National Comprehensive Cancer Network®

NCCN Clinical Practice Guidelines in Oncology (NCCN Guidelines®)

Soft Tissue Sarcoma

Version 3.2026 — March 12, 2026

NCCN recognizes the importance of clinical trials and encourages participation when applicable and available. Trials should be designed to maximize inclusiveness and broad representative enrollment.

NCCN Guidelines for Patients® available at www.nccn.org/patients

Version 3.2026, 03/12/26 © 2026 National Comprehensive Cancer Network® (NCCN®), All rights reserved. NCCN Guidelines® and this illustration may not be reproduced in any form without the express written permission of NCCN.

PLEASE NOTE that use of this NCCN Content is governed by the End-User License Agreement, and you MAY NOT distribute this Content or use it with any artificial intelligence model or tool.
Printed by Ling Lu on 6/26/2026 6:10:47 AM. Copyright © 2026 National Comprehensive Cancer Network, Inc. All Rights Reserved.

National Comprehensive Cancer Network®

NCCN Guidelines Version 3.2026
Soft Tissue Sarcoma

NCCN Guidelines Index
Table of Contents
Discussion

***Margaret von Mehren, MD/Chair †**
Fox Chase Cancer Center

***John M. Kane III, MD/Vice-Chair ¶**
Roswell Park Comprehensive Cancer Center

Samantha A. Armstrong, MD †
Indiana University Melvin and Bren Simon Comprehensive Cancer Center

Tessa Balach, MD ᴛ ¶
The UChicago Medicine Comprehensive Cancer Center

Andrew J. Bishop, MD §
The University of Texas MD Anderson Cancer Center

Darya Buehler, MD ≠
University of Wisconsin Carbone Cancer Center

Shauna R. Campbell, DO §
Case Comprehensive Cancer Center/ University Hospitals Seidman Cancer Center and Cleveland Clinic Taussig Cancer Institute

Janai Carr-Ascher, MD, PhD †
UC Davis Comprehensive Cancer Center

Edwin Choy, MD, PhD †
Mass General Cancer Center

Mary Connolly, MSW ¥
Patient advocate

Amanda Dann, MD ¶
UT Southwestern Simmons Comprehensive Cancer Center

Elizabeth J. Davis, MD Þ †
Vanderbilt-Ingram Cancer Center

NCCN
Zeenat Diwan, MS, PhD
Vaishnavi Sambandam, PhD
Mary Anne Bergman

Sarah Dry, MD ≠
UCLA Jonsson Comprehensive Cancer Center

Vanessa Eulo, MD †
O'Neal Comprehensive Cancer Center at UAB

Kristen N. Ganjoo, MD †
Stanford Cancer Institute

Ricardo J. Gonzalez, MD ¶
Moffitt Cancer Center

Pedro A. Hermida de Viveiros, MD ‡
Robert H. Lurie Comprehensive Cancer Center of Northwestern University

Ying J. Hitchcock, MD §
Huntsman Cancer Institute at the University of Utah

Edward Kim, MD §
Fred Hutchinson Cancer Center

Daniel S. Lefler, MD Þ †
Abramson Cancer Center at the University of Pennsylvania

David Liebner, MD Þ †
The Ohio State University Comprehensive Cancer Center - James Cancer Hospital and Solove Research Institute

Martin McCarter, MD ¶
University of Colorado Cancer Center

Sean V. McGarry, MD ¶ ᴛ
Fred & Pamela Buffett Cancer Center

Christian Meyer, MD, PhD †
Johns Hopkins Kimmel Cancer Center

Kambiz Motamedi, MD ф
UCLA Jonsson Comprehensive Cancer Center

Sujana Movva, MD †
Memorial Sloan Kettering Cancer Center

Alberto S. Pappo, MD €
St. Jude Children's Research Hospital/The University of Tennessee Health Science Center

Richard F. Riedel, MD †
Duke Cancer Institute

Steven Robinson, MBBS †
Mayo Clinic Comprehensive Cancer Center

Laura H. Rosenberger, MD, MS ¶
Duke Cancer Institute

Scott M. Schuetze, MD, PhD †
University of Michigan Rogel Cancer Center

Jason K. Sicklick, MD ¶
UC San Diego Moores Cancer Center

William W. Tseng, MD ¶
City of Hope National Medical Center

Mia C. Weiss, MD †
Siteman Cancer Center at Barnes-Jewish Hospital and Washington University School of Medicine

Melissa Zimel, MD ᴛ ¶
UCSF Helen Diller Family Comprehensive Cancer Center

NCCN Guidelines Panel Disclosures

ф Diagnostic/Interventional radiology	≠ Pathology
‡ Hematology/Hematologic oncology	¥ Patient advocacy
Þ Internal medicine	€ Pediatric oncology
† Medical oncology	§ Radiotherapy/Radiation oncology
ᴛ Orthopedics/Orthopedic oncology	¶ Surgery/Surgical oncology
	* Discussion writing committee member

Version 3.2026, 03/12/26 © 2026 National Comprehensive Cancer Network® (NCCN®), All rights reserved. NCCN Guidelines® and this illustration may not be reproduced in any form without the express written permission of NCCN.

PLEASE NOTE that use of this NCCN Content is governed by the End-User License Agreement, and you MAY NOT distribute this Content or use it with any artificial intelligence model or tool.
Printed by Ling Lu on 6/26/2026 6:10:47 AM. Copyright © 2026 National Comprehensive Cancer Network, Inc. All Rights Reserved.

National Comprehensive Cancer Network®

NCCN Guidelines Version 3.2026
Soft Tissue Sarcoma

NCCN Soft Tissue Sarcoma Panel Members
Summary of the Guidelines Updates
Soft Tissue Sarcoma
- Extremity/Body Wall, Head/Neck (EXTSARC-1)
- Retroperitoneal/Intra-Abdominal (RETSARC-1)
- Desmoid Tumors (Aggressive Fibromatosis) (DESM-1)
- Rhabdomyosarcoma (RMS-1)
- Atypical Lipomatous Tumor and Well-Differentiated Liposarcoma (ALT/WDLPS-1)
- Borderline Phyllodes Tumor of the Breast (PHYLLSARC-1)
- Malignant Phyllodes Tumor of the Breast (PHYLLSARC-2)

Principles of Imaging (SARC-A)
Principles of Pathologic Assessment of Sarcoma Specimens (SARC-B)
Principles of Ancillary Techniques Useful in the Diagnosis of Sarcomas (SARC-C)
Principles of Surgery (SARC-D)
Principles of Radiation Therapy (SARC-E)
Principles of Interventional Oncology (SARC-F)

Systemic Therapy Agents and Regimens with Activity in Soft Tissue Sarcoma Subtypes and Aggressive Soft Tissue Neoplasms (SARC-G)
Principles of Cancer Risk Assessment and Counseling (SARC-H)

Staging and WHO Classification (ST-1)
Abbreviations (ABBR-1)

Bone Sarcomas - NCCN Guidelines for Bone Cancer
Gastrointestinal Stromal Tumors - NCCN Guidelines for Gastrointestinal Stromal Tumors
Uterine Sarcomas - NCCN Guidelines for Uterine Neoplasms
Dermatofibrosarcoma Protuberans without Fibrosarcomatous Transformation - NCCN Guidelines for Dermatofibrosarcoma Protuberans

Find an NCCN Member Institution: https://www.nccn.org/home/member-institutions.

NCCN Categories of Evidence and Consensus: All recommendations are category 2A unless otherwise indicated.

See NCCN Categories of Evidence and Consensus.

NCCN Categories of Preference: All recommendations are considered appropriate.

See NCCN Categories of Preference.

The NCCN Guidelines® are a statement of evidence and consensus of the authors regarding their views of currently accepted approaches to treatment. Any clinician seeking to apply or consult the NCCN Guidelines is expected to use independent medical judgment in the context of individual clinical circumstances to determine any patient's care or treatment. The National Comprehensive Cancer Network® (NCCN®) makes no representations or warranties of any kind regarding their content, use or application and disclaims any responsibility for their application or use in any way. The NCCN Guidelines are copyrighted by National Comprehensive Cancer Network®. All rights reserved. The NCCN Guidelines and the illustrations herein may not be reproduced in any form without the express written permission of NCCN. ©2026.

PLEASE NOTE that use of this NCCN Content is governed by the End-User License Agreement, and you MAY NOT distribute this Content or use it with any artificial intelligence model or tool.
Printed by Ling Lu on 6/26/2026 6:10:47 AM. Copyright © 2026 National Comprehensive Cancer Network, Inc. All Rights Reserved.

National Comprehensive Cancer Network®

NCCN Guidelines Version 3.2026
Soft Tissue Sarcoma

NCCN Guidelines Index
Table of Contents
Discussion

Updates in Version 3.2026 of the NCCN Guidelines for Soft Tissue Sarcoma include:

SARC-G, 4 of 14
- Epithelioid Sarcoma: Tazemetostat removed.
  - Footnote, removed: Single-agent therapy for the treatment of metastatic or locally advanced epithelioid sarcoma not eligible for complete resection.
    - Reference, removed: Stacchiotti S, Schoffski P, Jones R, et al. Safety and efficacy of tazemetostat, a first-in-class EZH2 inhibitor, in patients with epithelioid sarcoma (NCT0261950). JClin Oncol 2019;37:11003.

Updates in Version 2.2026 of the NCCN Guidelines for Soft Tissue Sarcoma include:

SARC-G, 1 of 14

Subsequent Lines of Therapy for Advanced/Metastatic Disease

Other Recommended
- Modified: Ifosfamide/*Mesna*

Useful in Certain Circumstances
- Erratum: Revised regimen from pembrolizumab or ipilimumab + nivolumab to "pembrolizumab or *nivolumab ± ipilimumab*"

Updates in Version 1.2026 of the NCCN Guidelines for Soft Tissue Sarcoma include:

Global
- References for systemic therapy agents and regimens were updated throughout the guidelines.

EXTSARC-1

Work Up /Essential
- Bullet 6, new: Assess for Distress, with the following footnote: Refer to the NCCN Guidelines for Distress Thermometer and Problem List, which includes social determinants of health. See NCCN Guidelines for Distress.

Useful in Certain Circumstances
- Deleted footnote: Different subtypes have different propensities to spread to various locations.

Special considerations for unique histologies
- Added: *RETSARC-2* after Ewing Sarcoma.
- New algorithm: *Benign phyllodes,* linking to the NCCN Breast Cancer Guidelines.
- New algorithm: *Borderline/Malignant phyllodes,* linking to *PHYLLSARC-1 and PHYLLSARC-2.*

EXTSARC-2
- Page Title modified to include: *Multimodality Treatment is Critical, (*also for EXTSARC-4).
- Column 1: added "or" after Stage 1A.

Footnotes
- j, revised: See Principles of Surgery (SARC-D) including ~~Surgery can often result in physical disability. See~~ guidance for prehabilitation and rehabilitation (SARC-D 3 of 4). (Also for EXTSARC-3A).
- New footnote: In the rare situation where surgery is not an option, consider observation.

EXTSARC-3
- Column 3, Stage III, new footnote: In select histologies and locations there may be a role for neoadjuvant pembrolizumab (SARC-G), corresponding to neoadjuvant systemic therapy + RT.
  - Last row, footnote added: *Fungating necrotic bleeding and/or super infected tumors may not allow for pre-operative radiation and/or neoadjuvant chemotherapy and may be better served with surgery followed by adjuvant therapy.*
- Column 5, neoadjuvant systemic therapy, surgery to obtain oncologically appropriate margins: RT added *category 1* designation.
- Column 6, bullet 1, modified: H&P *imaging* every 3-6...
  - Sub-bullet 1, modified: ~~Chest~~ *Imaging for metastatic disease*.

Treatment
- New footnote: Owen D, Harmsen WS, Ahmed SK, et al. Highs and Lows of Spatially Fractionated Radiation Therapy: Dosimetry and Clinical Outcomes. Pract Radiat Oncol, 2025;15:e388-e395 corresponding to palliative options.
- New bullet: Resection of involved lymph nodes/regional nodal dissection for nodal involvement ± RT ± systemic therapy.

Continued

Version 3.2026, 03/12/26 © 2026 National Comprehensive Cancer Network® (NCCN®), All rights reserved. NCCN Guidelines® and this illustration may not be reproduced in any form without the express written permission of NCCN.

PLEASE NOTE that use of this NCCN Content is governed by the End-User License Agreement, and you MAY NOT distribute this Content or use it with any artificial intelligence model or tool.
Printed by Ling Lu on 6/26/2026 6:10:47 AM. Copyright © 2026 National Comprehensive Cancer Network, Inc. All Rights Reserved.

Updates in Version 1.2026 of the NCCN Guidelines for Soft Tissue Sarcoma include:

RETSARC-2
• Column 1, modified: ... Resectable *primary* disease.
Footnote
• n, modified: Consider systemic therapy if high risk for metastatic disease or if downstaging is needed to facilitate resection. Systemic therapy is not recommended for low-grade tumors *such as well-differentiated liposarcoma with no evidence of dedifferentiation.* (Also for RETSARC-6)
RETSARC-3
• R2, Column 2, modified: Adjuvant RT should not be administered routinely with the exception of highly selected patients and unless *progressive disease* ~~local recurrence~~ would cause undue morbidity.
DESM-2
Footnotes
• Deleted: For tumors that are symptomatic, or impairing or threatening in function, patients should be offered therapy with the decision based on the location of the tumor and potential morbidity of the therapeutic option. (Also for DESM-3).
• e, modified: Spontaneous regression has been reported in *up to* 20% of patients, supporting an initial period of observation in patients with newly diagnosed desmoid tumors (Gounder MM, et al. N Engl J Med *2023;388:898-912; Kasper B, et al. Future Oncol 2025;21:889-901).* ~~2018;379:2417-2428.~~ (Also for DESM-3).
DESM-4
• Column 4, R0: deleted: Adjuvant RT (category 3).
  ▸ R1, deleted: Adjuvant RT (category 2B).
  ▸ R2, modified: Ablation/*embolization*
    ◊ Deleted: procedures.
Footnote
• Deleted: Consider RT for lesions where recurrence would be technically challenging to resect and would lead to significant morbidity.
RMS-1
Treatment
• Column 3, modified: Recommend treating like high-grade *Soft Tissue Sarcoma* ~~undifferentiated pleomorphic sarcoma (UPS)~~ (see SARC-G for systemic therapy options).
PHYLLSARC-1
• Phyllodes tumor of the breast is an new section.
SARC-A
Principles of Imaging
Global:
• FDG-PET/CT has been modified to FDG-*PET* imaging (CT or MRI).
• Bullet 1, modified: ~~Plain radiographs~~ *For long-term survivors, chest x-rays and nonionizing imaging modalities may be considered to minimize radiation exposure* ~~or MRI may be substituted for long-term survivors on surveillance to minimize radiation exposure from CT imaging~~. *Consider FDG-PET/Fused 3-dimensional imaging* in staging, prognostication, grading, and determining response to chemotherapy with the following footnote: *FDG-PET/CT is more common but FDG-PET/MRI can be considered depending on availability and physician's opinion.*

Continued
UPDATES

PLEASE NOTE that use of this NCCN Content is governed by the End-User License Agreement, and you MAY NOT distribute this Content or use it with any artificial intelligence model or tool.
Printed by Ling Lu on 6/26/2026 6:10:47 AM. Copyright © 2026 National Comprehensive Cancer Network, Inc. All Rights Reserved.

Updates in Version 1.2026 of the NCCN Guidelines for Soft Tissue Sarcoma include:

SARC-A (continued)
Principles of Imaging
Table 1
- The table has been divided.
- Column 3, row, 2, modified: MRI (preferred for extremity/body wall, head and neck *and cardiac*) and/or CT (preferred for retroperitoneum).
- Column 4, all rows, deleted, As part of ... at the beginning of the sentence and Added "For".

SARC-A, 5 of 5
Evaluation and Workup
- New: ~~CT or MRI~~ Contrasted cross-sectional imaging with MRI (with and without contrast) is preferred over CT (with contrast, unless otherwise stated). (Also for Surveillance).
- ~~Biopsy should be performed for suspicious masses to confirm the diagnosis~~

~~May not be necessary if complete resection is planned~~ SARC-B
Principles of Pathologic Assessment of Sarcoma Specimens
- Sub-bullet 9, Sub, sub-bullet 5, new sentence: For patients who have received neoadjuvant therapy, information on treatment response and viable tumor.

SARC-C, 1 of 4
- Principles of Ancillary Techniques Useful in the Diagnosis of Sarcomas
- Footnote 2, sentence 2 deleted: For example, additional genetic aberrations can be found in alveolar RMS, including PAX3::NCOA1, PAX3::NCOA2, and PAX3::INO80D. NCOA2 gene rearrangements and MYOD mutation have been identified in spindle cell RMS. Receptor tyrosine kinase/RAS/PIK3CA aberrations are found in 93% of RMS cases. MIR143::NOTCH fusion has recently been identified in glomus tumor. Loss of TSC1 (9q34) or TSC2 (16p13.3) (mTOR pathway) or gene fusions of the TFE3 gene (microphthalmia-associated transcription factor family) have been identified in perivascular epithelioid cell tumor (PEComa).

SARC-C, 4 of 4
- Deleted, Leiomyosarcoma (LMS) under Tumor, Complete alterations under Aberration, Unknown under Gene(s) involved.

SARC-D, 1 of 4
- Principles of Surgery
  - Modified: *The* multidisciplinary *surgical* team *should include expertise in* ~~sarcoma with~~ *the management of sarcomas at specific anatomic sites as well as reconstruction*. ~~management including plastic, reconstructive, vascular and thoracic surgeons is recommended.~~
- Biopsy
  - Bullet 4, new: There is no clarity in the literature on when sentinel node staging in STS should be done. A multidisciplinary discussion should occur regarding its role in certain histologies with a possibility of occult lymph node metastasis (eg, clear cell, angiosarcoma, epithelioid, alveolar rhabdomyosarcoma) during treatment planning.
- Deleted: For certain histologies with a propensity for nodal metastatic disease, sentinel node biopsy can be considered, especially if the presence of occult nodal metastatic disease would change the multimodality treatment plan.

Continued
UPDATES

Version 3.2026, 03/12/26 © 2026 National Comprehensive Cancer Network® (NCCN®), All rights reserved. NCCN Guidelines® and this illustration may not be reproduced in any form without the express written permission of NCCN.

PLEASE NOTE that use of this NCCN Content is governed by the End-User License Agreement, and you MAY NOT distribute this Content or use it with any artificial intelligence model or tool.
Printed by Ling Lu on 6/26/2026 6:10:47 AM. Copyright © 2026 National Comprehensive Cancer Network, Inc. All Rights Reserved.

Updates in Version 1.2026 of the NCCN Guidelines for Soft Tissue Sarcoma include:

SARC-D, 2 of 4
- Failure to Obtain Oncologically Appropriate Margins: Added, *Extremity, Truncal, Head/Neck.*
- Failure to Obtain Oncologically Appropriate Margins: Added, *Retroperitoneal/Intra-abdominal.*

SARC-E, 1 of 6
- Principles of Radiation Therapy

Bullet 4, 2nd sentence: Added *(preferred)* to IMRT.

SARC-F 2 of 3

Principles of Interventional Oncology

Ablation
- Bullet 1,modified: Tumor ablation involves application of *FDA-approved* thermal or non-thermal *device therapies* to a tumor to achieve cell death. ~~Thermal ablation achieves tissue destruction by the induction of extreme hypothermia (cryoablation) or hyperthermia (radiofrequency ablation [RFA], microwave ablation, laser ablation, and high-intensity focused ultrasound [HIFU]). Non-thermal ablation such as irreversible electroporation (IRE) results in permanent cellular membrane injury~~.
- Bullet 2, new: Tumor ablation techniques include thermal and non-thermal approaches.
  - Sub-bullet 1, modified: Ablation modality should be based on tumor size, location, and adjacent critical structures to optimize treatment effect while limiting potential adverse events. *Choice of treatment modality may also take into account institutional experience and technique availability.*
  - Deleted: Ablation can include the target lesion in addition to a margin of radiologically normal tissue to ensure complete local treatment.
  - Deleted: Adjunct passive and active thermoprotective techniques, such as hydrodissection, could be used to protect adjacent critical structures during percutaneous ablation.
- Bullet 5, sub-bullet 2 modified: Cryoablation is the ~~recommended~~ *most commonly utilized* ablation modality.

SARC-G, 1 of 14

Neoadjuvant/Adjuvant Therapy

Preferred
- Bullet 3, new: Neoadjuvant Pembrolizumab with RT followed by adjuvant Pembrolizumab for UPS related sarcomas (limb girdle/extremity UPS/ myxofibrosarcoma [MFS]/dedifferentiated liposarcoma [ddLPS]/pleomorphic liposarcoma)

First-Line Therapy Advanced/Metastatic

Useful in Certain Circumstances
- Deleted: MAID (Mesna/Doxorubicin/Ifosfamide/Dacarbazine) (Also for DFSP, Other recommended, on SARC-G 4 of 14 and solitary Fibrous Tumor, Other recommended on SARC-G 6 of 14).

SARC-G, 3 of 14

Alveolar Soft Part Sarcoma (ASPS)

Preferred
- Bullet 4, new: Axitinib + Pembrolizumab

SARC-G 8 of 14

Footnotes
- New: Pembrolizumab and berahyaluronidase alfa-pmph subcutaneous injection may be substituted for IV pembrolizumab. Pembrolizumab and berahyaluronidase alfa-pmph has different dosing and administration instructions compared to IV pembrolizumab.

Continued

Version 3.2026, 03/12/26 © 2026 National Comprehensive Cancer Network® (NCCN®), All rights reserved. NCCN Guidelines® and this illustration may not be reproduced in any form without the express written permission of NCCN.

PLEASE NOTE that use of this NCCN Content is governed by the End-User License Agreement, and you MAY NOT distribute this Content or use it with any artificial intelligence model or tool.
Printed by Ling Lu on 6/26/2026 6:10:47 AM. Copyright © 2026 National Comprehensive Cancer Network, Inc. All Rights Reserved.

NCCN Guidelines Version 3.2026
Extremity/Body Wall, Head/Neck

NCCN Guidelines Index
Table of Contents
Discussion

WORKUP

ESSENTIAL:

- Prior to the initiation of therapy, all patients should be evaluated and treated by a multidisciplinary team with expertise and experience in sarcoma[a]
- History and physical (H&P)
- Adequate imaging of primary tumor[b] is indicated for all lesions with a reasonable chance of being malignant
- Carefully planned core needle [preferred] or incisional biopsy should be performed after adequate imaging (SARC-D)
  - Place biopsy along future resection axis with minimal dissection and careful attention to hemostasis
  - Biopsy should establish grade and histologic subtype[c]
  - As appropriate, use ancillary diagnostic methodologies[d]
- Obtain imaging of potential sites of metastatic disease
- Assess for distress[e]

USEFUL UNDER CERTAIN CIRCUMSTANCES:

- Additional imaging as indicated; see Principles of Imaging (SARC-A)
- The following conditions are linked to increased incidence of sarcoma and other cancers:
  - For patients with neurofibromatosis,[f] see NCCN Guidelines for Central Nervous System Cancers (PSCT-3)
    - ◊ For pheochromocytoma, see NCCN Guidelines for Neuroendocrine and Adrenal Tumors
  - For Li-Fraumeni syndrome, see NCCN Guidelines for Genetic/Familial High-Risk Assessment: Breast, Ovarian, Pancreatic, and Prostate
  - For hereditary non-polyposis colorectal cancer (HNPCC or Lynch syndrome), see NCCN Guidelines for Genetic/Familial High-Risk Assessment: Colorectal, Endometrial, and Gastric
  - For patients with personal/family history suggestive of other cancer predisposition syndromes, consider further genetics assessment

Special considerations for unique histologies[g]

- Ewing sarcoma → RETSARC-2; NCCN Guidelines for Bone Cancer
- Desmoid tumors (Aggressive fibromatosis) → DESM-1
- Rhabdomyosarcoma (RMS) → RMS-1
- Dermatofibrosarcoma protuberans (DFSP) without fibrosarcomatous transformation[h] → NCCN Guidelines for Dermatofibrosarcoma Protuberans (DFSP)
- Atypical lipomatous tumor (ALT)/Well-differentiated liposarcoma (WDLPS) → ALT/WDLPS-1
- Benign phyllodes → NCCN Guidelines for Breast Cancer
- Borderline/Malignant phyllodes → PHYLLSARC-1; PHYLLSARC-2

Other soft tissue sarcomas of the extremity/body wall, head/neck[h]

- Stage I → Primary (EXTSARC-2)
- Stage II, III, and select Stage IV (any T, N1, M0) resectable disease with acceptable functional outcomes → Primary (EXTSARC-3)
- Stage II, III, and select Stage IV (any T, N1, M0) resectable disease but with unacceptable functional outcomes or unresectable primary disease → Primary (EXTSARC-4)
- Stage IV synchronous disease → Primary (EXTSARC-5)
- Recurrent disease → Primary (EXTSARC-6)

Note: All recommendations are category 2A unless otherwise indicated.

Footnotes on EXTSARC-1A

Version 3.2026, 03/12/26 © 2026 National Comprehensive Cancer Network® (NCCN®), All rights reserved. NCCN Guidelines® and this illustration may not be reproduced in any form without the express written permission of NCCN.

PLEASE NOTE that use of this NCCN Content is governed by the End-User License Agreement, and you MAY NOT distribute this Content or use it with any artificial intelligence model or tool.
Printed by Ling Lu on 6/26/2026 6:10:47 AM. Copyright © 2026 National Comprehensive Cancer Network, Inc. All Rights Reserved.

FOOTNOTES

[a] These guidelines are intended to treat the adult population. For adolescent and young adult patients, see NCCN Guidelines for Adolescent and Young Adult (AYA) Oncology.

[b] Imaging studies should include cross-sectional imaging (MRI with and without contrast and/or CT with contrast) to provide details about the size of tumor and contiguity to nearby visceral structures and neurovascular landmarks. Other imaging studies such as angiogram and plain x-ray may be warranted in selected circumstances. See Principles of Imaging (SARC-A).

[c] Principles of Pathologic Assessment of Sarcoma Specimens (SARC-B).

[d] Principles of Ancillary Techniques Useful in the Diagnosis of Sarcomas (SARC-C).

[e] Refer to the NCCN Guidelines for Distress Thermometer and Problem List, which includes social determinants of health. See NCCN Guidelines for Distress Management (DIS-A).

[f] Patients with neurofibromatosis are at risk for multiple sarcomas at various locations and their assessment and follow-up should be different (Reilly KM, et al. J Natl Cancer Inst 2017;109:djx124). Consider FDG-PET imaging (CT or MRI) for initial workup to differentiate between neurofibroma(s) and malignant peripheral nerve sheath tumor (MPNST).

[g] Diagnoses that will impact the overall treatment plan. See SARC-G for special considerations for unique histologies.

[h] Patients with DFSP with fibrosarcomatous changes and/or malignant transformations should be treated according to the algorithms for other soft tissue sarcomas of the extremity/body wall and head/neck (EXTSARC-1 and SARC-G, 4 of 14).

Note: All recommendations are category 2A unless otherwise indicated.

PLEASE NOTE that use of this NCCN Content is governed by the End-User License Agreement, and you MAY NOT distribute this Content or use it with any artificial intelligence model or tool.
Printed by Ling Lu on 6/26/2026 6:10:47 AM. Copyright © 2026 National Comprehensive Cancer Network, Inc. All Rights Reserved.

PRIMARY TREATMENT
(MULTIMODALITY TREATMENT IS CRITICAL)

FOLLOW-UP

Stage IA[i] or Stage IB[i] (low grade) → • **Surgery[j,k] to obtain oncologically appropriate margins[l]** → • **H&P every 3–6 mo for 3 y, then annually**
• **Obtain baseline imaging[m] see SARC-A**
• **Periodic imaging of primary site[m] based upon risk of locoregional recurrence[n,o]**
• **Consider chest imaging[m]** → **If recurrence, see Recurrent Disease (EXTSARC-6)**

[i] See American Joint Committee on Cancer (AJCC) Staging, 8th Edition (ST-5 and ST-6).
[j] See Principles of Surgery (SARC-D) including guidance for prehabilitation and rehabilitation (SARC-D 3 of 4).
[k] See SARC-D for either a previous unplanned excision or a failure to obtain oncologically appropriate margins with planned sarcoma surgery.
[l] In the rare situation where surgery is not an option, consider observation.
[m] Principles of Imaging (SARC-A).
[n] In situations where the area is easily followed by physical examination, imaging may not be required.
[o] After 10 years, the likelihood of developing a recurrence is small and follow-up should be individualized.

Note: All recommendations are category 2A unless otherwise indicated.

Version 3.2026, 03/12/26 © 2026 National Comprehensive Cancer Network® (NCCN®), All rights reserved. NCCN Guidelines® and this illustration may not be reproduced in any form without the express written permission of NCCN.

PLEASE NOTE that use of this NCCN Content is governed by the End-User License Agreement, and you MAY NOT distribute this Content or use it with any artificial intelligence model or tool.
Printed by Ling Lu on 6/26/2026 6:10:47 AM. Copyright © 2026 National Comprehensive Cancer Network, Inc. All Rights Reserved.

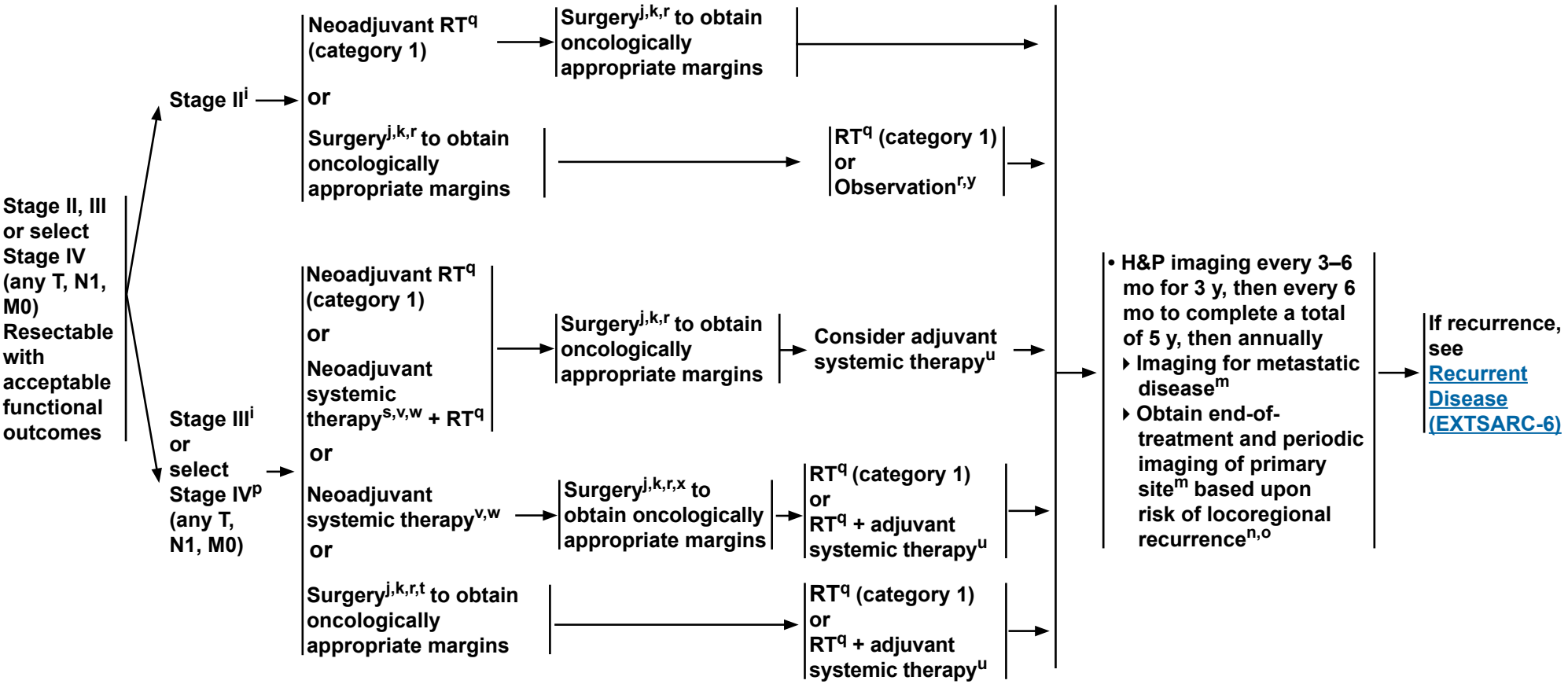

Footnotes on EXTSARC-3A

Note: All recommendations are category 2A unless otherwise indicated.

Version 3.2026, 03/12/26 © 2026 National Comprehensive Cancer Network® (NCCN®), All rights reserved. NCCN Guidelines® and this illustration may not be reproduced in any form without the express written permission of NCCN.

PLEASE NOTE that use of this NCCN Content is governed by the End-User License Agreement, and you MAY NOT distribute this Content or use it with any artificial intelligence model or tool.
Printed by Ling Lu on 6/26/2026 6:10:47 AM. Copyright © 2026 National Comprehensive Cancer Network, Inc. All Rights Reserved.

FOOTNOTES

[i] See AJCC Staging, 8th Edition (ST-5 and ST-6).
[j] See Principles of Surgery (SARC-D) including guidance for prehabilitation and rehabilitation (SARC-D 3 of 4).
[k] See SARC-D for either a previous unplanned excision or a failure to obtain oncologically appropriate margins with planned sarcoma surgery.
[m] Principles of Imaging (SARC-A).
[n] In situations where the area is easily followed by physical examination, imaging may not be required.
[o] After 10 years, the likelihood of developing a recurrence is small and follow-up should be individualized.
[p] For management of a primary sarcoma with synchronous regional nodal metastatic disease, see above for treatment of the primary tumor and refer to EXTSARC-6 for management of nodal disease.
[q] See Principles of Radiation Therapy (SARC-E) for discussion of adjuvant versus neoadjuvant therapy.
[r] In selected cases when margin status is uncertain, consultation with a radiation oncologist is recommended.
[s] In select histologies and locations, there may be a role for neoadjuvant pembrolizumab (SARC-G).
[t] Fungating necrotic bleeding and/or super infected tumors may not allow for preoperative radiation and/or neoadjuvant chemotherapy and may be better served with surgery followed by adjuvant therapy.
[u] Systemic Therapy Agents and Regimens with Activity in Soft Tissue Sarcoma Subtypes and Aggressive Soft Tissue Neoplasms (SARC-G).
[v] Neoadjuvant-based chemotherapy may be beneficial in patients with chemotherapy-sensitive tumor types with high-probability of mortality from sarcoma based on available nomograms, FNCLCC Grade 3 sarcomas, or in cases where downsizing tumor would facilitate complete resection. (Spunt SL, et al. Lancet Oncol 2020;21:145-161; Pasquali S, et al. Eur J Cancer 2019;109:51-60; Pasquali S, et al. Cancer 2022;128:85-93; Italiano A, et al. Ann Oncol 2010;21:2436-2441).
[w] FDG-PET imaging (CT or MRI) may be useful in determining response to systemic therapy (Schuetze SM, et al. Cancer 2005;103:339-348).
[x] A prospective study demonstrated low rates of local recurrence with surgery alone in carefully selected patients with high-grade tumors <5 cm (Pisters PW, et al. Ann Surg 2007;246:675-681). Consider omission of RT for tumors <5 cm resected with wide margins if a repeat resection would be feasible with low morbidity in the case of a recurrence.
[y] Observation alone can be considered following a resection with a widely negative margin if the risk for local recurrence is very low.

Note: All recommendations are category 2A unless otherwise indicated.

PLEASE NOTE that use of this NCCN Content is governed by the End-User License Agreement, and you MAY NOT distribute this Content or use it with any artificial intelligence model or tool.
Printed by Ling Lu on 6/26/2026 6:10:47 AM. Copyright © 2026 National Comprehensive Cancer Network, Inc. All Rights Reserved.

NCCN Guidelines Version 3.2026
Extremity/Body Wall, Head/Neck

NCCN Guidelines Index
Table of Contents
Discussion

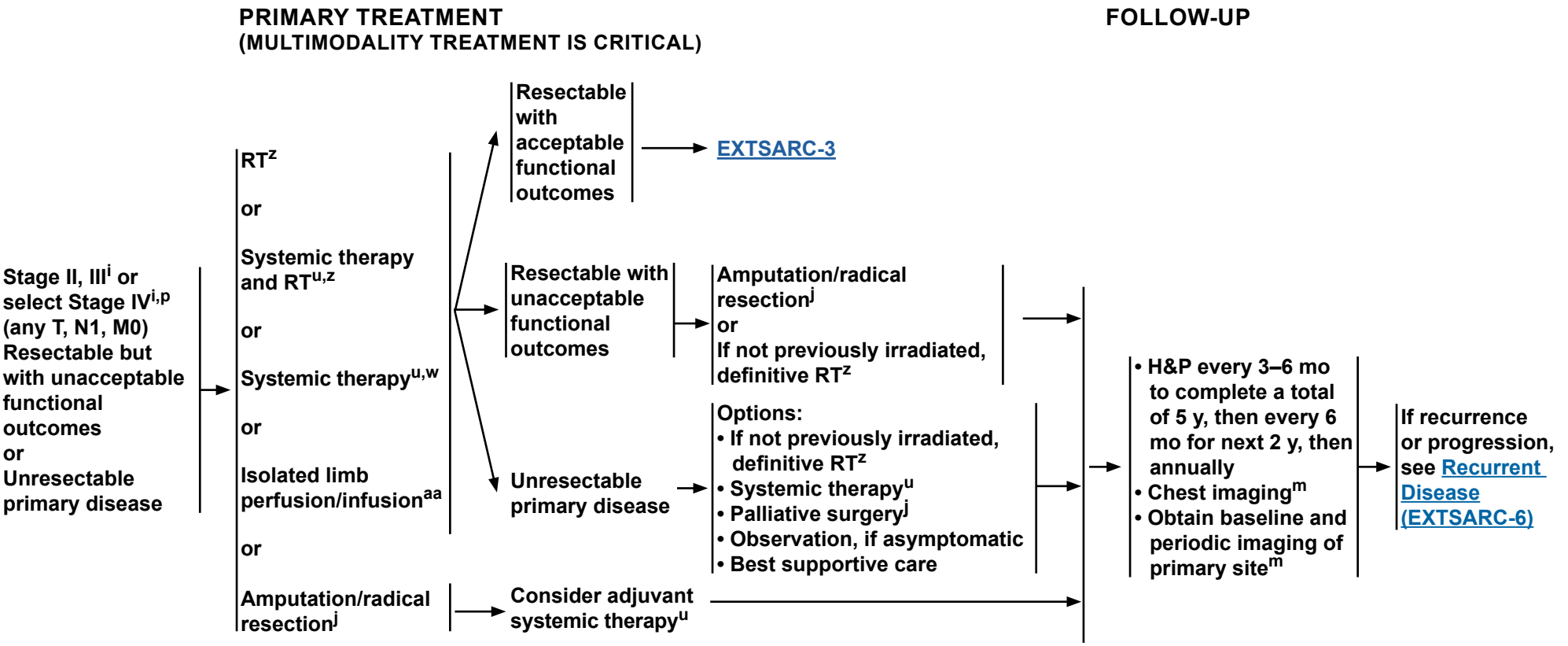

[i] See AJCC Staging, 8th Edition (ST-5 and ST-6).
[j] See Principles of Surgery (SARC-D) including guidance for prehabilitation and rehabilitation (SARC-D 3 of 4).
[m] Principles of Imaging (SARC-A).
[p] For management of a primary sarcoma with synchronous regional nodal metastatic disease, refer to EXTSARC-6 for management of nodal disease.
[u] Systemic Therapy Agents and Regimens with Activity in Soft Tissue Sarcoma Subtypes and Aggressive Soft Tissue Neoplasms (SARC-G).
[w] FDG-PET imaging (CT or MRI) may be useful in determining response to systemic therapy (Schuetze SM, et al. Cancer 2005;103:339-348).
[z] Principles of Radiation Therapy (SARC-E).
[aa] Should only be done at institutions with experience in isolated limb perfusion/infusion.

Note: All recommendations are category 2A unless otherwise indicated.

Version 3.2026, 03/12/26 © 2026 National Comprehensive Cancer Network® (NCCN®), All rights reserved. NCCN Guidelines® and this illustration may not be reproduced in any form without the express written permission of NCCN.

PLEASE NOTE that use of this NCCN Content is governed by the End-User License Agreement, and you MAY NOT distribute this Content or use it with any artificial intelligence model or tool.
Printed by Ling Lu on 6/26/2026 6:10:47 AM. Copyright © 2026 National Comprehensive Cancer Network, Inc. All Rights Reserved.

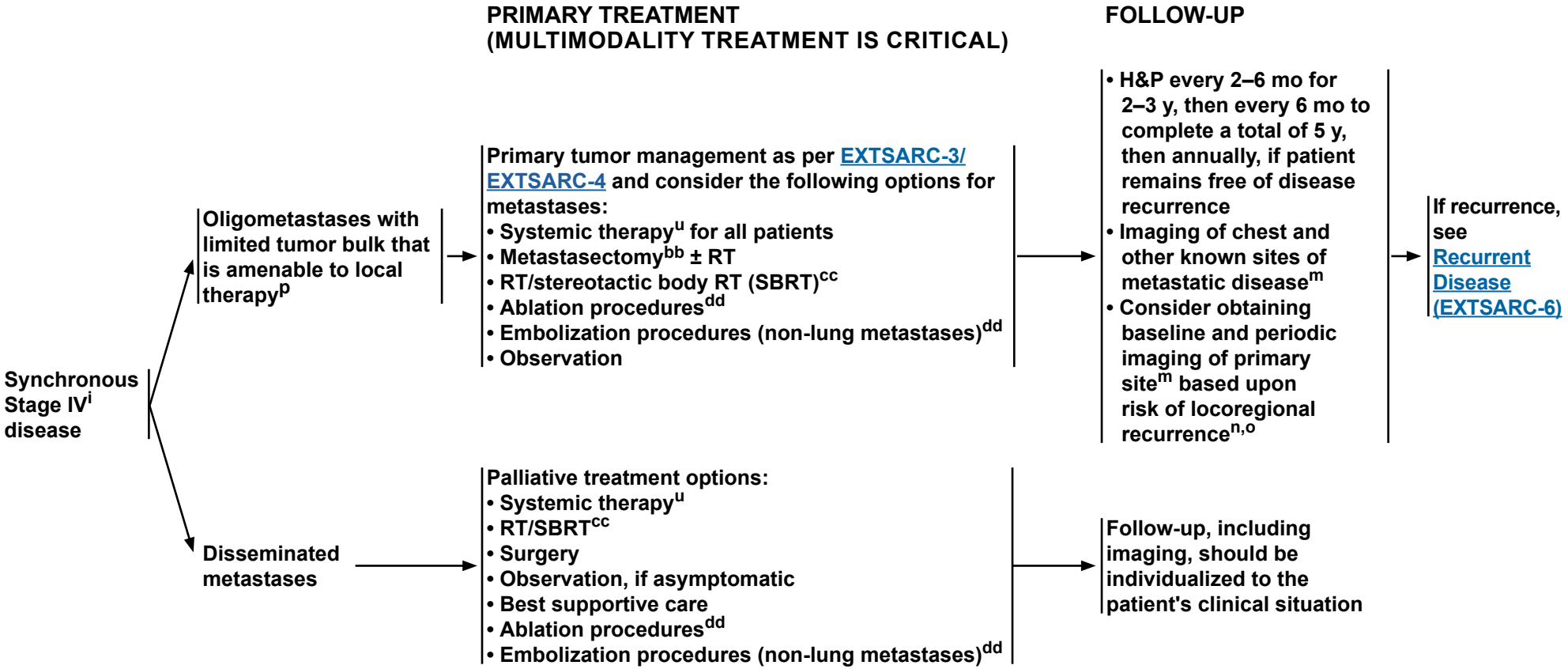

[i] See AJCC Staging, 8th Edition (ST-5 and ST-6).
[m] Principles of Imaging (SARC-A).
[n] In situations where the area is easily followed by physical examination, imaging may not be required.
[o] After 10 years, the likelihood of developing a recurrence is small and follow-up should be individualized.
[p] For management of a primary sarcoma with synchronous regional nodal metastatic disease, see EXTSARC-3 or EXTSARC-4 for treatment of the primary tumor and refer to EXTSARC-6 for management of nodal disease.
[u] Systemic Therapy Agents and Regimens with Activity in Soft Tissue Sarcoma Subtypes and Aggressive Soft Tissue Neoplasms (SARC-G).
[bb] Metastasectomy is the historical standard for patients with oligometastatic disease (primarily lung); the ultimate choice of local control modality may depend on factors such as performance status, patient preference, lesion location/ accessibility, ability to preserve normal tissue function, and anticipated morbidity of a treatment modality.
[cc] In retrospective studies, various SBRT dosing regimens have been reported to be effective for treatment of sarcoma metastases. Dose and fractionation should be determined by an experienced radiation oncologist based on normal tissue constraints (Dhakal S, et al. Int J Radiat Oncol Biol Phys 2012;82:940-945; Navarria P, et al. Eur J Cancer 2015;51:668-674; Baumann BC, et al. J Surg Oncol 2020;122:877-883).
[dd] Principles of Interventional Oncology (SARC-F).

Note: All recommendations are category 2A unless otherwise indicated.

Version 3.2026, 03/12/26 © 2026 National Comprehensive Cancer Network® (NCCN®), All rights reserved. NCCN Guidelines® and this illustration may not be reproduced in any form without the express written permission of NCCN.

PLEASE NOTE that use of this NCCN Content is governed by the End-User License Agreement, and you MAY NOT distribute this Content or use it with any artificial intelligence model or tool.
Printed by Ling Lu on 6/26/2026 6:10:47 AM. Copyright © 2026 National Comprehensive Cancer Network, Inc. All Rights Reserved.

RECURRENT DISEASE

TREATMENT

Local recurrence → **Follow Workup, then appropriate Primary Treatment[ff,gg,hh] pathway (EXTSARC-2, EXTSARC-3, EXTSARC-4)**

Metastatic disease

- **Single organ and limited tumor bulk that are amenable to local therapy** →
  - **Options:**
  - **Metastasectomy[bb] ± neoadjuvant or adjuvant systemic therapy[u] ± RT**
  - **SBRT[cc] ± systemic therapy[u]**
  - **Ablation procedures[dd]**
  - **Embolization procedures (non-lung metastases)[dd]**
  - **Observation**
- **Disseminated metastases** →
  - **Palliative options[ee]:**
  - **Systemic therapy[u]**
  - **RT/SBRT[cc]**
  - **Surgery**
  - **Observation, if asymptomatic**
  - **Best supportive care**
  - **Ablation procedures[dd]**
  - **Embolization procedures (non-lung metastases)[dd]**
- **Isolated regional disease or nodes** →
  - **Resection of involved lymph nodes/regional nodal dissection for nodal involvement ± RT ± systemic therapy[u]**

[u] Systemic Therapy Agents and Regimens with Activity in Soft Tissue Sarcoma Subtypes and Aggressive Soft Tissue Neoplasms (SARC-G).

[bb] Metastasectomy is the historical standard for patients with oligometastatic disease (primarily lung); the ultimate choice of local control modality may depend on factors such as performance status, patient preference, lesion location/accessibility, ability to preserve normal tissue function, and anticipated morbidity of a treatment modality.

[cc] In retrospective studies, various SBRT dosing regimens have been reported to be effective for treatment of sarcoma metastases. Dose and fractionation should be determined by an experienced radiation oncologist based on normal tissue constraints (Dhakal S, et al. Int J Radiat Oncol Biol Phys 2012;82:940-945; Navarria P, et al. Eur J Cancer 2015;51:668-674; Baumann BC, et al. J Surg Oncol 2020;122:877-883).

[dd] Principles of Interventional Oncology (SARC-F).

[ee] Owen D, et al. Pract Radiat Oncol 2025;15:e388-e395.

[ff] If local recurrence can be excised, a decision will need to be made on a case-by-case basis whether re-irradiation is possible. Some case series suggest benefit with re-irradiation (Catton C, et al. Radiother Oncol 1996;41:209-214) while others do not (Torres MA, et al. Int J Radiat Oncol Biol Phys 2007;67:1124-1129), likely reflecting differences in selection of patients for treatment with surgery and radiotherapy or surgery alone. Brachytherapy, intensity-modulated RT (IMRT), and/or proton beam therapy may be utilized to reduce the morbidity of re-irradiation.

[gg] Based upon tumor biology and disease-free interval, consideration for additional chemotherapy and/or radiation (if previously administered) would be made on a case-by-case basis by a sarcoma multidisciplinary team.

[hh] Consider preoperative or postoperative radiation if radiation was not administered previously.

Note: All recommendations are category 2A unless otherwise indicated.

PLEASE NOTE that use of this NCCN Content is governed by the End-User License Agreement, and you MAY NOT distribute this Content or use it with any artificial intelligence model or tool.
Printed by Ling Lu on 6/26/2026 6:10:47 AM. Copyright © 2026 National Comprehensive Cancer Network, Inc. All Rights Reserved.

WORKUP

- **Prior to the initiation of therapy, all patients should be evaluated and treated by a multidisciplinary team with expertise and experience in sarcoma.[a]**
- **H&P**
- **Imaging[b]**
- **Image-guided core needle biopsy[c,d]**
- **For patients with neurofibromatosis,[e] see NCCN Guidelines for Central Nervous System Cancers (PSCT-3)**
  - **For pheochromocytoma, see NCCN Guidelines for Neuroendocrine and Adrenal Tumors**
- **For Li-Fraumeni syndrome, see NCCN Guidelines for Genetic/Familial High-Risk Assessment: Breast, Ovarian, Pancreatic, and Prostate**
- **For HNPCC or Lynch syndrome, see NCCN Guidelines for Genetic/Familial High-Risk Assessment: Colorectal, Endometrial, and Gastric**
- **For patients with personal/family history suggestive of other cancer predisposition syndromes, consider further genetics assessment.**

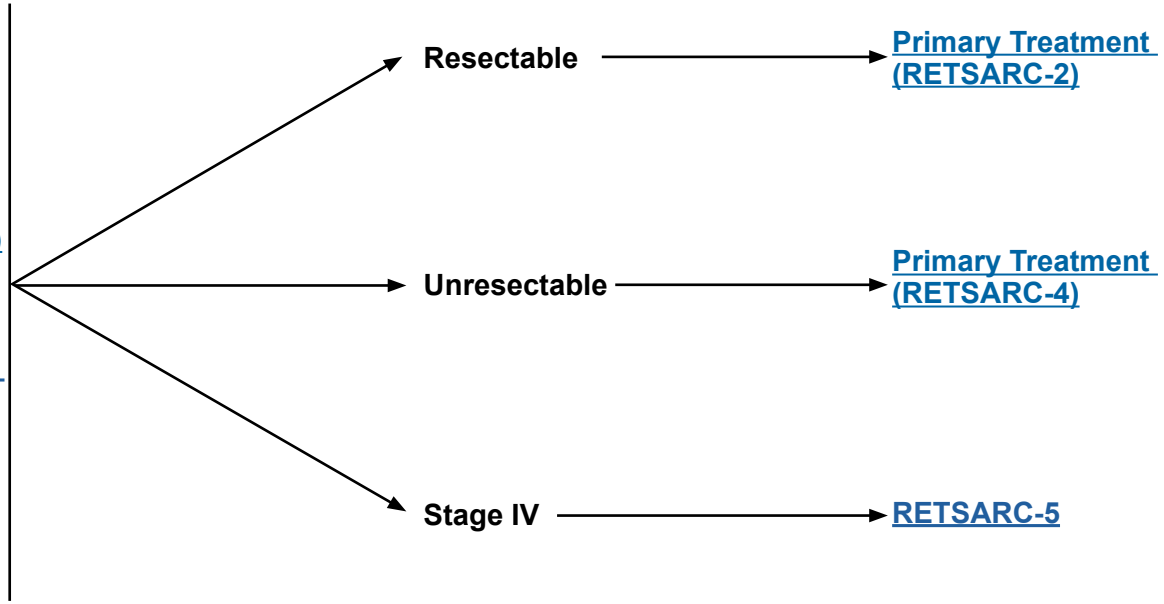

[a] These guidelines are intended to treat the adult population. For adolescent and young adult patients, see NCCN Guidelines for Adolescent and Young Adult (AYA) Oncology.
[b] Principles of Imaging (SARC-A).
[c] Biopsy for retroperitoneal/intra-abdominal sarcomas should try to avoid the free intra-abdominal space. See Principles of Surgery (SARC-D).
[d] Biopsy may occasionally be omitted if the imaging is judged to be pathognomonic (eg, WDLPS) by an expert radiologist within an expert multidisciplinary tumor board, and no preoperative treatment is planned.
[e] Patients with neurofibromatosis are at risk for multiple sarcomas at various locations and their assessment and follow-up should be different (Reilly KM, et al. J Natl Cancer Inst 2017;109:djx124). Consider FDG-PET imaging (CT or MRI) for initial workup to differentiate between neurofibroma(s) and MPNST.

Note: All recommendations are category 2A unless otherwise indicated.

Version 3.2026, 03/12/26 © 2026 National Comprehensive Cancer Network® (NCCN®), All rights reserved. NCCN Guidelines® and this illustration may not be reproduced in any form without the express written permission of NCCN.

PLEASE NOTE that use of this NCCN Content is governed by the End-User License Agreement, and you MAY NOT distribute this Content or use it with any artificial intelligence model or tool.
Printed by Ling Lu on 6/26/2026 6:10:47 AM. Copyright © 2026 National Comprehensive Cancer Network, Inc. All Rights Reserved.

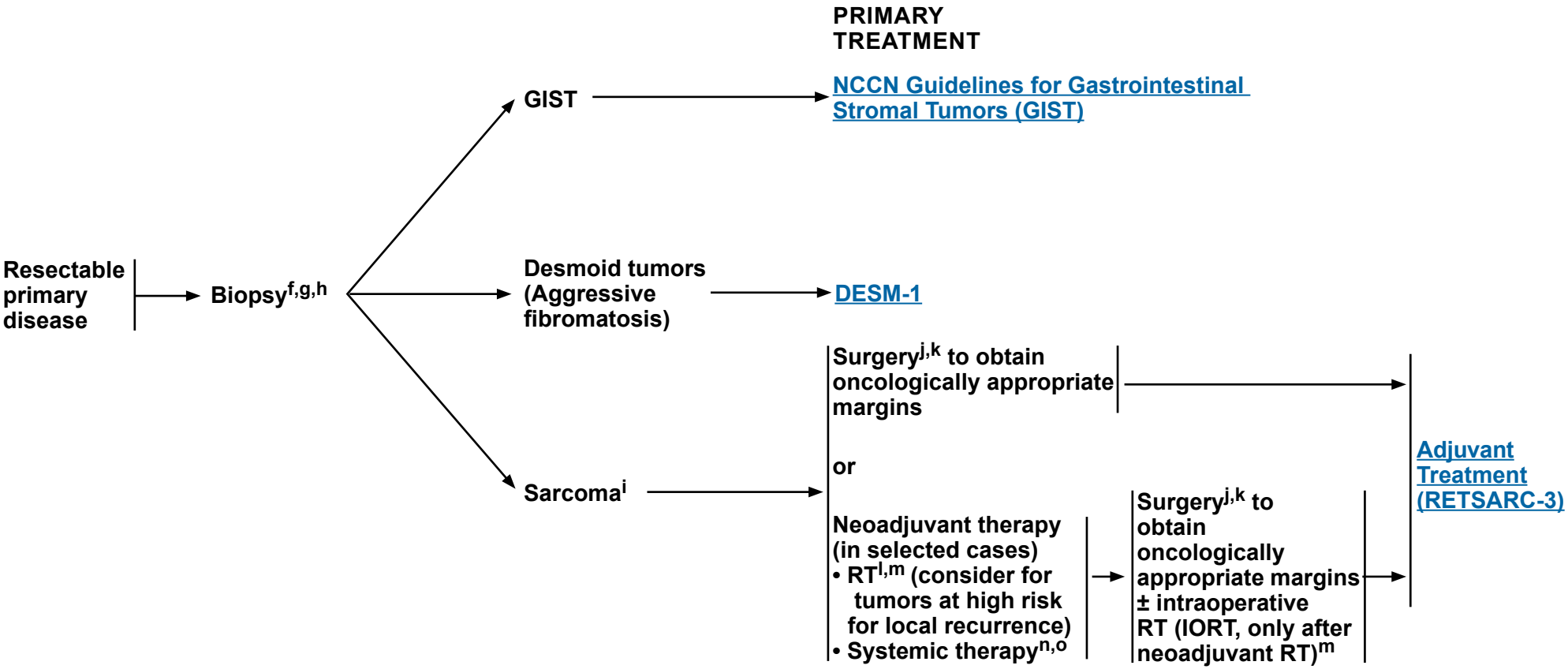

[f] Principles of Pathologic Assessment of Sarcoma Specimens (SARC-B).
[g] If considering neoadjuvant therapy, biopsy required, including endoscopic ultrasound-guided biopsy for suspected GIST lesions.
[h] Biopsy may not be required if diagnostic imaging is consistent with WDLPS.
[i] For other soft tissue sarcomas such as Ewing sarcoma, see NCCN Guidelines for Bone Cancer; for RMS, see RMS-1.
[j] Principles of Surgery (SARC-D).
[k] Surgery can often result in physical disability. See (SARC-D 3 of 4) for guidance on prehabilitation and rehabilitation.
[l] If neoadjuvant RT is anticipated, IMRT and other advanced image-guided radiation techniques are recommended; see Principles of Radiation Therapy (SARC-E).
[m] Principles of Radiation Therapy (SARC-E).
[n] Consider systemic therapy if high risk for metastatic disease or if downstaging is needed to facilitate resection. Systemic therapy is not recommended for low-grade tumors such as well differentiated liposarcoma with no evidence of dedifferentiation.
[o] Systemic Therapy Agents and Regimens with Activity in Soft Tissue Sarcoma Subtypes and Aggressive Soft Tissue Neoplasms (SARC-G).

Note: All recommendations are category 2A unless otherwise indicated.

Version 3.2026, 03/12/26 © 2026 National Comprehensive Cancer Network® (NCCN®), All rights reserved. NCCN Guidelines® and this illustration may not be reproduced in any form without the express written permission of NCCN.

PLEASE NOTE that use of this NCCN Content is governed by the End-User License Agreement, and you MAY NOT distribute this Content or use it with any artificial intelligence model or tool.
Printed by Ling Lu on 6/26/2026 6:10:47 AM. Copyright © 2026 National Comprehensive Cancer Network, Inc. All Rights Reserved.

NCCN Guidelines Version 3.2026
Retroperitoneal/Intra-Abdominal

NCCN Guidelines Index
Table of Contents
Discussion

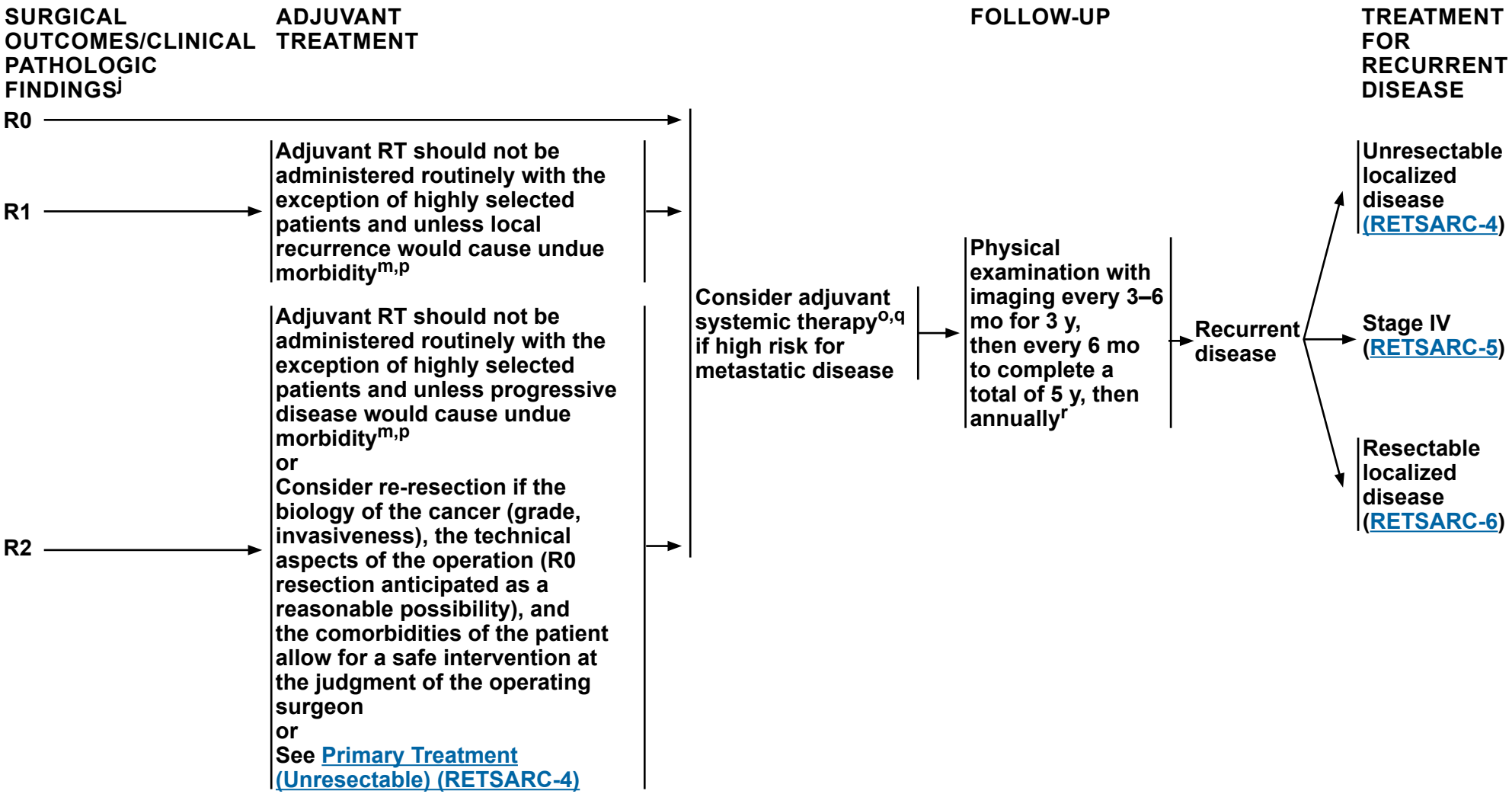

[j] Principles of Surgery (SARC-D).
[m] Principles of Radiation Therapy (SARC-E).
[o] Systemic Therapy Agents and Regimens with Activity in Soft Tissue Sarcoma Subtypes and Aggressive Soft Tissue Neoplasms (SARC-G).
[p] For example, critical anatomic surface where recurrence would cause morbidity.
[q] Systemic therapy is not recommended for low-grade tumors.
[r] Routine chest imaging for metastatic disease is not necessary (for well-differentiated liposarcoma) as per Principles of Imaging (SARC-A).

Note: All recommendations are category 2A unless otherwise indicated.

Version 3.2026, 03/12/26 © 2026 National Comprehensive Cancer Network® (NCCN®), All rights reserved. NCCN Guidelines® and this illustration may not be reproduced in any form without the express written permission of NCCN.

PLEASE NOTE that use of this NCCN Content is governed by the End-User License Agreement, and you MAY NOT distribute this Content or use it with any artificial intelligence model or tool.
Printed by Ling Lu on 6/26/2026 6:10:47 AM. Copyright © 2026 National Comprehensive Cancer Network, Inc. All Rights Reserved.

TREATMENT

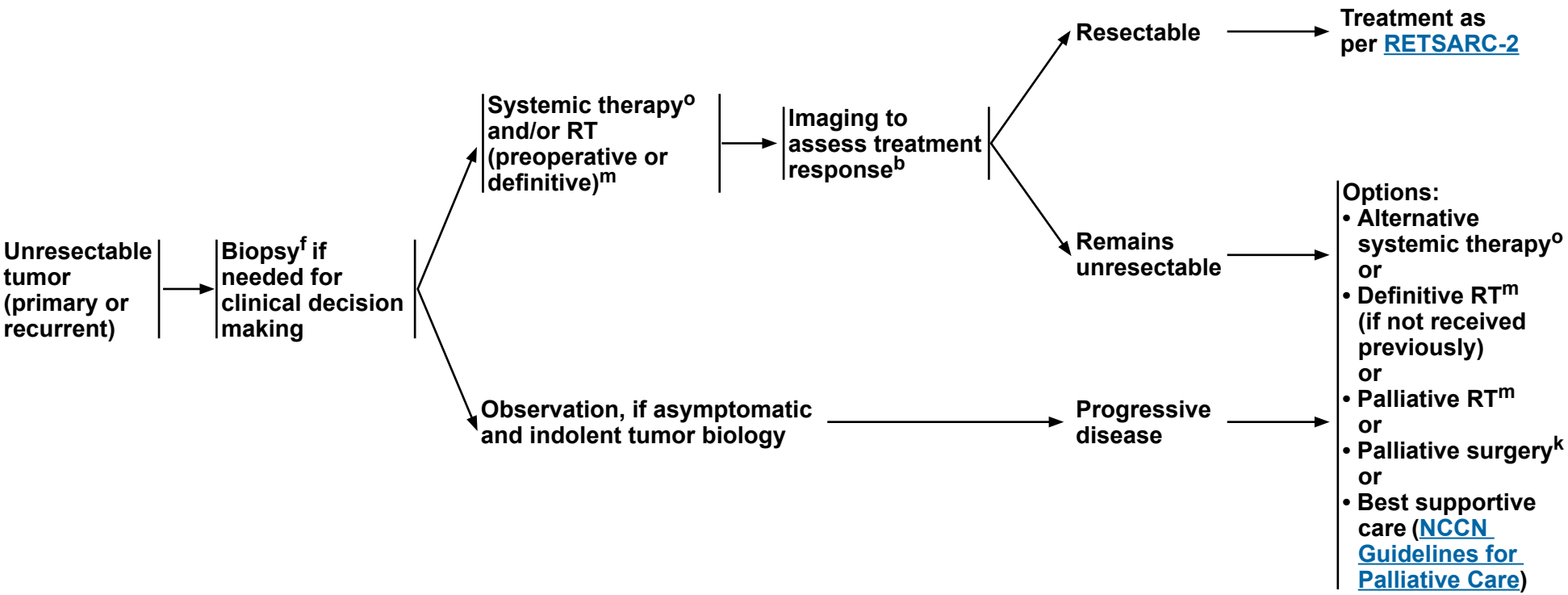

[b] Principles of Imaging (SARC-A).
[f] Principles of Pathologic Assessment of Sarcoma Specimens (SARC-B).
[k] Surgery can often result in physical disability. See (SARC-D 3 of 4) for guidance on prehabilitation and rehabilitation.
[m] Principles of Radiation Therapy (SARC-E).
[o] Systemic Therapy Agents and Regimens with Activity in Soft Tissue Sarcoma Subtypes and Aggressive Soft Tissue Neoplasms (SARC-G).

Note: All recommendations are category 2A unless otherwise indicated.

Version 3.2026, 03/12/26 © 2026 National Comprehensive Cancer Network® (NCCN®), All rights reserved. NCCN Guidelines® and this illustration may not be reproduced in any form without the express written permission of NCCN.

PLEASE NOTE that use of this NCCN Content is governed by the End-User License Agreement, and you MAY NOT distribute this Content or use it with any artificial intelligence model or tool.
Printed by Ling Lu on 6/26/2026 6:10:47 AM. Copyright © 2026 National Comprehensive Cancer Network, Inc. All Rights Reserved.

TREATMENT

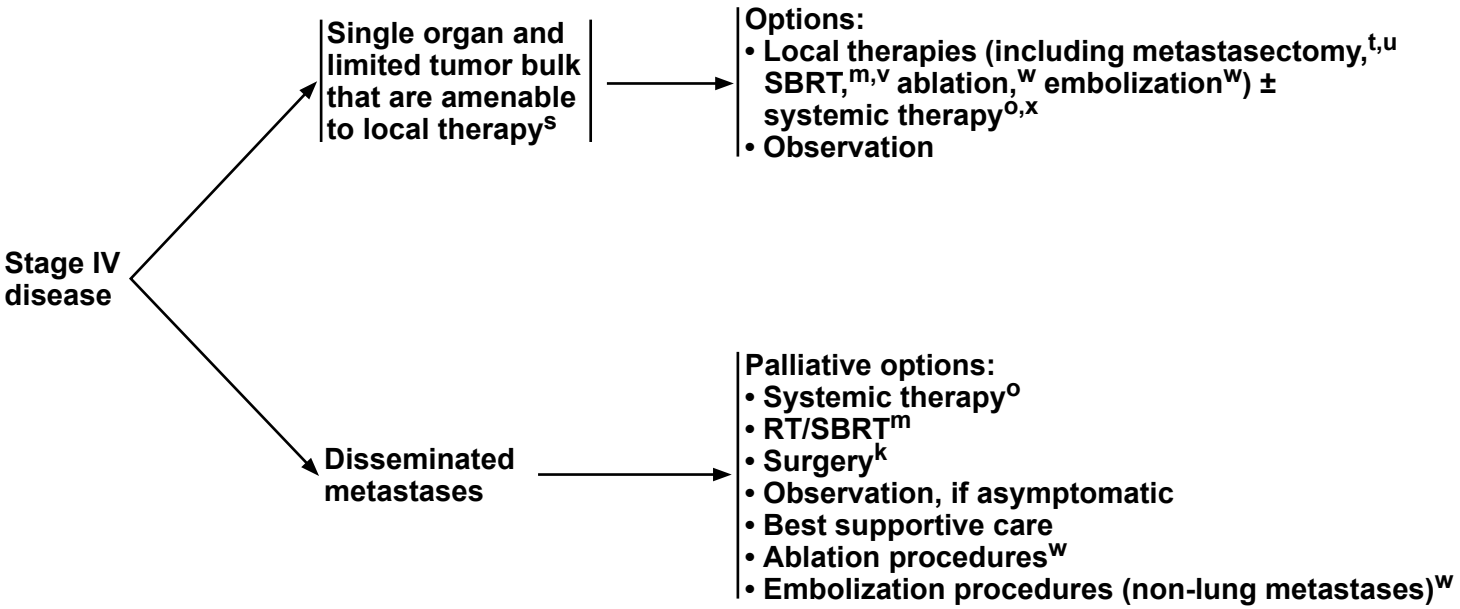

[k] Surgery can often result in physical disability. See (SARC-D 3 of 4) for guidance on prehabilitation and rehabilitation.
[m] Principles of Radiation Therapy (SARC-E).
[o] Systemic Therapy Agents and Regimens with Activity in Soft Tissue Sarcoma Subtypes and Aggressive Soft Tissue Neoplasms (SARC-G).
[s] Patients with lymph node involvement (including isolated regional nodal metastatic disease) should undergo regional lymph node dissection ± RT.
[t] Resection of resectable metastatic disease should be considered if primary tumor can be controlled. All patients should be evaluated and treated by a multidisciplinary team with expertise and experience in sarcoma.
[u] Metastasectomy is the historical standard for patients with oligometastatic disease (primarily lung); the ultimate choice of local control modality may depend on factors such as performance status, patient preference, lesion location/accessibility, ability to preserve normal tissue function, and anticipated morbidity of a treatment modality.
[v] In retrospective studies, various SBRT dosing regimens have been reported to be effective for treatment of sarcoma metastases. Dose and fractionation should be determined by an experienced radiation oncologist based on normal tissue constraints (Dhakal S, et al. Int J Radiat Oncol Biol Phys 2012;82:940-945; Navarria P, et al. Eur J Cancer 2015;51:668-674; Baumann BC, et al. J Surg Oncol 2020;122:877-883).
[w] Principles of Interventional Oncology (SARC-F).
[x] Consider neoadjuvant systemic therapy for unfavorable tumor biology (eg, short disease-free intervals, prior metastases) prior to considering local therapy.

Note: All recommendations are category 2A unless otherwise indicated.

Version 3.2026, 03/12/26 © 2026 National Comprehensive Cancer Network® (NCCN®), All rights reserved. NCCN Guidelines® and this illustration may not be reproduced in any form without the express written permission of NCCN.

PLEASE NOTE that use of this NCCN Content is governed by the End-User License Agreement, and you MAY NOT distribute this Content or use it with any artificial intelligence model or tool.
Printed by Ling Lu on 6/26/2026 6:10:47 AM. Copyright © 2026 National Comprehensive Cancer Network, Inc. All Rights Reserved.

INITIAL THERAPY

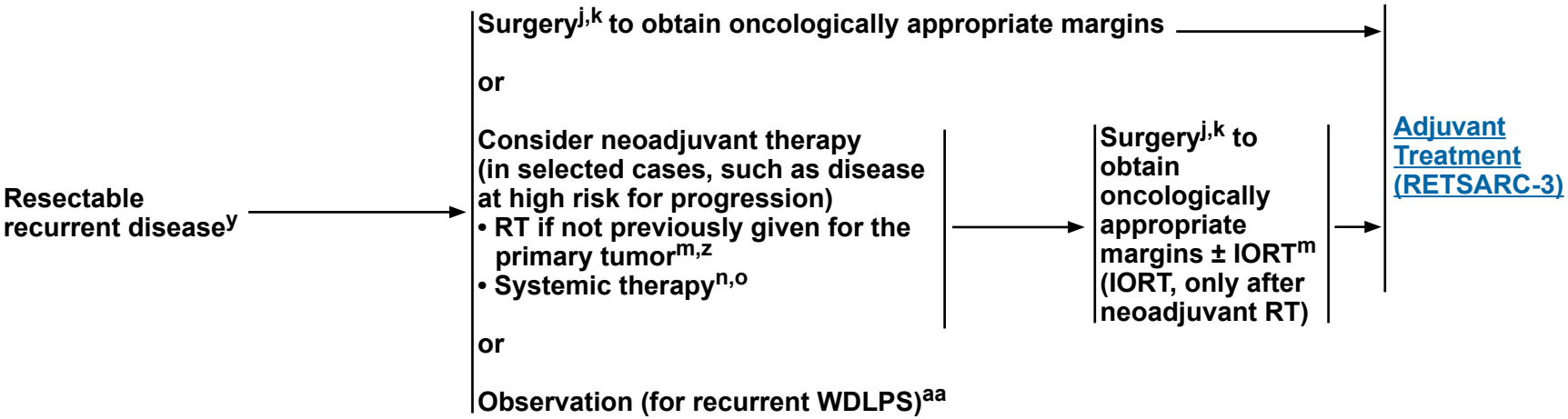

[j] Principles of Surgery (SARC-D).
[k] Surgery can often result in physical disability. See (SARC-D 3 of 4) for guidance on prehabilitation and rehabilitation.
[m] Principles of Radiation Therapy (SARC-E).
[n] Consider systemic therapy if high risk for metastatic disease or if downstaging is needed to facilitate resection. Systemic therapy is not recommended for low-grade tumors such as well-differentiated liposarcoma with no evidence of dedifferentiation.
[o] Systemic Therapy Agents and Regimens with Activity in Soft Tissue Sarcoma Subtypes and Aggressive Soft Tissue Neoplasms (SARC-G).
[y] Consider biopsy if recurrent disease diagnosis is not clinically definitive.
[z] If neoadjuvant RT is anticipated, IMRT would be preferred to optimize sparing of nearby critical structures.
[aa] For guidance on when to resect recurrent WDLPS, see: Ikoma N, et al. Ann Surg Oncol 2018;25:2193-2200; Tseng W, et al. Trans-Atlantic RPS Working Group. Ann Surg Oncol 2022;29:7335-7348.

Note: All recommendations are category 2A unless otherwise indicated.

Version 3.2026, 03/12/26 © 2026 National Comprehensive Cancer Network® (NCCN®), All rights reserved. NCCN Guidelines® and this illustration may not be reproduced in any form without the express written permission of NCCN.

PLEASE NOTE that use of this NCCN Content is governed by the End-User License Agreement, and you MAY NOT distribute this Content or use it with any artificial intelligence model or tool.
Printed by Ling Lu on 6/26/2026 6:10:47 AM. Copyright © 2026 National Comprehensive Cancer Network, Inc. All Rights Reserved.

NCCN Guidelines Version 3.2026
Desmoid Tumors (Aggressive Fibromatosis)

NCCN Guidelines Index
Table of Contents
Discussion

WORKUP

- **Prior to the initiation of the treatment plan, all patients should be evaluated and treated by a multidisciplinary team with expertise and experience in desmoid tumors**
- **H&P**
- **Consider evaluation for Gardner syndrome[a]/familial adenomatous polyposis (FAP) (NCCN Guidelines for Colorectal Cancer Screening)**
- **Appropriate imaging of primary site as clinically indicated[b]**

→ **Biopsy[c]**

→ **Anatomic location where progression would not be morbid** → **DESM-2**

→ **Anatomic location where progression would be morbid** → **DESM-3**

[a] Gardner syndrome is an autosomal dominant disorder characterized by a triad of colonic polyposis, osteoma, and soft tissue tumors (Traill Z, et al. AJR Am J Roentgenol 1995;165:1460-1461).
[b] Principles of Imaging (SARC-A).
[c] Principles of Pathologic Assessment of Sarcoma Specimens (SARC-B).

Note: All recommendations are category 2A unless otherwise indicated.

Version 3.2026, 03/12/26 © 2026 National Comprehensive Cancer Network® (NCCN®), All rights reserved. NCCN Guidelines® and this illustration may not be reproduced in any form without the express written permission of NCCN.

PLEASE NOTE that use of this NCCN Content is governed by the End-User License Agreement, and you MAY NOT distribute this Content or use it with any artificial intelligence model or tool.
Printed by Ling Lu on 6/26/2026 6:10:47 AM. Copyright © 2026 National Comprehensive Cancer Network, Inc. All Rights Reserved.

NCCN Guidelines Version 3.2026
Desmoid Tumors (Aggressive Fibromatosis)

NCCN Guidelines Index
Table of Contents
Discussion

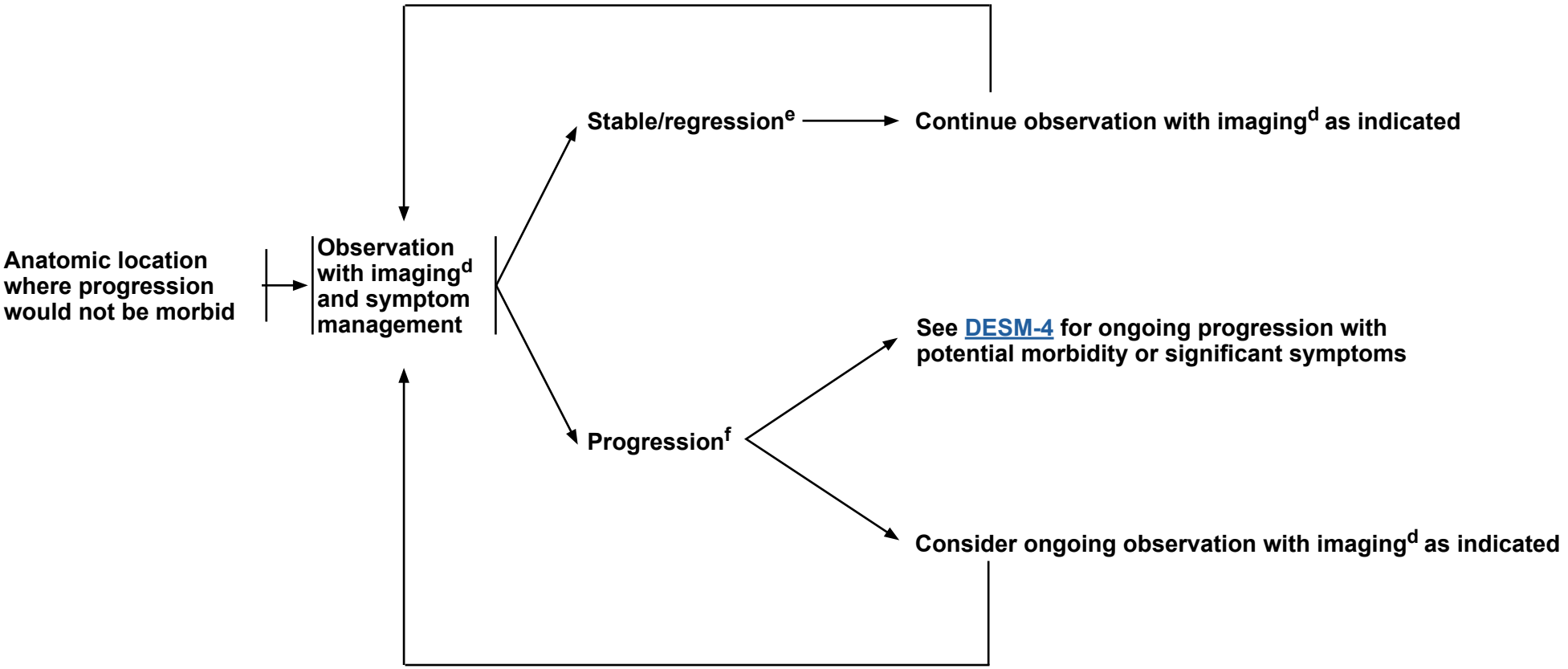

[d] Optimal frequency for imaging depends on the anatomic location of tumor, risk of progression, and symptoms of disease progression. Initial imaging every 3 months is recommended. More frequent imaging may be indicated in symptomatic patients. See Principles of Imaging (SARC-A).

[e] Spontaneous regression has been reported in up to 20% of patients, supporting an initial period of observation in patients with newly diagnosed desmoid tumors (Gounder MM, et al. N Engl J Med 2023;388:898-912; Kasper B, et al. Future Oncol 2025;21:889-901).

[f] A course of ongoing observation is an appropriate option even for patients with disease progression, if the patient is minimally symptomatic and the anatomical location of the tumor is not critical.

Note: All recommendations are category 2A unless otherwise indicated.

Version 3.2026, 03/12/26 © 2026 National Comprehensive Cancer Network® (NCCN®), All rights reserved. NCCN Guidelines® and this illustration may not be reproduced in any form without the express written permission of NCCN.

PLEASE NOTE that use of this NCCN Content is governed by the End-User License Agreement, and you MAY NOT distribute this Content or use it with any artificial intelligence model or tool.
Printed by Ling Lu on 6/26/2026 6:10:47 AM. Copyright © 2026 National Comprehensive Cancer Network, Inc. All Rights Reserved.

NCCN Guidelines Version 3.2026
Desmoid Tumors (Aggressive Fibromatosis)

NCCN Guidelines Index
Table of Contents
Discussion

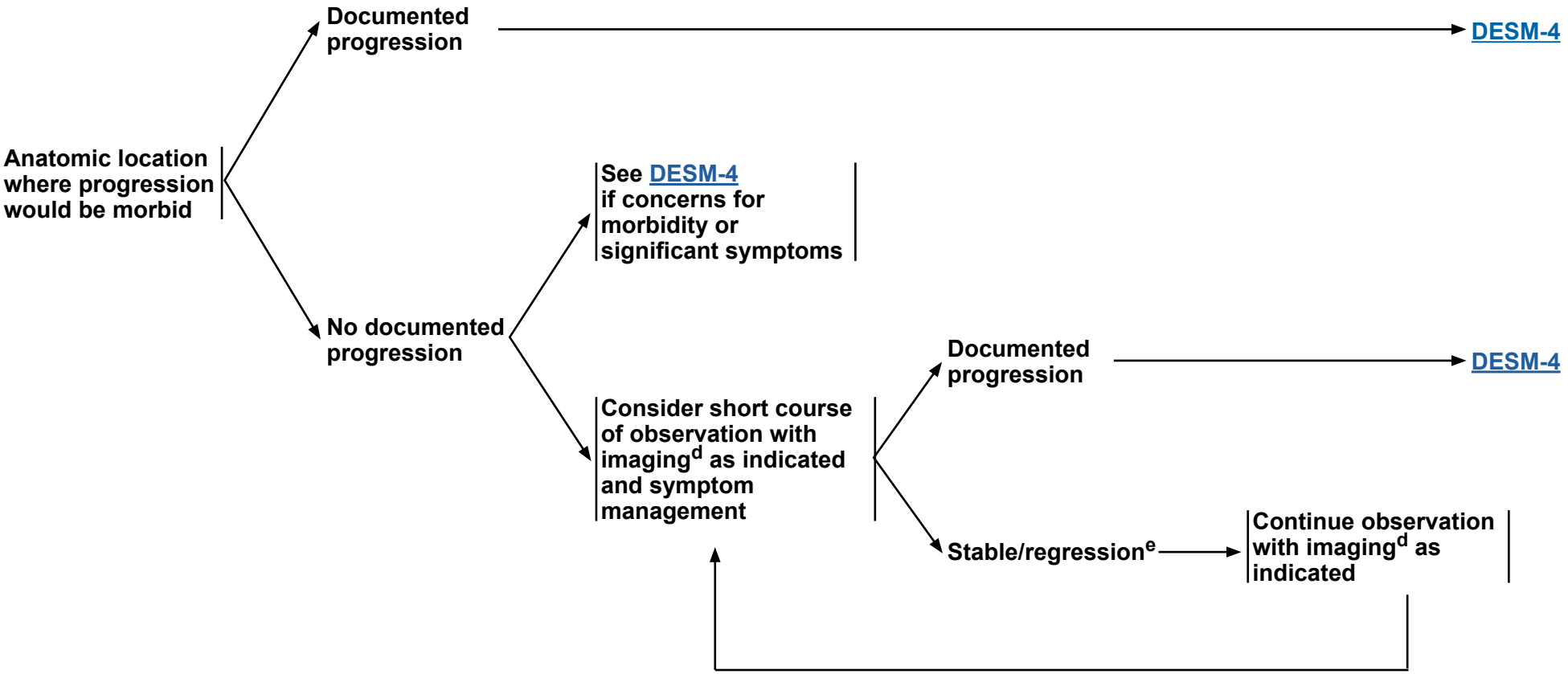

[d] Optimal frequency for imaging depends on the anatomic location of tumor, risk of progression, and symptoms of disease progression. Initial imaging every 3 months is recommended. More frequent imaging may be indicated in symptomatic patients. See Principles of Imaging (SARC-A).

[e] Spontaneous regression has been reported in up to 20% of patients, supporting an initial period of observation in patients with newly diagnosed desmoid tumors (Gounder MM, et al. N Engl J Med 2023;388:898-912; Kasper B, et al. Future Oncol 2025;21:889-901).

Note: All recommendations are category 2A unless otherwise indicated.

Version 3.2026, 03/12/26 © 2026 National Comprehensive Cancer Network® (NCCN®), All rights reserved. NCCN Guidelines® and this illustration may not be reproduced in any form without the express written permission of NCCN.

PLEASE NOTE that use of this NCCN Content is governed by the End-User License Agreement, and you MAY NOT distribute this Content or use it with any artificial intelligence model or tool.
Printed by Ling Lu on 6/26/2026 6:10:47 AM. Copyright © 2026 National Comprehensive Cancer Network, Inc. All Rights Reserved.

TREATMENT BASED ON ANATOMIC LOCATION

FOLLOW-UP

Active therapy for progressive, morbid, or symptomatic disease

- **Intra-abdominal/ Retroperitoneal** →
  - **Options**
  - **• Systemic therapy[g]**
  - **• Surgery[h,i] (less preferred)**
- **All other sites (abdominal wall, pelvis, trunk/ extremity, head/neck/ intrathoracic)** →
  - **Options**
  - **• Systemic therapy[g]**
  - **• Ablation/embolization[j]**
  - **• Definitive RT[k]**
  - **• Surgery[h,i,l] (less preferred)** →
    - **R0** →
    - **R1** →
    - **Observation**
    - **R2** →
    - **Definitive RT[k]**
    - **or**
    - **Systemic therapy[g]**
    - **or**
    - **Ablation/embolization[j]**
    - **or**
    - **Observation**
    - **or**
    - **Radical surgery to be considered if other modalities fail**

→ **• Imaging every 3–6 mo for 3 y, then every 6 mo to complete a total of 5 y, then annually[m]**

[g] Systemic Therapy Agents and Regimes with Activity in Soft Tissue Sarcoma Subtypes and Aggressive Soft Tissue Neoplasms (SARC-G).
[h] In general, surgery is not considered a first-line treatment option, except in certain situations if agreed upon by a multidisciplinary tumor board.
[i] Surgery can often result in physical disability. See (SARC-D 3 of 4) for guidance on prehabilitation and rehabilitation.
[j] Principles of Interventional Oncology (SARC-F).
[k] Principles of Radiation Therapy (SARC-E).
[l] Consider ± RT for head/neck/intrathoracic lesions where recurrence would be technically challenging to resect and would lead to significant morbidity.
[m] Principles of Imaging (SARC-A).

Note: All recommendations are category 2A unless otherwise indicated.

Version 3.2026, 03/12/26 © 2026 National Comprehensive Cancer Network® (NCCN®), All rights reserved. NCCN Guidelines® and this illustration may not be reproduced in any form without the express written permission of NCCN.

PLEASE NOTE that use of this NCCN Content is governed by the End-User License Agreement, and you MAY NOT distribute this Content or use it with any artificial intelligence model or tool.
Printed by Ling Lu on 6/26/2026 6:10:47 AM. Copyright © 2026 National Comprehensive Cancer Network, Inc. All Rights Reserved.

National Comprehensive Cancer Network®

NCCN Guidelines Version 3.2026
Rhabdomyosarcoma[a]

NCCN Guidelines Index
Table of Contents
Discussion

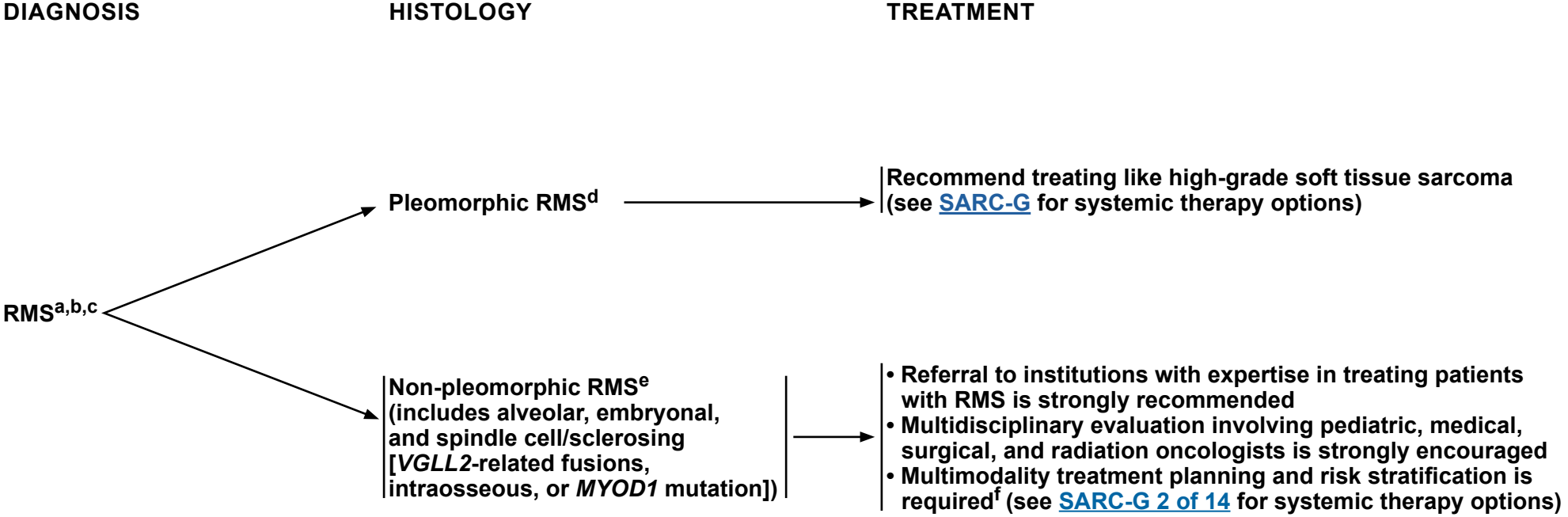

[a] RMS that is identified within another histology should be treated as the original histology. This pathway refers to patients diagnosed with pure RMS after full slide review.
[b] FDG-PET imaging (CT or MRI) scan may be useful for initial staging because of the possibility of nodal metastases and the appearance of unusual sites of initial metastatic disease in adult patients. See Principles of Imaging (SARC-A).
[c] Referral to centers with expertise in the management of pediatric cancers is recommended.
[d] Not to be confused with anaplastic variant in children.
[e] Up to 13% of RMS in younger patients may have anaplastic features and should not be confused with the high-grade tumors seen in adults designated as pleomorphic RMS.
[f] Systemic therapy options for RMS may be different than those used with other soft tissue sarcoma histologies. See Systemic Therapy Agents and Regimens with Activity in Soft Tissue Sarcoma Subtypes and Aggressive Soft Tissue Neoplasms (SARC-G).

Note: All recommendations are category 2A unless otherwise indicated.

Version 3.2026, 03/12/26 © 2026 National Comprehensive Cancer Network® (NCCN®), All rights reserved. NCCN Guidelines® and this illustration may not be reproduced in any form without the express written permission of NCCN.

PLEASE NOTE that use of this NCCN Content is governed by the End-User License Agreement, and you MAY NOT distribute this Content or use it with any artificial intelligence model or tool.
Printed by Ling Lu on 6/26/2026 6:10:47 AM. Copyright © 2026 National Comprehensive Cancer Network, Inc. All Rights Reserved.

NCCN Guidelines Version 3.2026
Atypical Lipomatous Tumor and Well-differentiated Liposarcoma

NCCN Guidelines Index
Table of Contents
Discussion

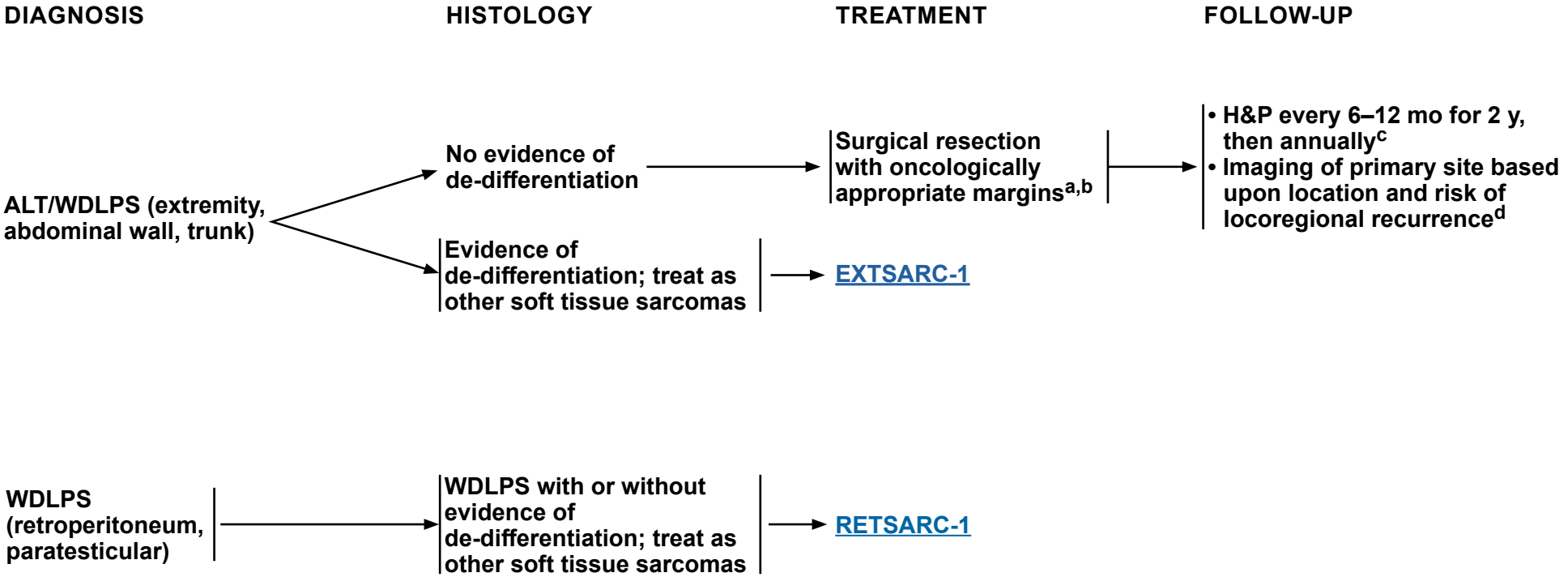

[a] ALT of the extremity, trunk, and abdominal wall is generally more indolent and an attempted marginal resection technique should be tailored to minimize surgical morbidity. En bloc resection with negative margins is generally sufficient to obtain long-term local control.
[b] For patients with ALT/WDLPS, observation is recommended for focally positive margins if, in the event of recurrence, re-resection would not result in undue morbidity. RT is reserved for selected patients with recurrent or deeply infiltrative primary lesions with a risk of local recurrence, depending on the tumor location and patient's age.
[c] Surveillance physical exams and imaging intervals should be adjusted to account for the potential for local recurrence.
[d] Routine chest imaging for metastatic disease is not necessary. See Principles of Imaging (SARC-A).

Note: All recommendations are category 2A unless otherwise indicated.

Version 3.2026, 03/12/26 © 2026 National Comprehensive Cancer Network® (NCCN®), All rights reserved. NCCN Guidelines® and this illustration may not be reproduced in any form without the express written permission of NCCN.

PLEASE NOTE that use of this NCCN Content is governed by the End-User License Agreement, and you MAY NOT distribute this Content or use it with any artificial intelligence model or tool.
Printed by Ling Lu on 6/26/2026 6:10:47 AM. Copyright © 2026 National Comprehensive Cancer Network, Inc. All Rights Reserved.

National Comprehensive Cancer Network®

NCCN Guidelines Version 3.2026
Borderline Phyllodes Tumor of the Breast

NCCN Guidelines Index
Table of Contents
Discussion

WORKUP

- Prior to the initiation of the treatment plan, all patients should be evaluated and treated by a multidisciplinary team with expertise and experience in phyllodes tumor
- H&P
  - Additional age- and risk-appropriate breast screening
- Consider breast MRI with and without contrast
  - Consider additional imaging (eg, CT) of the primary tumor as necessary for surgical planning. See Principles of Imaging (SARC-A)
- Core needle biopsy may not be sufficient to classify the tumor
- Genetic counseling and testing is recommended for breast[a] and sarcoma genes plus other inherited cancer genes consistent with family phenotype

TREATMENT

Surgery to obtain oncologically appropriate margins,[b] initial intent for 1 cm margin

- Negative margins → Consider adjuvant RT[d]
- Positive margins → Re-excision to obtain negative margins[c] → Consider adjuvant RT[d]

FOLLOW-UP

- H&P every 6 mo for 2 y, then annually through 5 y
  - Routine age- and risk-appropriate breast screening
- Breast/Chest wall MRI with and without contrast every 6 mo for 2 y, then annually through 5 y. See Principles of Imaging (SARC-A)
  - Consider additional imaging (eg, US, CT, as clinically appropriate) of the primary tumor site to monitor for local recurrence

If local recurrence or metastatic disease, see PHYLLSARC-5

[a] For risk criteria, see NCCN Guidelines for Genetic/Familial High-Risk Assessment: Breast, Ovarian, Pancreatic, and Prostate.
[b] For borderline or malignant phyllodes tumors, wide excision means excision with the intention of obtaining surgical margins ≥1 cm. Narrow surgical margins are associated with increased local recurrence risk, but are not an absolute indication for mastectomy when partial mastectomy fails to achieve a margin width ≥1 cm. Mastectomy may be needed to obtain these margins (considerations may include tumor and breast size).
[c] Radiation therapy is not a substitute for negative margins and additional surgery should be pursued for positive margins.
[d] Following adequate margin resection, adjuvant RT can be deferred. However adjuvant RT should be considered in the setting of increased risk of local recurrence (eg, mitoses >30/10 hpf, size >10 cm, malignant heterologous elements). Scenarios include (but are not limited to) multiple recurrent phyllodes, and surgically narrow margins due to chest wall with reduced local recurrence threshold. See Principles of Radiation Therapy (SARC-E) for dose recommendations.

Note: All recommendations are category 2A unless otherwise indicated.

Version 3.2026, 03/12/26 © 2026 National Comprehensive Cancer Network® (NCCN®), All rights reserved. NCCN Guidelines® and this illustration may not be reproduced in any form without the express written permission of NCCN.

PLEASE NOTE that use of this NCCN Content is governed by the End-User License Agreement, and you MAY NOT distribute this Content or use it with any artificial intelligence model or tool.
Printed by Ling Lu on 6/26/2026 6:10:47 AM. Copyright © 2026 National Comprehensive Cancer Network, Inc. All Rights Reserved.

National Comprehensive Cancer Network®

NCCN Guidelines Version 3.2026
Malignant Phyllodes Tumor of the Breast

NCCN Guidelines Index
Table of Contents
Discussion

WORKUP

- Prior to the initiation of the treatment plan, all patients should be evaluated and treated by a multidisciplinary team with expertise and experience in phyllodes tumor
- H&P
  - Additional age- and risk-appropriate breast screening
- CT chest (consider CT abdomen/pelvis) with contrast
- Breast MRI with and without contrast
- Consider additional imaging as clinically indicated[e]
- Core needle biopsy may not be sufficient to classify the tumor
- Genetic counseling and testing is recommended for breast[a] and sarcoma genes plus other inherited cancer genes consistent with family phenotype

TREATMENT

Localized resectable disease → **Surgical resection (preferred), with 1 cm margin, expedite initial excision, without delay for staging scans or immediate breast-specific reconstruction due to extreme rapidity of growth and to obtain definitive final histopathologic diagnosis[f]**

- **Mastectomy[b,i,j,k] without axillary staging** → **Negative margins** → **Adjuvant RT following breast conservation surgery[i]**; **Consider adjuvant RT after mastectomy[d,g]**; **Consider adjuvant systemic therapy[h,l]** → **Follow-up** (PHYLL SARC-3)
- **Breast conservation surgery with oncologically appropriate margins[b,j] without axillary staging** → **Negative margins** → **Adjuvant RT following breast conservation surgery[i]**; **Consider adjuvant RT after mastectomy[d,g]**; **Consider adjuvant systemic therapy[h,l]** → **Follow-up** (PHYLL SARC-3)
- **Breast conservation surgery with oncologically appropriate margins[b,j] without axillary staging** → **Positive margins** → **Additional surgical resection to obtain negative margins[c,j]** → **Adjuvant RT following breast conservation surgery[i]**; **Consider adjuvant RT after mastectomy[d,g]**; **Consider adjuvant systemic therapy[h,l]** → **Follow-up** (PHYLL SARC-3)

Unresectable primary disease → **Options:**
- **Definitive RT[g]**
- **Systemic therapy[h]**
- **Best supportive care**

→ **Follow-up** (PHYLL SARC-3)

Synchronous Stage IV disease → (PHYLL SARC-4)

Note: All recommendations are category 2A unless otherwise indicated.

Version 3.2026, 03/12/26 © 2026 National Comprehensive Cancer Network® (NCCN®), All rights reserved. NCCN Guidelines® and this illustration may not be reproduced in any form without the express written permission of NCCN.

PLEASE NOTE that use of this NCCN Content is governed by the End-User License Agreement, and you MAY NOT distribute this Content or use it with any artificial intelligence model or tool.
Printed by Ling Lu on 6/26/2026 6:10:47 AM. Copyright © 2026 National Comprehensive Cancer Network, Inc. All Rights Reserved.

FOOTNOTES

[a] For risk criteria, see NCCN Guidelines for Genetic/Familial High-Risk Assessment: Breast, Ovarian, Pancreatic, and Prostate.

[b] For borderline or malignant phyllodes tumors, wide excision means excision with the intention of obtaining surgical margins ≥1 cm. Narrow surgical margins are associated with increased local recurrence risk, but are not an absolute indication for mastectomy when partial mastectomy fails to achieve a margin width ≥1 cm. Mastectomy may be needed to obtain these margins (considerations may include tumor and breast size).

[c] Radiation therapy is not a substitute for negative margins and additional surgery should be pursued for positive margins.

[d] Following adequate margin resection, adjuvant RT can be deferred. However adjuvant RT should be considered in the setting of increased risk of local recurrence (eg, mitoses >30/10 hpf, size >10 cm, malignant heterologous elements). Scenarios include (but are not limited to) multiple recurrent phyllodes, and surgically narrow margins due to chest wall with reduced local recurrence threshold. See Principles of Radiation Therapy (SARC-E) for dose recommendations.

[e] Given propensity for lung/bone/visceral metastases, consider additional imaging with whole body FDG-PET/CT to evaluate metastatic disease, bone scan, or brain MRI as clinically indicated (Parkes A, et al. Breast Cancer Res Treat 2021;186:871-882; Mituś JW, et al. World J Surg 2016;40:323-328). See Principles of Imaging (SARC-A).

[f] Consider preoperative RT in marginally unresectable disease or when anticipated narrow margins despite radical resection. Effort should be made to expedite the initiation of preoperative RT when recommended by the multidisciplinary team as delays may impact outcomes in this rapidly growing tumor. Surgical re-evaluation should occur during and immediately after preoperative RT to reassess resectability.

[g] Principles of Radiation Therapy (SARC-E).

[h] Systemic Therapy Agents and Regimens with Activity in Soft Tissue Sarcoma Subtypes and Aggressive Soft Tissue Neoplasms (SARC-G).

[i] Data indicate that local recurrence is less likely to occur with mastectomy than breast conservation surgery. If patient has undergone breast conservation surgery, adjuvant RT is recommended regardless of margin status. Neron M, et al. Ann Surg Oncol 2020;27:1818-1827; Bartles SAL, et al. Eur J Cancer 2024;201:113924.

[j] Principles of Surgery (SARC-D).

[k] Due to high rates of local recurrence with narrow or positive margins, attempts at nipple or skin sparing approach in close proximity to the tumor to facilitate reconstruction is discouraged. The goal should be to obtain widely negative margins even if that requires resection of extensive amounts of skin.

[l] Consider systemic therapy if high risk for occult metastatic disease or high-risk features (eg, mitoses >30/10 hpf, size >10 cm, malignant heterologous elements). Use of systemic therapy should be discussed with a multidisciplinary team with expertise and experience in phyllodes tumor and considered after careful discussion with surgeon.

Note: All recommendations are category 2A unless otherwise indicated.

PLEASE NOTE that use of this NCCN Content is governed by the End-User License Agreement, and you MAY NOT distribute this Content or use it with any artificial intelligence model or tool.
Printed by Ling Lu on 6/26/2026 6:10:47 AM. Copyright © 2026 National Comprehensive Cancer Network, Inc. All Rights Reserved.

FOLLOW-UP

Patient rendered without evidence of disease who presented with localized or oligometastatic disease

→

- **Evaluation for rehabilitation (SARC-D 3 of 4)**
- **H&P and imaging (includes CT chest/abdomen/pelvis (C/A/P) and breast/chest MRI with and without contrast) every 3–6 mo for 3 y, then every 6 mo, to complete a total of 5 y, then annually[m,n]**
- **Age- and risk-appropriate breast screening (eg, mammogram)**

→

Local recurrence or Metastatic disease

→ **PHYLLSARC-5**

[m] Principles of Imaging (SARC-A).
[n] Consider symptom-driven brain MRI with and without contrast for 5 years for malignant phyllodes tumor.

Note: All recommendations are category 2A unless otherwise indicated.

Version 3.2026, 03/12/26 © 2026 National Comprehensive Cancer Network® (NCCN®), All rights reserved. NCCN Guidelines® and this illustration may not be reproduced in any form without the express written permission of NCCN.

PLEASE NOTE that use of this NCCN Content is governed by the End-User License Agreement, and you MAY NOT distribute this Content or use it with any artificial intelligence model or tool.
Printed by Ling Lu on 6/26/2026 6:10:47 AM. Copyright © 2026 National Comprehensive Cancer Network, Inc. All Rights Reserved.

NCCN Guidelines Version 3.2026
Malignant Phyllodes Tumor of the Breast

NCCN Guidelines Index
Table of Contents
Discussion

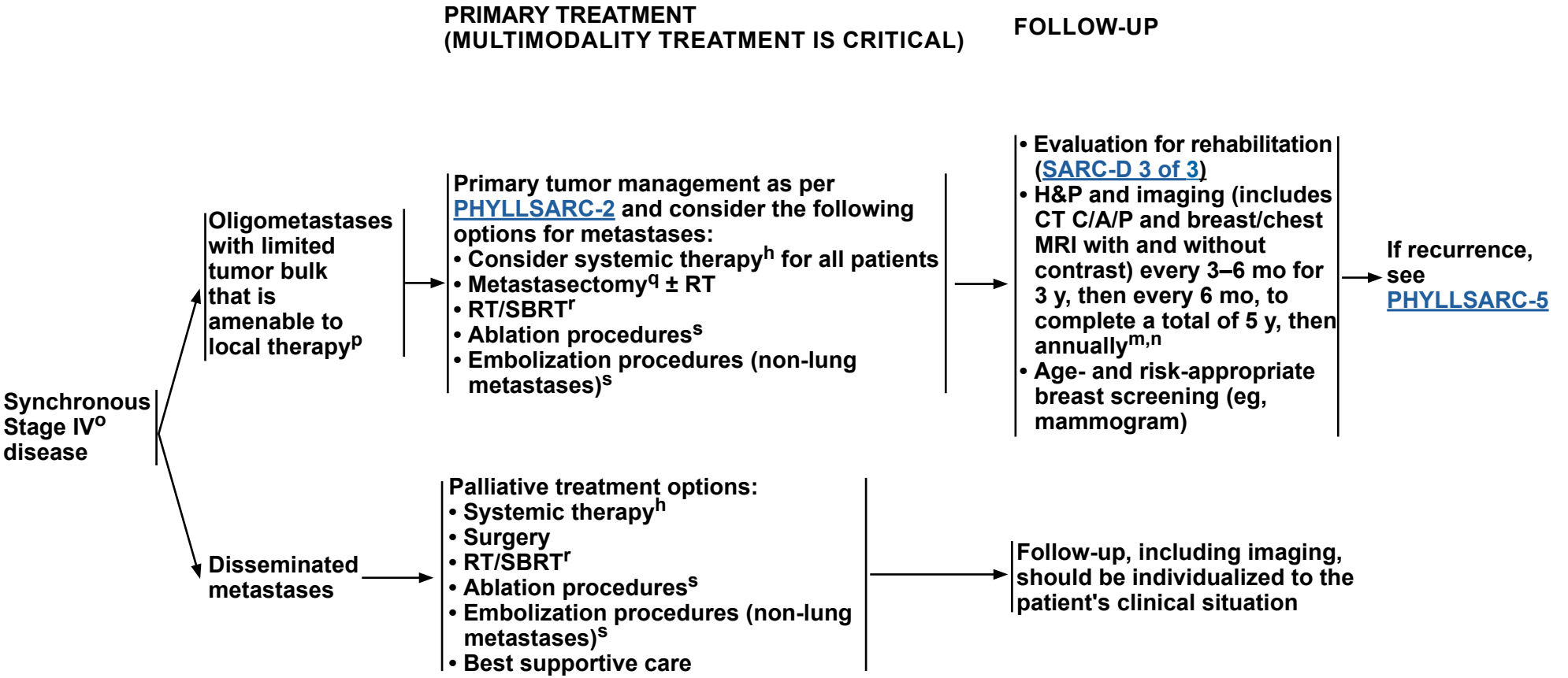

Footnotes on PHYLLSARC-4A

Note: All recommendations are category 2A unless otherwise indicated.

Version 3.2026, 03/12/26 © 2026 National Comprehensive Cancer Network® (NCCN®), All rights reserved. NCCN Guidelines® and this illustration may not be reproduced in any form without the express written permission of NCCN.

PLEASE NOTE that use of this NCCN Content is governed by the End-User License Agreement, and you MAY NOT distribute this Content or use it with any artificial intelligence model or tool.
Printed by Ling Lu on 6/26/2026 6:10:47 AM. Copyright © 2026 National Comprehensive Cancer Network, Inc. All Rights Reserved.

FOOTNOTES

[h] Systemic Therapy Agents and Regimens with Activity in Soft Tissue Sarcoma Subtypes and Aggressive Soft Tissue Neoplasms (SARC-G).

[m] Principles of Imaging (SARC-A).

[n] Consider symptom-driven brain MRI with and without contrast for 5 years for malignant phyllodes tumor.

[o] The Panel endorses the College of American Pathologists Protocol for standardized pathology reporting for all phyllodes tumors (https://documents.cap.org/protocols/Breast.Phyllodes_1.1.0.1.REL_CAPCP.pdf).

[p] Patients with lymph node involvement (including isolated regional nodal metastatic disease) should undergo regional lymph node dissection ± RT.

[q] Metastasectomy is the historical standard for patients with oligometastatic disease (primarily lung); the ultimate choice of local control modality may depend on factors such as performance status, patient preference, lesion location/accessibility, ability to preserve normal tissue function, and anticipated morbidity of a treatment modality. In a multicenter retrospective study of 51 patients with metastatic malignant phyllodes tumors, multivariate analysis showed that surgery of metastasis was independently associated with overall survival (OS) (HR, 0.33; 95% CI, 0.14–0.78) (Neron M, et al. Ann Surg Oncol 2020;27:1693-1699).

[r] In retrospective studies, various SBRT dosing regimens have been reported to be effective for treatment of sarcoma metastases. Dose and fractionation should be determined by an experienced radiation oncologist based on normal tissue constraints (Dhakal S, et al. Int J Radiat Oncol Biol Phys 2012;82:940-945; Navarria P, et al. Eur J Cancer 2015;51:668-674; Baumann BC, et al. J Surg Oncol 2020;122:877-883).

[s] Principles of Interventional Oncology (SARC-F).

Note: All recommendations are category 2A unless otherwise indicated.

PLEASE NOTE that use of this NCCN Content is governed by the End-User License Agreement, and you MAY NOT distribute this Content or use it with any artificial intelligence model or tool.
Printed by Ling Lu on 6/26/2026 6:10:47 AM. Copyright © 2026 National Comprehensive Cancer Network, Inc. All Rights Reserved.

PRIMARY TREATMENT
(MULTIMODALITY TREATMENT IS CRITICAL)

Local recurrence → Follow Workup, then appropriate Primary Treatment[t] pathway (PHYLLSARC-1 for borderline phyllodes or PHYLLSARC-2 for malignant phyllodes)

Metastatic disease[o]

- **Oligometastases with limited tumor bulk that is amenable to local therapy[p]** →
  - Consider systemic therapy[h] for all patients
  - Metastasectomy[q] ± RT
  - RT/SBRT[r]
  - Ablation procedures[s]
  - Embolization procedures (non-lung metastases)[s]
- **Disseminated metastases** →
  - Palliative treatment options:
  - Systemic therapy[h]
  - Surgery
  - RT/SBRT[r]
  - Ablation procedures[s]
  - Embolization procedures (non-lung metastases)[s]
  - Best supportive care

Footnotes on PHYLLSARC-5A

Note: All recommendations are category 2A unless otherwise indicated.

Version 3.2026, 03/12/26 © 2026 National Comprehensive Cancer Network® (NCCN®), All rights reserved. NCCN Guidelines® and this illustration may not be reproduced in any form without the express written permission of NCCN.

PLEASE NOTE that use of this NCCN Content is governed by the End-User License Agreement, and you MAY NOT distribute this Content or use it with any artificial intelligence model or tool.
Printed by Ling Lu on 6/26/2026 6:10:47 AM. Copyright © 2026 National Comprehensive Cancer Network, Inc. All Rights Reserved.

FOOTNOTES

[h] Systemic Therapy Agents and Regimens with Activity in Soft Tissue Sarcoma Subtypes and Aggressive Soft Tissue Neoplasms (SARC-G).

[o] The Panel endorses the College of American Pathologists Protocol for standardized pathology reporting for all phyllodes tumors (https://documents.cap.org/protocols/Breast.Phyllodes_1.1.0.1.REL_CAPCP.pdf).

[p] Patients with lymph node involvement (including isolated regional nodal metastatic disease) should undergo regional lymph node dissection ± RT.

[q] Metastasectomy is the historical standard for patients with oligometastatic disease (primarily lung); the ultimate choice of local control modality may depend on factors such as performance status, patient preference, lesion location/accessibility, ability to preserve normal tissue function, and anticipated morbidity of a treatment modality. In a multicenter retrospective study of 51 patients with metastatic malignant phyllodes tumors, multivariate analysis showed that surgery of metastasis was independently associated with OS (HR, 0.33; 95% CI, 0.14–0.78) (Neron M, et al. Ann Surg Oncol 2020;27:1693-1699).

[r] In retrospective studies, various SBRT dosing regimens have been reported to be effective for treatment of sarcoma metastases. Dose and fractionation should be determined by an experienced radiation oncologist based on normal tissue constraints (Dhakal S, et al. Int J Radiat Oncol Biol Phys 2012;82:940-945; Navarria P, et al. Eur J Cancer 2015;51:668-674; Baumann BC, et al. J Surg Oncol 2020;122:877-883).

[s] Principles of Interventional Oncology (SARC-F).

[t] If local recurrence can be excised, a decision will need to be made on a case-by-case basis whether reirradiation is possible. Some case series suggest benefit with reirradiation (Catton C, et al. Radiother Oncol 1996;41:209-214) while others do not (Torres MA, et al. Int J Radiat Oncol Biol Phys 2007;67:1124-1129), likely reflecting differences in selection of patients for treatment with surgery and radiotherapy or surgery alone. Brachytherapy, IMRT, and/or proton beam therapy may be utilized to reduce the morbidity of reirradiation.

Note: All recommendations are category 2A unless otherwise indicated.

Version 3.2026, 03/12/26 © 2026 National Comprehensive Cancer Network® (NCCN®), All rights reserved. NCCN Guidelines® and this illustration may not be reproduced in any form without the express written permission of NCCN.

PLEASE NOTE that use of this NCCN Content is governed by the End-User License Agreement, and you MAY NOT distribute this Content or use it with any artificial intelligence model or tool.
Printed by Ling Lu on 6/26/2026 6:10:47 AM. Copyright © 2026 National Comprehensive Cancer Network, Inc. All Rights Reserved.

PRINCIPLES OF IMAGING

- Contrasted cross-sectional imaging with MRI (with and without contrast) is preferred over CT (with contrast, unless otherwise stated). For long-term survivors, chest x-rays and nonionizing imaging modalities may be considered to minimize radiation exposure.A multidisciplinary team should manage all patients. Consider FDG-PET/Fused 3-dimensional imaging[a] in staging, prognostication, grading, and determining response to chemotherapy.
- Some STS histologies and presentations have a unique metastatic pattern that would necessitate additional sites of staging/surveillance imaging, in addition to the recommended primary sites.

Table 1

Histologic Subtype(s)	Locations to Image	Imaging Modality	Reason
All	• Primary site	• MRI (preferred for extremity/body wall, head and neck, and cardiac) and/or CT (preferred for retroperitoneum)	• For initial workup and follow-up
All (with exception of WDLPS)	• Lungs	• CT chest (preferred) or CXR	• For initial workup and follow-up given propensity for lung metastases
Alveolar soft part sarcoma (ASPS)	• Central nervous system (CNS)	• MRI brain (preferred) or CT brain	• For initial workup and follow-up given propensity for CNS metastases
	• Bone	• Consider FDG-PET imaging (CT or MRI) or bone scan	• For initial workup and follow-up given propensity for bone metastases
Angiosarcoma	• Abdomen/Pelvis	• CT abdomen/pelvis or MRI abdomen/pelvis	• For initial workup and follow-up given propensity for abdominal/pelvic metastases
	• CNS	• Consider MRI brain (preferred) or CT brain	• For initial workup and follow-up given propensity for CNS metastases
	• Regional lymph node basin[1]	• Consider CT or FDG-PET imaging (CT or MRI)	• For initial workup and follow-up given propensity for nodal metastatic disease
Cardiac sarcoma (left sided)	• CNS	• Consider MRI brain (preferred) or CT brain	• For initial workup and follow-up given propensity for CNS metastases
Clear cell sarcoma	• Regional lymph node basin[1]	• Consider CT or FDG-PET imaging (CT or MRI)	• For initial workup and follow-up given propensity for nodal metastatic disease
	• Bone	• Consider FDG-PET imaging (CT or MRI) or bone scan	• For initial workup and follow-up given propensity for bone metastases

Continued on next page

[a] FDG-PET/CT is more common but FDG-PET/MRI can be considered depending on availability and physician's opinion.

[1] Basile G, Mattei JC, Alshaygy I, et al. Curability of patients with lymph node metastases from extremity soft-tissue sarcoma. Cancer 2020;126:5098-5108.

Note: All recommendations are category 2A unless otherwise indicated.

Version 3.2026, 03/12/26 © 2026 National Comprehensive Cancer Network® (NCCN®), All rights reserved. NCCN Guidelines® and this illustration may not be reproduced in any form without the express written permission of NCCN.

PLEASE NOTE that use of this NCCN Content is governed by the End-User License Agreement, and you MAY NOT distribute this Content or use it with any artificial intelligence model or tool.
Printed by Ling Lu on 6/26/2026 6:10:47 AM. Copyright © 2026 National Comprehensive Cancer Network, Inc. All Rights Reserved.

PRINCIPLES OF IMAGING

Table 1 (continued)

Histologic Subtype(s)	Locations to Image	Imaging Modality	Reason
Epithelioid sarcoma	• Abdomen/Pelvis	• CT abdomen/pelvis or MRI abdomen/pelvis	• For initial workup and follow-up given propensity for abdominal/pelvic metastases
	• Regional lymph node basin[1]	• Consider CT or FDG-PET imaging (CT or MRI)	• For initial workup and follow-up given propensity for nodal metastatic disease
Leiomyosarcoma	• Liver	• CT abdomen/pelvis or MRI abdomen/pelvis	• For initial workup and follow-up given propensity for liver metastases
	• Bone	• Consider FDG-PET imaging (CT or MRI) or bone scan	• For initial workup and follow-up given propensity for bone metastases
Myxoid/Round cell liposarcoma	• Abdomen/Pelvis	• CT abdomen/pelvis or MRI abdomen/pelvis	• For initial workup and follow-up given propensity for abdominal/pelvic metastases
	• Total spine	• MRI total spine	• For initial workup and follow-up given propensity for spine metastases
	• Soft tissues	• Consider whole body (WB) MRI (preferred), as PET and CT may not identify extrapulmonary disease. ▸ If WB MRI unavailable, consider PET/CT	• For initial workup and follow-up given propensity for soft tissue metastases
Rhabdomyosarcoma	• Regional lymph node basin[1]	• CT or FDG-PET imaging (CT or MRI)	• For initial workup and follow-up given propensity for nodal metastatic disease
	• Bone	• Consider FDG-PET imaging (CT or MRI) or bone scan	• For initial workup and follow-up given propensity for bone metastases
WDLPS/ Dedifferentiated liposarcoma	• Retroperitoneal/Intra-abdominal	• Consider FDG-PET imaging (CT or MRI)	• To help differentiate between WDLPS and dedifferentiated liposarcoma and to help determine site for biopsy
Select histologies in which neoadjuvant therapy is being used	• Any site	• Consider FDG-PET imaging (CT or MRI)	• FDG-PET imaging (CT or MRI) may be useful in staging, prognostication, grading, and determining response to neoadjuvant therapy

[1] Basile G, Mattei JC, Alshaygy I, et al. Curability of patients with lymph node metastases from extremity soft-tissue sarcoma. Cancer 2020;126:5098-5108.

Note: All recommendations are category 2A unless otherwise indicated.

Version 3.2026, 03/12/26 © 2026 National Comprehensive Cancer Network® (NCCN®), All rights reserved. NCCN Guidelines® and this illustration may not be reproduced in any form without the express written permission of NCCN.

PLEASE NOTE that use of this NCCN Content is governed by the End-User License Agreement, and you MAY NOT distribute this Content or use it with any artificial intelligence model or tool.
Printed by Ling Lu on 6/26/2026 6:10:47 AM. Copyright © 2026 National Comprehensive Cancer Network, Inc. All Rights Reserved.

PRINCIPLES OF IMAGING

STS of extremity, superficial/trunk, or head and neck (refer to SARC-A for guidance on imaging of specific histologic subtypes)
The differential diagnosis of STS of the extremities includes benign lesions and other malignant entities.

Evaluation and Workup
- Imaging of the primary tumor
  - MRI (preferred) or CT (less sensitive)
  - CT angiogram and plain radiographs may be useful in certain circumstances
- Staging includes chest imaging
  - CT chest without contrast (preferred) or plain radiographs (less sensitive)

Some STS histologies and presentations have a unique metastatic pattern that would necessitate additional sites of staging/surveillance imaging, in addition to the recommended primary sites.

- Consider the following:
  - For angiosarcoma
    - ◊ CNS MRI (or CT if MRI is contraindicated)
    - ◊ Consider CT or FDG-PET imaging (CT or MRI) to evaluate regional lymph node basin
    - ◊ Consider FDG-PET/CT or bone scan to evaluate bones
  - For cardiac sarcoma (left sided)
    - ◊ Consider CNS MRI (or CT if MRI is contraindicated)
  - For clear cell sarcoma
    - ◊ Consider CT or FDG-PET imaging (CT or MRI) to evaluate regional lymph node basin
    - ◊ Consider FDG-PET/CT or bone scan to evaluate bones
  - For epithelioid sarcoma
    - ◊ CT or MRI abdomen/pelvis
    - ◊ Consider CT or FDG-PET/CT to evaluate regional lymph node basin
  - For leiomyosarcoma
    - ◊ CT or MRI abdomen/pelvis
    - ◊ Consider FDG-PET imaging (CT or MRI) or bone scan to evaluate bones
  - For myxoid/round cell liposarcoma
    - ◊ CT or MRI abdomen/pelvis
    - ◊ MRI of the total spine
    - ◊ Consider WB MRI (preferred) to evaluate soft tissues
    - ◊ If unavailable, consider FDG-PET imaging (CT or MRI)
  - For rhabdomyosarcoma
    - ◊ CT or FDG-PET imaging (CT or MRI) to evaluate regional lymph node basin
    - ◊ Consider FDG-PET imaging (CT or MRI) or bone scan to evaluate bones

Surveillance
- Long-term follow-up
  - Consider MRI (preferred) or CT (less sensitive) when MR is contraindicated
- Consider ultrasound (US) to detect early local recurrence/small nodules <0.5 cm
- Chest imaging is useful for the detection of asymptomatic distant recurrence while primary site imaging may only be useful for patients at high-risk of local recurrence
  - CT chest without contrast (preferred) or plain radiographs (less sensitive)
- MRI should be preferably used for surveillance of primary site. US may aid in problem solving: solid nodule versus seroma/hematoma formation, or very small nodules <0.5 cm

Note: All recommendations are category 2A unless otherwise indicated.

Version 3.2026, 03/12/26 © 2026 National Comprehensive Cancer Network® (NCCN®), All rights reserved. NCCN Guidelines® and this illustration may not be reproduced in any form without the express written permission of NCCN.

PLEASE NOTE that use of this NCCN Content is governed by the End-User License Agreement, and you MAY NOT distribute this Content or use it with any artificial intelligence model or tool.
Printed by Ling Lu on 6/26/2026 6:10:47 AM. Copyright © 2026 National Comprehensive Cancer Network, Inc. All Rights Reserved.

PRINCIPLES OF IMAGING

STS of extremity, superficial/trunk, or head and neck (continued)

Surveillance (continued)
- Follow-up schedule by disease stage
  - Higher grade/larger tumors have a higher risk of dissemination
  - Internal hemorrhage/capsular rupture may have a higher risk of dissemination as well
  - Surveillance is more rigorous, especially during the first 5 years post resection
    - ◊ After 10 years, follow-up should be individualized
- Stage I tumors
  - Consider chest imaging every 6–12 months
    - ◊ CT without contrast (preferred) or plain radiographs (less sensitive)
  - Postoperative baseline and periodic imaging of the primary tumor site is recommended based upon risk of locoregional recurrence
    - ◊ MRI (preferred) or CT (less sensitive)
- Stage II/III and synchronous stage IV disease
  - Postoperative reimaging to assess the primary tumor site and rule out metastatic disease
    - ◊ MRI (preferred) or CT (less sensitive)
  - Baseline and periodic imaging of the primary site are recommended based upon risk of locoregional recurrence
  - Imaging of the chest and other known sites of metastatic disease should be performed every 2–6 months for 2–3 years, then every 6 months to complete a total of 5 years, and then annually
    - ◊ CT without contrast (preferred) or plain radiographs (less sensitive)

Retroperitoneal or intra-abdominal STS
- The differential diagnosis of retroperitoneal/intra-abdominal soft tissue mass includes malignant lesions (such as other sarcomas, GIST, lymphomas, or germ cell tumors), desmoids, and benign lesions. Workup and evaluation recommendations are similar to that of extremity sarcomas. Pre-resection biopsy is not necessary for all patients; however, confirmation of a sarcoma diagnosis (including histologic subtype) is required for patients being considered for neoadjuvant therapy. Image-guided (CT or US) core needle biopsy is preferred over surgical biopsy and should be performed if neoadjuvant therapy is being considered or for suspicion of malignancy other than sarcoma.

Evaluation and Workup
- CT with contrast is preferred, although MRI is useful in certain circumstances.
- Chest imaging should be performed for histologies that have the potential for lung metastases
  - CT without contrast (preferred) or plain radiographs (less sensitive)
- For unresectable or stage IV disease, follow-up imaging is recommended to assess treatment response (RETSARC-4).
  - Options include CT with contrast (preferred) or MRI
- Patients whose tumors become resectable following primary treatment should be managed as described for resectable disease (RETSARC-2).

Surveillance
- Follow-up imaging every 3–6 months for 3 years, then every 6 months to complete a total of 5 years, and then annually, following management of primary disease (RETSARC-3)
  - Chest/abdomen/pelvis CT (preferred) or MRI

Note: All recommendations are category 2A unless otherwise indicated.

Version 3.2026, 03/12/26 © 2026 National Comprehensive Cancer Network® (NCCN®), All rights reserved. NCCN Guidelines® and this illustration may not be reproduced in any form without the express written permission of NCCN.

PLEASE NOTE that use of this NCCN Content is governed by the End-User License Agreement, and you MAY NOT distribute this Content or use it with any artificial intelligence model or tool.
Printed by Ling Lu on 6/26/2026 6:10:47 AM. Copyright © 2026 National Comprehensive Cancer Network, Inc. All Rights Reserved.

PRINCIPLES OF IMAGING

Desmoid tumors (aggressive fibromatoses)

The differential diagnosis for desmoids depends on location; it includes other sarcomas, other malignant carcinomas, and benign lesions.

Evaluation and Workup

- Imaging of the primary site as clinically indicated
  - Contrasted cross-sectional imaging with MRI (with and without contrast) is preferred over CT (with contrast, unless otherwise stated).

Surveillance

- Imaging every 3–6 months for 3 years and then every 6–12 months thereafter
  - Contrasted cross-sectional imaging with MRI (with and without contrast) is preferred over CT (with contrast, unless otherwise stated).
  - US may be considered for select locations (eg, abdominal wall) for long-term follow-up. US should be done by an ultrasonographer experienced in musculoskeletal disease[2]
- Disease progression or recurrence should be managed as described under primary treatment for resectable or unresectable disease

Rhabdomyosarcoma (RMS)

- FDG-PET imaging (CT or MRI) can be useful in certain circumstances for initial staging due to the possibility of nodal metastases and the appearance of unusual sites of initial metastatic disease

[2] Choi H, et al. AJR Am J Roentgenol 1991;157:353-358.

Note: All recommendations are category 2A unless otherwise indicated.

Version 3.2026, 03/12/26 © 2026 National Comprehensive Cancer Network® (NCCN®), All rights reserved. NCCN Guidelines® and this illustration may not be reproduced in any form without the express written permission of NCCN.

PLEASE NOTE that use of this NCCN Content is governed by the End-User License Agreement, and you MAY NOT distribute this Content or use it with any artificial intelligence model or tool.
Printed by Ling Lu on 6/26/2026 6:10:47 AM. Copyright © 2026 National Comprehensive Cancer Network, Inc. All Rights Reserved.

PRINCIPLES OF PATHOLOGIC ASSESSMENT OF SARCOMA SPECIMENS[1]

- Biopsy should establish malignancy, provide a specific diagnosis where possible, and provide a grade where appropriate or feasible, recognizing that limited biopsy material may underestimate grade.
- In patients without a definitive diagnosis following initial biopsy due to limited sampling size, repeat image-guided core needle biopsy or, if necessary, incisional biopsy should be considered to make a diagnosis.
- Pathologic assessment of biopsies and resection specimens should be carried out by an experienced sarcoma pathologist.
- Morphologic diagnosis based on microscopic examination of histologic sections remains the gold standard for sarcoma diagnosis. However, since several ancillary techniques are useful in support of morphologic diagnosis (including immunohistochemistry [IHC], classical cytogenetics, and molecular genetic testing), sarcoma diagnosis should be carried out by pathologists who have access to these ancillary methods.[2]
- The pathologic assessment should include evaluation of the following features, all of which should be specifically addressed in the pathology report:

  - Organ, site, and operative procedure
  - Primary diagnosis (using standardized nomenclature, such as the WHO Classification of Tumors of Soft Tissue and Bone[3])
  - Size of tumor
  - Histologic grade (at the least, specify low or high grade if applicable); ideally, grade using the Fédération Nationale des Centres de Lutte Contre le Cancer (FNCLCC) Sarcoma Group, NCI system, or appropriate diagnosis-specific grading system if applicable
  - Necrosis
    - ◊ Present or absent
    - ◊ Approximate extent (percentage)
  - Status of margins of excision
    - ◊ Uninvolved
    - ◊ Close (state which margins, the measured distance, and the nature of the adjacent tissue such as fascia)
    - ◊ Involved (state which margins)
    - ◊ Cannot be assessed
  - Status of lymph nodes
    - ◊ Site
    - ◊ Number examined
    - ◊ Number positive
  - Results of ancillary studies[2]
    - ◊ Type of testing (ie, electron microscopy, IHC, molecular genetic analysis)
    - ◊ Where performed
  - Additional tumor features of potential clinical value
    - ◊ Mitotic rate per 10 high-power fields (HPFs)
    - ◊ Presence or absence of vascular invasion
    - ◊ Character of tumor margin (well circumscribed or infiltrative)
    - ◊ For some tumors, characterization of the inflammatory infiltrate by immunohistochemical or other ancillary studies may be helpful (type and extent).
    - ◊ For patients who have received neoadjuvant therapy, information on treatment response and viable tumor
  - TNM stage (see ST-5 through ST-7)

[1] Laurini JA, Cooper K, Fletcher CDM, et al. Protocol for the examination of specimens from patients with soft tissue tumors. CAP Guidelines, 2017.
[2] Principles of Ancillary Techniques Useful in the Diagnosis of Sarcomas (SARC-C).
[3] WHO Classification of Tumours Editorial Board. Soft tissue and bone tumours. Lyon, France: International Agency for Research on Cancer; 2020. (WHO classification of tumours series, 5th ed; vol 3).

Note: All recommendations are category 2A unless otherwise indicated.

Version 3.2026, 03/12/26 © 2026 National Comprehensive Cancer Network® (NCCN®), All rights reserved. NCCN Guidelines® and this illustration may not be reproduced in any form without the express written permission of NCCN.

PLEASE NOTE that use of this NCCN Content is governed by the End-User License Agreement, and you MAY NOT distribute this Content or use it with any artificial intelligence model or tool.
Printed by Ling Lu on 6/26/2026 6:10:47 AM. Copyright © 2026 National Comprehensive Cancer Network, Inc. All Rights Reserved.

PRINCIPLES OF ANCILLARY TECHNIQUES USEFUL IN THE DIAGNOSIS OF SARCOMAS

Morphologic diagnosis based on microscopic examination of histologic sections remains the gold standard for sarcoma diagnosis. However, several ancillary techniques are useful in support of morphologic diagnosis, including IHC, classical cytogenetics, electron microscopy, and molecular genetic testing. Molecular genetic testing has emerged as an ancillary testing approach since many sarcoma types harbor characteristic genetic aberrations, including single base pair substitutions, deletions and amplifications, and translocations. Molecular testing utilizes multiple techniques such as fluorescence in situ hybridization (FISH), polymerase chain reaction (PCR)-based methods, or next-generation sequencing (NGS)-based methods (including DNA and RNA sequencing).[1] The selection of the "best" technique depends on the individual tumor and clinical needs. NGS may be beneficial; the timing of when to perform NGS and for which patients must be evaluated individually. NGS findings can: determine patient eligibility for clinical trials, identify actionable mutations that may not have been targeted previously, and select patients who may benefit from immunotherapy. Thus, NGS may be appropriate for patients who may qualify for and who are interested in enrolling in a clinical trial or for patients with disease that is refractory or has progressed on standard therapies. NGS also may be helpful in certain histologies where NGS is likely to provide clinically actionable information. NGS should not replace expert pathology review, as NGS only rarely results in a diagnosis change following expert review. Technically successful NGS on bone biopsies requires use of decalcification agents, such as ethylenediaminetetraacetic acid (EDTA), that do not interfere with genomic testing. Each type of molecular testing is associated with test limitations and sources of false-negative results; if negative results are received when a molecular aberration clinically was expected, discussion with the testing lab is highly recommended as testing by another technique may be indicated. Selected recurrent genetic aberrations in sarcoma[2,3] are listed on the next page.

[1] Molecular genetic analysis involves highly complex test methods. None of the methods are absolutely sensitive or provide results that are absolutely specific; test results must always be interpreted in the context of the clinical and pathologic features of the case. Testing should therefore be carried out by a pathologist with expertise in sarcoma diagnosis and molecular diagnostic techniques.
[2] This table is not exhaustive for either sarcomas with characteristic genetic changes or the genes involved.
[3] Similar translocations can be seen in very different diseases; eg, *EWSR1::ATF1* can be seen in both angiomatoid fibrous histiocytoma as well as clear cell sarcoma.

Note: All recommendations are category 2A unless otherwise indicated.

Version 3.2026, 03/12/26 © 2026 National Comprehensive Cancer Network® (NCCN®), All rights reserved. NCCN Guidelines® and this illustration may not be reproduced in any form without the express written permission of NCCN.

PLEASE NOTE that use of this NCCN Content is governed by the End-User License Agreement, and you MAY NOT distribute this Content or use it with any artificial intelligence model or tool.
Printed by Ling Lu on 6/26/2026 6:10:47 AM. Copyright © 2026 National Comprehensive Cancer Network, Inc. All Rights Reserved.

PRINCIPLES OF ANCILLARY TECHNIQUES USEFUL IN THE DIAGNOSIS OF SARCOMAS

TUMOR	ABERRATION	GENE(S) INVOLVED
Malignant Round Cell Tumors		
Alveolar RMS	t(2;13)(q35;q14) t(1;13)(p36;q14) t(X;2)(q13;q35)	*PAX3::FOXO1* *PAX7::FOXO1* *PAX3::AFX*
Desmoplastic small round cell tumor	t(11;22)(p13;q12)	*EWSR1::WT1*
Embryonal RMS	Complex alterations	Multiple, *MYOD1, KRAS, HRAS, TP53, NF1, NRAS, PIK3CA, FBXW7, FGFR4, BCOR*
Ewing sarcoma/peripheral neuroectodermal tumor	t(11;22)(q24;q12) t(21;22)(q22;q12) t(2;22)(q33;q12) t(7;22)(p22;q12) t(17;22)(q12;q12) inv(22)(q12;q12) t(16;21)(p11;q22)	*EWSR1::FLI1* *EWSR1::ERG* *EWSR1::FEV* *EWSR1::ETV1* *EWSR1::E1AF* *EWSR1::ZSG* *FUS::ERG*
Undifferentiated round cell sarcoma	t(4;19)(q35;q13) or t(10;19)(q26;q13) inv(X)(p11.4;p11.22)	*CIC::DUX4*[4] *BCOR::CCNB3*[5]
Lipomatous Tumors		
ALT/WDLPS	Supernumerary ring chromosomes; giant marker chromosomes	Amplification of region 12q13-15, including *MDM2, CDK4, HMGA2, SAS, GLI*
Dedifferentiated liposarcoma	Same as for ALT/WDLPS	Same as for ALT/WDLPS
Myxoid/round cell liposarcoma	t(12;16)(q13;p11) t(12;22)(q13;q12)	*FUS::DDIT3* *EWSR1::DDIT3*
Pleomorphic liposarcoma	Complex alterations	Unknown

[4] Yoshimoto T, Tanaka M, Homme M, et al. CIC-DUX4 induces small round cell sarcomas distinct from Ewing sarcoma. Cancer Res 2017;77:2927-2937.
[5] Kao YC, Owosho AA, Sung YS, et al. BCOR-CCNB3-fusion positive sarcomas: A clinicopathologic and molecular analysis of 36 cases with comparison to morphologic spectrum and clinical behavior of other round cell sarcomas. Am J Surg Path 2018;42:604-615.

Note: All recommendations are category 2A unless otherwise indicated.

Version 3.2026, 03/12/26 © 2026 National Comprehensive Cancer Network® (NCCN®), All rights reserved. NCCN Guidelines® and this illustration may not be reproduced in any form without the express written permission of NCCN.

PLEASE NOTE that use of this NCCN Content is governed by the End-User License Agreement, and you MAY NOT distribute this Content or use it with any artificial intelligence model or tool.
Printed by Ling Lu on 6/26/2026 6:10:47 AM. Copyright © 2026 National Comprehensive Cancer Network, Inc. All Rights Reserved.

PRINCIPLES OF ANCILLARY TECHNIQUES USEFUL IN THE DIAGNOSIS OF SARCOMAS

TUMOR	ABERRATION	GENE(S) INVOLVED
Other Sarcomas		
Alveolar soft part sarcoma	der(17)t(X;17)(p11;q25)	*ASPL::TFE3*
Angiomatoid fibrous histiocytoma	t(12;22)(q13;q12) t(2;22)(q33;q12) t(12;16)(q13;p11)	*EWSR1::ATF1* *EWSR1::CREB1* *FUS::ATF1*
Clear cell sarcoma	t(12;22)(q13;q12) t(2;22)(q33;q12)	*EWSR1::ATF1* *EWSR1::CREB1*
Congenital/infantile fibrosarcoma	t(12;15)(p13;q25)	*ETV6::NTRK3*[6]
Dermatofibrosarcoma protuberans	t(17;22)(q21;q13) and derivative ring chromosomes	*COL1A1::PDGFB*
Desmoid fibromatosis	Trisomy 8 or 20; loss of 5q21	*CTNNB1 or APC* mutations
High-grade endometrial stromal sarcoma	t(10;17)(q22;p13) t(x;22)(p11;q13)	*YWHAE::NUTM2* *ZC3H7B::BCOR*[7]
Epithelioid hemangioendothelioma	t(1;3)(p36;q25) t(X;11)(p11.23; q22.1)	*WWTR1::CAMTA1* *YAP1::TFE3*
Epithelioid sarcoma	Inactivation, deletion, or mutation of *INI1* (*SMARCB-1*)	*INI1 (SMARCB-1)*
Extrarenal rhabdoid tumor	Inactivation of *INI1* (*SMARCB-1*)	*INI1 (SMARCB-1)*
Extraskeletal myxoid chondrosarcoma	t(9;22)(q22;q12) t(9;17)(q22;q11) t(9;15)(q22;q21) t(3;9)(q11;q22)	*EWSR1::NR4A3* *TAF2N::NR4A3* *TCF12::NR4A3* *TFG::NR4A3*
Sporadic and familial GIST Carney-Stratakis syndrome (gastric GIST and paraganglioma)	Activating kinase mutations Krebs cycle mutation	*KIT* or *PDGFRA* Germline *SDH* subunit mutations

[6] Yamamoto H, Yoshida A, Taguchi K, et al. ALK, ROS1 and NTRK3 gene rearrangements in inflammatory myofibroblastic tumours. Histopathology 2016;69:72-83.
[7] Lewis N, Soslow RA, Delair DF, et al. ZC3H7B-BCOR high-grade endometrial stromal sarcomas: a report of 17 cases of a newly defined entity. Mod Pathol 2018;31:674-684.

Note: All recommendations are category 2A unless otherwise indicated.

Version 3.2026, 03/12/26 © 2026 National Comprehensive Cancer Network® (NCCN®), All rights reserved. NCCN Guidelines® and this illustration may not be reproduced in any form without the express written permission of NCCN.

PLEASE NOTE that use of this NCCN Content is governed by the End-User License Agreement, and you MAY NOT distribute this Content or use it with any artificial intelligence model or tool.
Printed by Ling Lu on 6/26/2026 6:10:47 AM. Copyright © 2026 National Comprehensive Cancer Network, Inc. All Rights Reserved.

PRINCIPLES OF ANCILLARY TECHNIQUES USEFUL IN THE DIAGNOSIS OF SARCOMAS

TUMOR	ABERRATION	GENE(S) INVOLVED
Inflammatory myofibroblastic tumor (IMT)	t(1;2)(q22;p23) t(2;19)(p23;p13) t(2;17)(p23;q23) t(2;2)(p23;q13) t(2;11)(p23;p15) inv(2)(p23;q35)	*TPM3::ALK*[6] *TPM4::ALK*[6] *CLTC::ALK*[6] *RANBP2::ALK*[6] *CARS::ALK*[6] *ATIC::ALK*[6] *ETV6::NTRK3*[6,8] *TFG::ROS1*[8-10]
Low-grade fibromyxoid sarcoma/sclerosing epithelioid fibrosarcoma	t(7;16)(q33;p11) t(11;16)(p11;p11)	*FUS::CREB3L2* *FUS::CREB3L1*
Malignant peripheral nerve sheath tumor (MPNST)		*NF1, CDKN2A* and *EED* or *SUZ12*
Mesenchymal chondrosarcoma	t(8;8)(q13;q21)	*HEY1::NCOA2*
NTRK-rearranged spindle cell neoplasm[a,11]	Multiple	*NTRK 1, 2, 3*
Solitary fibrous tumor	inv(12)(q13;q13)	*NAB2::STAT6*
Synovial sarcoma	t(X;18)(p11;q11); t(X;18)(p11;q11); t(X;18)(p11;q11)	*SS18::SSX1; SS18::SSX2; SS18::SSX4*
Tenosynovial giant cell tumor/pigmented villonodular synovitis (TGCT/PVNS)	CSF1 rearrangements	Multiple[12-14]

a Emerging entity; NGS testing is preferred.

[6] Yamamoto H, Yoshida A, Taguchi K, et al. ALK, ROS1 and NTRK3 gene rearrangements in inflammatory myofibroblastic tumours. Histopathology 2016;69:72-83.
[8] Taylor MS, Chougule A, MacLeay AR, et al. Morphologic overlap between inflammatory myofibroblastic tumor and IgG4-related disease: Lessons from next-generation sequencing. Am J Surg Pathol 2019;43:314-324.
[9] Lopez-Nunez O, John I, Panasiti RN, et al. Infantile inflammatory myofibroblastic tumors: clinicopathological and molecular characterization of 12 cases. Mod Pathol 2020;33:576-590.
[10] Lovly CM, Gupta A, Lipson D, et al. Inflammatory myofibroblastic tumors harbor multiple potentially actionable kinase fusions. Cancer Discov 2014;4:889-895.
[11] Davis JL, Al-Ibraheemi A, Rudzinski ER, Surrey LF. Mesenchymal neoplasms with NTRK and other kinase gene alterations. Histopathology 2022;80:4-18.
[12] Ho J, Peters T, Dickson BC, et al. Detection of CSF1 rearrangements deleting the 3' UTR in tenosynovial giant cell tumors. Genes Chromosomes Cancer 2020;59:96-105.
[13] West RB, Rubin BP, Miller MA, et al. A landscape effect in tenosynovial giant-cell tumor from activation of CSF1 expression by a translocation in a minority of tumor cells. Proc Natl Acad Sci 2006;103:690-695.
[14] Cupp JS, Miller MA, Montgomery KD, et al. Translocation and expression of CSF1 in pigmented villonodular synovitis, tenosynovial giant cell tumor, rheumatoid arthritis and other reactive synovitides. Am J Surg Pathol 2007;31:970-976.

Note: All recommendations are category 2A unless otherwise indicated.

Version 3.2026, 03/12/26 © 2026 National Comprehensive Cancer Network® (NCCN®), All rights reserved. NCCN Guidelines® and this illustration may not be reproduced in any form without the express written permission of NCCN.

PLEASE NOTE that use of this NCCN Content is governed by the End-User License Agreement, and you MAY NOT distribute this Content or use it with any artificial intelligence model or tool.
Printed by Ling Lu on 6/26/2026 6:10:47 AM. Copyright © 2026 National Comprehensive Cancer Network, Inc. All Rights Reserved.

PRINCIPLES OF SURGERY[1]

The multidisciplinary surgical team should include expertise in the management of sarcomas at specific anatomic sites as well as reconstruction.

Biopsy

- A pretreatment pathologic diagnosis, including histologic subtype and grade, is almost always necessary for the optimal treatment of a soft tissue sarcoma (surgical resection margin planning, a discussion of neoadjuvant chemotherapy, and/or radiation).
- Prior to amputation or limb-sparing surgery, Physical Medicine and Rehabilitation (PM&R) physician consultation should be offered to provide education about functional outcomes of the planned surgery, set adjuvant goals, and establish care for longitudinal follow-up.
- Percutaneous core needle biopsy is preferred as it is associated with a low risk for biopsy-related complications. The biopsy tract should avoid potential tumor contamination of uninvolved anatomic compartments and, ideally, be in line with any future surgical resection incision. In certain situations, especially deep-seated tumors, image-guided needle biopsy can improve diagnostic accuracy (avoid necrotic nondiagnostic areas or surrounding normal tissues, and thoroughly sample heterogenous tumors). Open incisional biopsy can be considered if percutaneous core needle biopsies do not lead to an adequate diagnosis.
  - In certain situations, MRI and FDG-PET/CT imaging obtained prior to biopsy may allow for targeting of enhancing/metabolically active components and less necrotic regions of the tumor.
  - Needle gauge and imaging modality should be determined based on lesion location and ability to adequately visualize target and non-target anatomy.
- There is no clarity in the literature on when sentinel node staging in STS should be done. A multidisciplinary discussion should occur regarding its role in certain histologies with a possibility of occult lymph node metastasis (eg, clear cell, angiosarcoma, epithelioid, alveolar rhabdomyosarcoma) during treatment planning.[2]

Oncologically Appropriate Surgery

- The ideal surgical procedure necessary to resect the tumor with oncologically appropriate margins would have pathologically negative resection margins. However, planned close margins or even microscopically positive margins may be appropriate to preserve critical structures (eg, major vessels, nerves, bones, joints), especially in the setting of multimodality therapy.
- For extremity sarcomas, the goal of surgery should be functional limb preservation, if possible, within the realm of an appropriate oncologic resection (“limb sparing surgery”).
- Radical excision/entire anatomic compartment resection is not routinely necessary.
- Prior to considering amputation, patients should be evaluated by a surgeon with expertise in the treatment of soft tissue sarcomas.
- Consideration for amputation to treat an extremity sarcoma should be made for patient preference or if gross total resection of the tumor is expected to render the limb nonfunctional.

Previous Unplanned Excision

- For patients who present with a previous unplanned surgical excision of an extremity, body wall, or head/neck sarcoma, staging imaging of the primary tumor site will help to determine the optimal management for local control.
- For gross residual tumor, follow EXTSARC-1.

References on SARC-D 4 of 4

Note: All recommendations are category 2A unless otherwise indicated.

Version 3.2026, 03/12/26 © 2026 National Comprehensive Cancer Network® (NCCN®), All rights reserved. NCCN Guidelines® and this illustration may not be reproduced in any form without the express written permission of NCCN.

PLEASE NOTE that use of this NCCN Content is governed by the End-User License Agreement, and you MAY NOT distribute this Content or use it with any artificial intelligence model or tool.
Printed by Ling Lu on 6/26/2026 6:10:47 AM. Copyright © 2026 National Comprehensive Cancer Network, Inc. All Rights Reserved.

PRINCIPLES OF SURGERY[1]

Previous Unplanned Excision (continued)
- For no gross residual tumor, but nononcologic close or microscopically positive margins, management of the primary tumor site will be the same as for "Failure to Obtain Oncologically Appropriate Margins" below.
  - For sarcomas at high risk for metastatic disease (stage III), systemic therapy should also be considered as per EXTSARC-3.
- Following unplanned excision, data suggest some increased risk of local recurrence thus supporting a combined local control approach with re-resection and RT, preferably preoperative.
- For retroperitoneal/intra-abdominal sarcomas, unplanned spillage of microscopic tumor into the free intra-abdominal cavity is associated with an increased risk for future sarcomatosis. See R1 and R2 management algorithms in RETSARC-3.

Surgical Technique
- Ideally, any prior surgical or biopsy site potentially contaminated with microscopic tumor should be excised en bloc with the definitive surgical resection specimen if technically possible with acceptable morbidity.
  - En bloc resection of a prior core needle biopsy tract in the setting of either preoperative or planned postoperative RT is less critical for local control.
- Dissection should be through grossly normal tissue planes uncontaminated by tumor.
- If the tumor is close to or displaces major vessels or nerves, these do not need to be resected if the adventitia or perineurium is removed and the underlying neurovascular structures are not involved with gross tumor.
- Surgical clips may be placed to mark the periphery of the surgical field and other relevant structures to help guide potential future RT.
- If closed suction drainage is used, the drains should exit the skin close to the edge of the surgical incision (in case re-resection or radiation is indicated).
- Clinical surgical margins at the time of resection should be documented by the surgeon.
- For certain histologies that are highly infiltrative, such as myxofibrosarcoma and DFSP, staged resections (with temporary wound coverage) to obtain negative pathologic margins prior to definitive closure/reconstruction can reduce the risk for local recurrence.[3,4,5]

Failure to Obtain Oncologically Appropriate Margins (Extremity, Truncal, Head/Neck)
- If soft tissue surgical resection margins other than bone, nerve, or major blood vessels are unexpectedly positive on final pathology (or following an unplanned excision), then surgical re-resection to obtain negative margins should strongly be considered if technically possible with minimal adverse impact on functionality.
- If there is a close/microscopically positive soft tissue margin that cannot be re-resected, then adjuvant RT should be considered based upon the risk for as well as the potential morbidity of a future local recurrence.
  - For patients with ALT/WDLPS, observation is recommended for focally positive margins if re-resection, in the event of recurrence, would not be unduly morbid. RT is reserved for selected patients with recurrent or deeply infiltrative primary lesions with a risk of local recurrence, depending on the tumor location and patient's age.
  - On a case-by-case basis, close observation is also a management option for some other Stage IA sarcoma histologies.
- Re-resection for either a planned or unplanned excision with close/microscopically positive margins on critical structures (bone, nerve, or major blood vessels) is usually not technically possible without significant morbidity. Therefore, strong considerations should be given to adjuvant RT (unless preoperative RT was already administered).

Failure to Obtain Oncologically Appropriate Margins (Retroperitoneal/Intra-abdominal)
- Given the close proximity of retroperitoneal sarcomas to critical structures, close or microscopically positive margins are not uncommon. However, re-resection and/or adjuvant RT are not typically considered in this situation (RETSARC-3).

References on SARC-D 4 of 4

Note: All recommendations are category 2A unless otherwise indicated.

Version 3.2026, 03/12/26 © 2026 National Comprehensive Cancer Network® (NCCN®), All rights reserved. NCCN Guidelines® and this illustration may not be reproduced in any form without the express written permission of NCCN.

PLEASE NOTE that use of this NCCN Content is governed by the End-User License Agreement, and you MAY NOT distribute this Content or use it with any artificial intelligence model or tool.
Printed by Ling Lu on 6/26/2026 6:10:47 AM. Copyright © 2026 National Comprehensive Cancer Network, Inc. All Rights Reserved.

PRINCIPLES OF SURGERY[1]

Prehabilitation/Rehabilitation

- Surgery for extremity soft tissue sarcomas can often result in physical disability, especially following amputation. Resection of truncal and intra-abdominal/retroperitoneal sarcomas can also adversely impact major organ systems (including cardiopulmonary function), nutrition, and general performance status. Therefore, when significant postoperative dysfunction is anticipated, strong consideration should be given to both outpatient prehabilitation and rehabilitation to optimize functional outcomes and the patient's quality of life.

Prehabilitation

- All patients should undergo a thorough preoperative assessment of medical comorbidities, physical endurance/frailty, nutritional status, and the specifics of the postoperative home environment/psychological support.

- Prior to amputation or major limb-sparing surgery, a formal PM&R consultation should be offered to provide education regarding the expected functional outcomes following the planned surgery, set up postoperative therapy goals, demonstrate postoperative exercises, and establish care for longitudinal follow-up.

- Multimodality prehabilitation (exercise training, nutritional supplementation, and anxiety-coping techniques) is associated with greater improvements in functional capacity and a lower risk for postoperative complications following major abdominal surgery.[6] Therefore, this should be strongly considered to optimize patients with comorbidities undergoing retroperitoneal/intra-abdominal sarcoma resection.

- Although there might not be adequate time for extensive prehabilitation if surgery is being performed immediately, most soft tissue sarcoma patients receiving neoadjuvant chemotherapy and/or preoperative radiation will have several months before surgery to undergo a formal prehabilitation assessment/regimen.

Rehabilitation

- In the immediate postoperative period, all patients should undergo a physical functionality and home environment evaluation (typically by a physical therapist) to ensure that they can be safely discharged home. If further inpatient rehabilitation is needed, a PM&R physician and occupational therapist should also evaluate the patient.

- Close communication between the orthopedic/surgical oncologist and the rehabilitation team is essential, including postoperative physical restrictions, anticipated concerns, and a coordinated review of the rehabilitation plan. This is especially true for more complex limb-sparing surgeries (eg, oncologic proximal humerus replacement, proximal tibia replacement, internal hemipelvectomy) that require adequate scar tissue formation for functional joint recovery.

References on SARC-D 4 of 4

Note: All recommendations are category 2A unless otherwise indicated.

Version 3.2026, 03/12/26 © 2026 National Comprehensive Cancer Network® (NCCN®), All rights reserved. NCCN Guidelines® and this illustration may not be reproduced in any form without the express written permission of NCCN.

PLEASE NOTE that use of this NCCN Content is governed by the End-User License Agreement, and you MAY NOT distribute this Content or use it with any artificial intelligence model or tool.
Printed by Ling Lu on 6/26/2026 6:10:47 AM. Copyright © 2026 National Comprehensive Cancer Network, Inc. All Rights Reserved.

PRINCIPLES OF SURGERY[1]

Rehabilitation (continued)

- The rehabilitation plan should consider oncology treatment-related side effects and comorbidities that could potentially impact recovery such as lymphedema, systemic therapy-induced neuropathy and fatigue, radiation fibrosis, and impaired bone healing.

- When possible, a more complex rehabilitation plan should be overseen by a PM&R physician, who can prescribe medications, order and interpret diagnostic tests, and oversee/coordinate therapies.

- Pain management should be integrated into the rehabilitation plan as early as possible, especially for neuropathic pain or phantom limb sensation/pain following amputation. Interventions can include mirror therapy, motor imagery, massage, oral and topical analgesics, coping strategies, and patient education.

- The rehabilitation plan should also address any psychological concerns (eg, distress associated with the surgery/decreased physical ability, body image issues) and include referrals to appropriate mental health professionals, if appropriate. All patients should be offered participation in peer support groups.

[1] American College of Surgeons Cancer Research Program. Operative Standards for Cancer Surgery: Volume 3: Sarcoma, Adrenal, Neuroendocrine, Peritoneal Malignancies, Urothelial, Hepatobiliary. Philadelphia, PA: Wolters Kluwer Health; 2022.
[2] Keung EZ, Krause KJ, Maxwell J, et al. Sentinel lymph node biopsy for extremity and truncal soft tissue sarcomas: A systematic review of the literature. Ann Surg Oncol 2023;30:958-967.
[3] Fourman MS, Ramsey DC, Newman ET, et al. Assessing the safety and utility of wound VAC temporization of the sarcoma or benign aggressive tumor bed until final margins are achieved. Ann Surg Oncol 2022;29:2290-2298.
[4] Berner JE, Crowley TP, Teelucksingh S, et al. The importance of clear margins in myxofibrosarcoma: Improving local control by means of staged resection and reconstruction. Eur J Surg Oncol 2021;47:2627-2632.
[5] Fourman MS, Ramsey C, Kleiner J, et al. Temporizing wound VAC dressing until final negative margins are achieved reduces myxofibrosarcoma local recurrence. Ann Surg Oncol 2021;28:9171-9176.
[6] Soh NH, Yau CRZ, Low XZ, et al. Prehabilitation outcomes in surgical oncology patients undergoing major abdominal surgery: A meta-analysis of randomized control trials. Ann Surg Oncol 2025;32:1236-1247.

Note: All recommendations are category 2A unless otherwise indicated.

Version 3.2026, 03/12/26 © 2026 National Comprehensive Cancer Network® (NCCN®), All rights reserved. NCCN Guidelines® and this illustration may not be reproduced in any form without the express written permission of NCCN.

PLEASE NOTE that use of this NCCN Content is governed by the End-User License Agreement, and you MAY NOT distribute this Content or use it with any artificial intelligence model or tool.
Printed by Ling Lu on 6/26/2026 6:10:47 AM. Copyright © 2026 National Comprehensive Cancer Network, Inc. All Rights Reserved.

PRINCIPLES OF RADIATION THERAPY[a]

Radiation Therapy Guidelines for Soft Tissue Sarcoma of Extremity/Body Wall/Head and Neck[1,2]

Neoadjuvant RT

- The Panel has expressed a general preference for preoperative over postoperative radiotherapy.[3]
- Potential benefits of preoperative radiation include lower total radiation dose, shorter treatment time, smaller field sizes, potential for reduced late toxicities (ie, fibrosis, edema, joint stiffness), and potential for tumor downstaging. Potential disadvantages include increased frequency of early wound healing complications, particularly for lower extremity tumors.[4,5]
- A preoperative dose of 50 to 50.4 Gy external beam RT (EBRT) (1.8–2 Gy per fraction) is recommended.[6-9]
- Radiation should be delivered using the most appropriate technique that will cover the target volume while maintaining dose constraints to normal tissues (which may include bone, lymphatics, and soft tissue). These techniques may include IMRT (preferred), or electron beam therapy, 3D conformal radiation therapy, or (in challenging anatomic locations) proton beam therapy. These treatments should be delivered with daily image guidance to ensure adequate targeting of the tumor and sparing of adjacent normal tissue.[10-12]
- If an R1 or R2 resection is anticipated, placement of clips in areas at high risk for recurrence is encouraged.
- A dose reduction to 36 Gy for myxoid liposarcoma can be considered.[13]
- Conventionally fractionated RT remains the standard of care. A moderately hypofractionated preoperative regimen has demonstrated acceptable early local control, but long-term local control and toxicity data are not yet available. A hypofractionated regimen may be appropriate for select patients who might otherwise be unable to receive a standard course of preoperative radiotherapy.[14-17]

[a] These guidelines are intended to treat the adult population. For adolescent and young adult patients, see NCCN Guidelines for Adolescent and Young Adult (AYA) Oncology.

References on SARC-E 5 of 6

Note: All recommendations are category 2A unless otherwise indicated.

Version 3.2026, 03/12/26 © 2026 National Comprehensive Cancer Network® (NCCN®), All rights reserved. NCCN Guidelines® and this illustration may not be reproduced in any form without the express written permission of NCCN.

PLEASE NOTE that use of this NCCN Content is governed by the End-User License Agreement, and you MAY NOT distribute this Content or use it with any artificial intelligence model or tool.
Printed by Ling Lu on 6/26/2026 6:10:47 AM. Copyright © 2026 National Comprehensive Cancer Network, Inc. All Rights Reserved.

PRINCIPLES OF RADIATION THERAPY[a]

Radiation Therapy Guidelines for Soft Tissue Sarcoma of Extremity/Body Wall/Head and Neck[1,2]

Adjuvant RT

- Potential benefits of postoperative radiotherapy include ability to review final surgical pathology including margin status and lower rate of wound healing complications (especially in the lower extremity). Potential disadvantages include larger field sizes, higher radiation doses, and potential for increased risk of late toxicities (ie, fibrosis, edema, joint stiffness).[4,5]
- For positive margins after preoperative radiation and surgery, consider observation or RT boost in select situations.
  - There are data to suggest that some patients with positive margins following neoadjuvant RT such as those with low-grade WDLPS and a focally, "planned" positive margin on an anatomically fixed critical structure may have acceptable local control without a boost.[18]
  - There are data to suggest that delivery of a boost for positive margins does not improve local control. Since delivery of an adjuvant RT boost does not clearly add benefit, the decision should be individualized and the potential toxicities should be carefully considered.[19,20]
  - If adjuvant boost radiation for a positive margin is felt to be appropriate, an additional 14 to 20 Gy can be considered with fractionated EBRT or brachytherapy.[21]
- Postoperative dose guidelines (total doses should always be determined by normal tissue tolerance):
  - EBRT (50–50.4 Gy; 1.8–2.0 Gy per fraction) to larger volume followed by a 10- to 16-Gy boost to reduced volume encompassing the tumor bed (final dose of 60 Gy for R0 and 66 Gy for R1 resection margins)
  - Brachytherapy ± EBRT
    - ◊ Positive margins: Low dose-rate (16–20 Gy) or high dose-rate equivalent brachytherapy (14–16 Gy) + 50 Gy EBRT
    - ◊ Negative margins: Low dose-rate (45 Gy) or high dose-rate equivalent brachytherapy (36 Gy in 3.6 Gy BID over 10 fractions in 5 days)

Definitive RT for Unresectable Disease[22]

- Long-term local control from radiation alone may be inferior to multimodality therapy, but this is a reasonable option for nonsurgical candidates.
- Doses are based on the clinical scenario, histology, and anatomic location prioritizing nearby critical structures.
- Doses to the initial volume should be 50 Gy with a boost of at least 63 Gy; however, higher doses of 70 to 80 Gy can be considered, based on tolerance of normal structures.
- Alternative hypofractionated regimens may be considered.[23-25]

Radiation Therapy Guidelines for Desmoid Tumors

- Definitive RT is an appropriate treatment option primarily for patients with non-mesenteric desmoid tumors. Treatment is often reserved for patients who cannot tolerate or progress through systemic therapy and where surgery would be too morbid or would result in positive margins.
  - The recommended dose of definitive RT is 56 Gy in 28 fractions.[26]
- Treat similarly to high-grade soft tissue sarcoma, keeping in mind the infiltrative nature of desmoid tumors.[27-29]
- Although no prospective data exists, there appears to be a benefit to definitive and postoperative radiation in doses ≥50 to 56 Gy, administered in standard 1.8 to 2 Gy/fraction postoperatively.[30-32]

[a] These guidelines are intended to treat the adult population. For adolescent and young adult patients, see NCCN Guidelines for Adolescent and Young Adult (AYA) Oncology.

References on SARC-E 5 of 6

Note: All recommendations are category 2A unless otherwise indicated.

Version 3.2026, 03/12/26 © 2026 National Comprehensive Cancer Network® (NCCN®), All rights reserved. NCCN Guidelines® and this illustration may not be reproduced in any form without the express written permission of NCCN.

PLEASE NOTE that use of this NCCN Content is governed by the End-User License Agreement, and you MAY NOT distribute this Content or use it with any artificial intelligence model or tool.
Printed by Ling Lu on 6/26/2026 6:10:47 AM. Copyright © 2026 National Comprehensive Cancer Network, Inc. All Rights Reserved.

PRINCIPLES OF RADIATION THERAPY[a]

Radiation Therapy Guidelines for Retroperitoneal/Intra-Abdominal Sarcoma

- When EBRT is used, treatment planning with IMRT, image-guided RT (IGRT), and/or proton beam therapy should be used to improve the therapeutic ratio.[10,11]

Neoadjuvant RT[30-32]

- Neoadjuvant RT for retroperitoneal/intra-abdominal sarcomas can be considered in selected patients at high risk for local recurrence.
- If neoadjuvant RT is deemed to be appropriate for a patient, the following dose guidelines are recommended:
  - 50 to 50.4 Gy EBRT (1.8–2.0 Gy per fraction)
  - Consider IORT boost for known or suspected positive margins at the time of surgery
    - 10–12.5 Gy for microscopically positive disease
    - 15 Gy for gross disease
  - In experienced centers only: 45 to 50 Gy in 25 to 28 fractions to entire clinical target volume (CTV) with dose-painted simultaneous integrated boost (SIB) to total dose of 57.5 Gy in 25 fractions to the high-risk retroperitoneal margin jointly defined by the surgeon and radiation oncologist (no boost after surgery)[33]

Adjuvant RT[34-36]

- Adjuvant RT following surgery is discouraged for retroperitoneal/intra-abdominal sarcoma. If RT is not given prior to surgical resection, consider follow-up with possible neoadjuvant RT at time of localized recurrence. See SARC-D.

Radiation Therapy Guidelines for Borderline/Malignant Phyllodes Tumor

- Data supports postoperative radiation in certain scenarios. General sarcoma dose guidelines are often utilized with 50–60 Gy administered in standard 1.8–2 Gy/fraction postoperatively.[37,38]
- The timing of preoperative versus postoperative radiation needs to be determined in tandem with the surgeon and multidisciplinary team. Factors that may inform this decision include tumor size, proximity to skin and chest wall, the planned extent of surgery, and reconstructive considerations.
- There are no data supporting the use of hypofractionated radiation regimens in phyllodes tumors therefore conventionally fractionated whole breast/post-mastectomy radiation is recommended, consistent with the dosing used for soft tissue sarcomas.

[a] These guidelines are intended to treat the adult population. For adolescent and young adult patients, see NCCN Guidelines for Adolescent and Young Adult (AYA) Oncology.

References on SARC-E 5 of 6

Note: All recommendations are category 2A unless otherwise indicated.

Version 3.2026, 03/12/26 © 2026 National Comprehensive Cancer Network® (NCCN®), All rights reserved. NCCN Guidelines® and this illustration may not be reproduced in any form without the express written permission of NCCN.

PLEASE NOTE that use of this NCCN Content is governed by the End-User License Agreement, and you MAY NOT distribute this Content or use it with any artificial intelligence model or tool.
Printed by Ling Lu on 6/26/2026 6:10:47 AM. Copyright © 2026 National Comprehensive Cancer Network, Inc. All Rights Reserved.

PRINCIPLES OF RADIATION THERAPY[a]

General Treatment Guidelines for Stereotactic Body Radiotherapy (SBRT)[39-45]

- SBRT delivers ablative doses of radiation to tumors using specialized patient immobilization, treatment planning, and image guidance to ensure a high degree of precision and facilitate protection of adjacent normal tissues.
- SBRT is commonly used to treat metastatic sarcomas involving the lungs, liver, bone, lymph nodes, and other anatomic sites, but could also be used for select primary tumors.
- Dose and fractionation should be determined by an experienced radiation oncologist based on normal tissue constraints.

- Patient selection:
  - Multidisciplinary discussion can help identify patients that may benefit from SBRT.
  - Patients with oligometastatic disease.
  - Patients with oligoprogressive disease with other sites of disease stable or controlled by systemic therapy.
  - Patients who require treatment to a tumor within a previously irradiated field.

Palliative RT

- Palliative radiation can improve symptoms from unresectable or metastatic disease. Radiation dose and fractionation should be determined based on normal tissue constraints, performance status, patient prognosis, and prior treatment history. Patients with limited volume metastatic disease and an excellent performance status may benefit from dose escalation through IMRT or SBRT. Patients who have previously received irradiation to the treatment site may benefit from IMRT or SBRT to improve the safety of reirradiation.

[a] These guidelines are intended to treat the adult population. For adolescent and young adult patients, see NCCN Guidelines for Adolescent and Young Adult (AYA) Oncology.

References on SARC-E 5 of 6

Note: All recommendations are category 2A unless otherwise indicated.

Version 3.2026, 03/12/26 © 2026 National Comprehensive Cancer Network® (NCCN®), All rights reserved. NCCN Guidelines® and this illustration may not be reproduced in any form without the express written permission of NCCN.

PLEASE NOTE that use of this NCCN Content is governed by the End-User License Agreement, and you MAY NOT distribute this Content or use it with any artificial intelligence model or tool.
Printed by Ling Lu on 6/26/2026 6:10:47 AM. Copyright © 2026 National Comprehensive Cancer Network, Inc. All Rights Reserved.

PRINCIPLES OF RADIATION THERAPY – REFERENCES

[1] Haas RL, Delaney TF, O'Sullivan B, et al. Radiotherapy for management of extremity soft tissue sarcomas: why, when, and where? Int J Radiat Oncol Biol Phys 2012;84:572-580.
[2] Salerno KE, Alektiar KM, Baldini EH, et al. Radiation therapy for treatment of soft tissue sarcoma in adults: Executive summary of an ASTRO clinical practice guideline. Pract Radiat Oncol 2021;11:339-351.
[3] O'Sullivan B, Davis AM, Turcotte R, et al. Preoperative versus postoperative radiotherapy in soft-tissue sarcoma of the limbs: a randomised trial. Lancet 2002;359:2235-2241.
[4] Davis AM, O'Sullivan B, Turcotte R, et al. Late radiation morbidity following randomization to preoperative versus postoperative radiotherapy in extremity soft tissue sarcoma. Radiother Oncol 2005;75:48-53.
[5] Nielsen OS, Cummings B, O'Sullivan B, et al. Preoperative and postoperative irradiation of soft tissue sarcomas: effect of radiation field size. Int J Radiat Oncol Biol Phys 1991;21:1595-1599.
[6] Li XA, Chen X, Zhang Q, et al. Margin reduction from image guided radiation therapy for soft tissue sarcoma: Secondary analysis of Radiation Therapy Oncology Group 0630 results. Pract Radiat Oncol 2016;6:e135-140.
[7] Wang D, Zhang Q, Eisenberg BL, et al. Significant reduction of late toxicities in patients with extremity sarcoma treated with image-guided radiation therapy to a reduced target volume: Results of Radiation Therapy Oncology Group RTOG-0630 Trial. J Clin Oncol 2015;33:2231-2238.
[8] Bahig H, Roberge D, Bosch W, et al. Agreement among RTOG sarcoma radiation oncologists in contouring suspicious peritumoral edema for neoadjuvant radiation therapy of soft tissue sarcoma of the extremity. Int J Radiat Oncol Biol Phys 2013;86:298-303.
[9] Wang D, Bosch W, Roberge D, et al. RTOG sarcoma radiation oncologists reach consensus on gross tumor volume and clinical target volume on computed tomographic images for neoadjuvant radiotherapy of primary soft tissue sarcoma of extremity in Radiation Therapy Oncology Group studies. Int J Radiat Oncol Biol Phys 2011;81:e525-e528.
[10] Salerno KE, Alektiar KM, Baldini EH, et al. Radiation Therapy for Treatment of Soft Tissue Sarcoma in Adults: Executive Summary of an ASTRO Clinical Practice Guideline. Pract Radiat Oncol 2021;11:339-351.
[11] Alektiar KM, Brennan MF, Healey JH, Singer S. Impact of intensity-modulated radiation therapy on local control in primary soft-tissue sarcoma of the extremity. J Clin Oncol 2008;26:3440-3444.
[12] Kraybill WG, Harris J, Spiro IJ, et al. Phase II study of neoadjuvant chemotherapy and radiation therapy in the management of high-risk, high-grade, soft tissue sarcomas of the extremities and body wall: Radiation Therapy Oncology Group Trial 9514. J Clin Oncol 2006;24:619-625.
[13] Lansu J, Bovèe J, Braam P, et al. Dose reduction of preoperative radiotherapy in myxoid liposarcoma: A nonrandomized controlled trial. JAMA Oncol 2021;7:e205865.
[14] Guadagnolo BA, Bassett RL, Mitra D, et al. Hypofractionated, 3-week, preoperative radiotherapy for patients with soft tissue sarcomas (HYPORT-STS): a single-centre, open-label, single-arm, phase 2 trial. Lancet Oncol 2022;23:1547-1557.
[15] Bedi M,Singh R, Charlson JA, et al. Is 5 the New 25? Long-Term Oncologic Outcomes From a Phase II, Prospective, 5-Fraction Preoperative Radiation Therapy Trial in Patients With Localized Soft Tissue Sarcoma. Adv Radiat Oncol 2022;7:100850.
[16] Kalbasi A, Kamrava M, Chu Fang-I, et al. A Phase II Trial of 5-Day Neoadjuvant Radiotherapy for Patients with High-Risk Primary Soft Tissue Sarcoma. Clin Cancer Res 2020;26:1829-1836.
[17] Bishop AJ, Mitra D, Farooqi A, et al. Moderately hypofractionated, preoperative radiotherapy in patients with soft tissue sarcomas (HYPORT-STS): Updated local control, late toxicities, and patient-reported outcomes. Cancer 2025;131:e35542.
[18] Gerrand CH, Wunder JS, Kandel RA, et al. Classification of positive margins after resection of soft-tissue sarcoma of the limb predicts the risk of local recurrence. J Bone Joint Surg Br 2001;83:1149-1155.
[19] Yami AA, Griffin AM, Ferguson PC, et al. Positive surgical margins in soft tissue sarcoma treated with preoperative radiation: is a postoperative boost necessary? Int J Radiat Oncol Biol Phys 2010;77:1191-1107.
[20] Pan E, Goldberg SI, Chen YL, et al. Role of post-operative radiation boost for soft tissue sarcomas with positive margins following pre-operative radiation and surgery. J Surg Oncol 2014;110:817-822.
[21] Delaney TF, Kepka L, Goldberg SI, et al. RT therapy for control of soft tissue sarcomas resected with positive margins. Int J Radiat Oncol Biol Phys 2007;67:1460-1469.
[22] Kepka L, Delaney TF, Suit HD, et al. Results of radiation therapy for unresected soft-tissue sarcomas. Int J Radiat Oncol Biol Phys 2005;63:852-859.
[23] Boyce-Fappiano D, Damron EP, Farooqi A, et al. Hypofractionated radiation therapy for unresectable or metastatic sarcoma lesions. Adv Radiat Oncol 2022;7:100913.

Note: All recommendations are category 2A unless otherwise indicated.

Continued

Version 3.2026, 03/12/26 © 2026 National Comprehensive Cancer Network® (NCCN®), All rights reserved. NCCN Guidelines® and this illustration may not be reproduced in any form without the express written permission of NCCN.

PLEASE NOTE that use of this NCCN Content is governed by the End-User License Agreement, and you MAY NOT distribute this Content or use it with any artificial intelligence model or tool.
Printed by Ling Lu on 6/26/2026 6:10:47 AM. Copyright © 2026 National Comprehensive Cancer Network, Inc. All Rights Reserved.

PRINCIPLES OF RADIATION THERAPY – REFERENCES

[24] Bryant JM, Mills MN, Yang GQ, et al. Novel definitive hypofractionated accelerated radiation dose-painting (HARD) for unresected soft tissue sarcomas. Adv Radiat Oncol 2024;9:101447.
[25] Bryant JM, Mills MN, Liveringhouse C, et al. Hypofractionated accelerated radiation dose-painting (HARD) improves outcomes in unresected soft-tissue sarcoma. Radiother Oncol 2025;202:110644.
[26] Keus RB, Nout RA, Blay J-Y, et al. Results of a phase II pilot study of moderate dose radiotherapy for inoperable desmoid-Type fibromatosis-an EORTC STBSG and ROG study (EORTC 62991-22998). Ann Oncol 2013;24:2672-2676.
[27] Baumert BG, Spahr MO, Von Hochstetter A, et al. The impact of radiotherapy in the treatment of desmoid tumours. An international survey of 110 patients. A study of the Rare Cancer Network. Radiat Oncol 2007;2:12.
[28] Nuyttens JJ, Rust PF, Thomas CR, Turrisi AT III. Surgery versus radiation therapy for patients with aggressive fibromatosis or desmoid tumors: A comparative review of 22 articles. Cancer 2000;88:517-523.
[29] Bishop AJ, Landry JP, Roland CL, et al. Certain risk factors for patients with desmoid tumors warrant reconsideration of local therapy strategies. Cancer 2020;126:3265-3273.
[30] Aidid F, Aichouni N, Afilal I, et al. Retroperitoneal desmoid tumor in a patient with familial adenomatous polyposis: A case report. Radiol Case Rep 2022;17:2901-2914.
[31] Micke O, Seegenschmiedt MH, German Cooperative Group on Radiotherapy for Benign Diseases. Radiation therapy for aggressive fibromatosis (desmoid tumors): results of a national Patterns of Care Study. Int J Radiat Oncol Biol Phys 2005;61:882-891.
[32] Guadagnolo BA, Zagars GK, Ballo MT. Long-term outcomes for desmoid tumors treated with radiation therapy. Int J Radiat Oncol Biol Phys 2008;71:441-447.
[33] Baldini EH, Wang D, Haas RL, et al. Treatment guidelines for neoadjuvant radiation therapy for retroperitoneal sarcoma: Preliminary consensus of an international expert panel. Int J Radiat Oncol Biol Phys 2015;92:602-612.
[34] Baldini EH, Bosch W, Kane JM, et al. Retroperitoneal sarcoma (RPS) high risk gross tumor volume boost (HR GTV boost) contour delineation agreement among NRG sarcoma radiation and surgical oncologists. Ann Surg Oncol 2015;22:2846-2852.
[35] Bonvalot S, Gronchi A, Le Péchoux C, et al. Preoperative radiotherapy plus surgery versus surgery alone for patients with primary retroperitoneal sarcoma (EORTC-62092: STRASS): a multicentre, open-label, randomised, phase 3 trial. Lancet Oncol 2020;21:1366-1377.
[36] Tzeng CW, Fiveash JB, Popple RA, et al. Preoperative radiation therapy with selective dose escalation to the margin at risk for retroperitoneal sarcoma. Cancer 2006;107:371-379.
[37] Trans-Atlantic RPS Working Group. Management of primary retroperitoneal sarcoma (RPS) in the adult: a consensus approach from the Trans-Atlantic RPS Working Group. Ann Surg Oncol 2015;22:256-263.
[38] Musat E, Kantor G, Caron J, et al. Comparison of intensity-modulated adjuvant radiotherapy with conventional adjuvant radiotherapy for retroperitoneal sarcoma. Cancer Radiother 2004;8:255-261.
[39] Swanson EL, Indelicato DJ, Louis D, et al. Comparison of three-dimensional (3D) conformal proton radiotherapy (RT), 3D conformal photon RT, and intensity-modulated RT for retroperitoneal and intra-abdominal sarcomas. Int J Radiat Oncol Biol Phys 2012;83:1549-1557.
[40] Dhakal S, Corbin KS, Milano MT, et al. Stereotactic body radiotherapy for pulmonary metastases from soft-tissue sarcomas: excellent local lesion control and improved patient survival. Int J Radiat Oncol Biol Phys 2012;82:940-945.
[41] Navarria P, Ascolese AM, Cozzi L, et al. Stereotactic body radiation therapy for lung metastases from soft tissue sarcoma. Eur J Cancer 2015;51:668-674.
[42] Baumann BC, De Amorim Bernstein K, DeLaney TF, et al. Multi-institutional analysis of stereotactic body radiotherapy for sarcoma pulmonary metastases: high rates of local control with favorable toxicity. J Surg Oncol 2020;122:877-883.
[43] Asha W, Koro S, Mayo Z, et al. Stereotactic body radiation therapy for sarcoma pulmonary metastases. Am J Clin Oncol 2023;46:263-270.
[44] Gutkin PM, von Eyben R, Chin A, et al. Local control outcomes using stereotactic body radiation therapy or surgical resection for metastatic sarcoma. Int J Radiat Oncol Biol Phys 2022;114:771-779.
[45] Navarria P, Baldaccini D, Clerici E, et al. Stereotactic body radiation therapy or lung metastases from sarcoma in oligometastatic patients: A phase 2 study. Int J Radiat Oncol Biol Phys 2022;114:762-770.

Note: All recommendations are category 2A unless otherwise indicated.

Version 3.2026, 03/12/26 © 2026 National Comprehensive Cancer Network® (NCCN®), All rights reserved. NCCN Guidelines® and this illustration may not be reproduced in any form without the express written permission of NCCN.

PLEASE NOTE that use of this NCCN Content is governed by the End-User License Agreement, and you MAY NOT distribute this Content or use it with any artificial intelligence model or tool.
Printed by Ling Lu on 6/26/2026 6:10:47 AM. Copyright © 2026 National Comprehensive Cancer Network, Inc. All Rights Reserved.

PRINCIPLES OF INTERVENTIONAL ONCOLOGY

Catheter-Directed Therapies

- In appropriately selected patients with liver-dominant metastatic disease, surgical resection of hepatic metastases can be associated with long-term survival benefit.[1-3]
- Catheter-directed therapies allow minimally invasive treatment of liver disease in select patients, including those unable to tolerate surgical resection or lesions not amenable to surgery.
- Intra-arterial therapies produce cell death by inducing ischemia and/or locally delivering cytotoxic agents or radiation to hepatic tumors. Specific intra-arterial therapies include transarterial (bland) embolization (TAE), transarterial chemoembolization (TACE), and transarterial radioembolization (TARE). These therapies have been shown to be safe treatments for progressive disease with high rates of local disease control and overall survival.[4-6]
  - Transarterial Embolization (TAE)
    - TAE involves delivery of embolic agents within hepatic arteries supplying liver tumors with the goal of vessel stasis.
    - TAE could be considered for treatment of hepatic sarcoma metastases in patients with unresectable liver disease or those who have disease that progresses despite conventional therapy.[4]
  - Transarterial Chemoembolization (TACE)
    - TACE consists of conventional TACE (cTACE) and drug-eluting bead (DEB)-TACE. cTACE involves targeted infusion of chemotherapeutic medications in addition to embolic agents and lipiodol into the tumoral blood supply while DEB-TACE drug delivery is through embolic beads loaded with chemotherapeutic medication.
    - In surgically unresectable liver disease, TACE has been shown to increase overall survival in patients with sarcoma who have liver metastases.[7,8]
  - Transarterial Radioembolization (TARE)
    - TARE utilizes beta particle emitting microspheres by yttrium-90 decay to induce tumoricidal effects through local brachytherapy. TARE can be performed with either glass or resin microspheres.[9,10]
- Patient selection
  - Multidisciplinary discussion should be performed to identify candidates who may benefit from catheter-directed therapies.
  - Unresectable liver-dominant metastases or patients with medical comorbidities prohibiting surgical resection can be considered for catheter-directed therapies.
  - Patients whose disease progresses despite conventional therapies could also be considered for transarterial treatments.
  - Absolute contraindications to catheter-directed therapies are few, but include:
    - Uncorrectable coagulopathy
    - Active infection in the planned treatment area
    - Decompensated liver failure (relative based on treatment approach)

References on SARC-F 3 of 3

Note: All recommendations are category 2A unless otherwise indicated.

Version 3.2026, 03/12/26 © 2026 National Comprehensive Cancer Network® (NCCN®), All rights reserved. NCCN Guidelines® and this illustration may not be reproduced in any form without the express written permission of NCCN.

PLEASE NOTE that use of this NCCN Content is governed by the End-User License Agreement, and you MAY NOT distribute this Content or use it with any artificial intelligence model or tool.
Printed by Ling Lu on 6/26/2026 6:10:47 AM. Copyright © 2026 National Comprehensive Cancer Network, Inc. All Rights Reserved.

PRINCIPLES OF INTERVENTIONAL ONCOLOGY

Ablation

- Tumor ablation involves application of FDA-approved thermal or non-thermal device therapies to a tumor to achieve cell death.
- Tumor ablation techniques include thermal and non-thermal approaches.
  - Ablation modality should be based on tumor size, location, and adjacent critical structures to optimize treatment effect while limiting potential adverse events. Choice of treatment modality may also take into account institutional experience and technique availability.
- Patient selection
  - Multidisciplinary discussion should be considered to identify candidates who may benefit from ablative therapies.
  - Unresectable metastases or patients with medical comorbidities prohibiting surgical resection could be considered for image-guided ablation.
  - Patients whose disease progresses despite conventional therapies could also be considered for ablation.
  - Ablation after stability on chemotherapy can serve as a well-tolerated maintenance therapy with significant progression-free survival and systemic therapy-free intervals.[11]
  - Ablation for patients with painful musculoskeletal metastases could be considered for pain palliation and may be combined with cement augmentation, osteosynthesis, or internal fixation in the event of osseous destruction or increased fracture risk, especially in weight-bearing bones.
  - Absolute contraindications to image-guided ablation are few, but include:
    - ◊ Uncorrectable coagulopathy
    - ◊ Active infection in the planned treatment area
    - ◊ Inability to displace or protect adjacent critical structures (relative based on risk-benefit discussion)
- Specific considerations in ablation of metastatic disease
  - Liver metastases
    - ◊ Local ablative treatment is associated with improved overall survival in patients with oligometastatic disease.[12]
  - Lung metastases
    - ◊ Percutaneous thermal ablation may be considered in the treatment of sarcoma lung metastases given high rates of local tumor control.[13,14]
  - Musculoskeletal metastases
    - ◊ Percutaneous ablation is an effective option for local tumor control in the setting of oligometastatic disease and pain palliation of metastatic sarcomas within the musculoskeletal system.[15]
- Specific considerations of ablation in desmoid tumors
  - Ablation can provide good local control and favorable clinical response rates when used as active therapy for progressive, morbid, or symptomatic desmoids.[16-26]
  - Cryoablation is the most commonly utilized ablation modality.[27]
  - DEB chemoembolization in desmoid tumors can be utilized for selective extra-abdominal desmoid tumors if cryoablation is not technically possible.[28]

Note: All recommendations are category 2A unless otherwise indicated.

References on SARC-F 3 of 3

Version 3.2026, 03/12/26 © 2026 National Comprehensive Cancer Network® (NCCN®), All rights reserved. NCCN Guidelines® and this illustration may not be reproduced in any form without the express written permission of NCCN.

PLEASE NOTE that use of this NCCN Content is governed by the End-User License Agreement, and you MAY NOT distribute this Content or use it with any artificial intelligence model or tool.
Printed by Ling Lu on 6/26/2026 6:10:47 AM. Copyright © 2026 National Comprehensive Cancer Network, Inc. All Rights Reserved.

PRINCIPLES OF INTERVENTIONAL ONCOLOGY
REFERENCES

[1] Tirotta F, Hodson J, Parente A, et al. Liver resection for sarcoma metastases: A systematic review and experience from two European centres. Eur J Surg Oncol 2020;46:1807-1813.
[2] Brudvik KW, Patel SH, Roland CL, et al. Survival after resection of gastrointestinal stromal tumor and sarcoma liver metastases in 146 patients. J Gastrointest Surg 2015;19:1476-1483.
[3] Goumard C, Marcal LP, Wang W-L, et al. Long-term survival according to histology and radiologic response to preoperative chemotherapy in 126 patients undergoing resection of non-GIST sarcoma liver metastases. Ann Surg Oncol 2018;25:107-116.
[4] Maluccio MA, Covey AM, Schubert J, et al. Treatment of metastatic sarcoma to the liver with bland embolization. Cancer 2006;107:1617-1623.
[5] Chapiro J, Duran R, Lin M, et al. Transarterial chemoembolization in soft-tissue sarcoma metastases to the liver – The use of imaging biomarkers as predictors of patient survival. Eur J Radiol 2015;84:424-430.
[6] Miller MD, Sze DY, Padia SA, et al. Response and overall survival for yttrium-90 radioembolization of hepatic sarcoma: A multicenter retrospective study. J Vasc Interv Radiol 2018;29:867-873.
[7] Rajan DK, Soulen MC, Clark TWI, et al. Sarcomas metastatic to the liver: Response and survival after cisplatin, doxorubicin, mitomycin-C, ethiodol, and polyvinyl alcohol chemoembolization. J Vasc Interv Radiol 2001;12:187-193.
[8] Krzyston H, Morse B, Deperalta D, et al. Liver-directed treatments of liver-dominant metastatic leiomyosarcoma. Diagnostic Interv Radiol 2020;26:449-455.
[9] Zhou W, Du L, Brown DB, et al. Outcomes analysis of yttrium-90 radioembolization for tumors other than metastatic colorectal cancer from the Radiation-Emitting SIR-Spheres in Nonresectable (RESiN) Registry. J Vasc Interv Radiol 2024;35:1591-1600.
[10] Testa S, Bui NQ, Wang DS, et al. Efficacy and safety of trans-arterial yttrium-90 radioembolization in patients with unresectable liver-dominant metastatic or primary hepatic soft tissue sarcomas. Cancers 2022;14:324.
[11] Falk AT, Moureau-Zabotto L, Ouali M, et al. Effect on survival of local ablative treatment of metastases from sarcomas: a study of the French sarcoma group. Clin Oncol (R Coll Radiol) 2015;27:48-55.
[12] Koelblinger C, Strauss S, Gillams A. Outcome after radiofrequency ablation of sarcoma lung metastases. Cardiovasc Intervent Radiol 2014;37:147-153.
[13] Bourgouin PP, Wrobel MM, Mercaldo ND, et al. Comparison of percutaneous image-guided microwave ablation and cryoablation for sarcoma lung metastases: A 10-year experience. AJR Am J Roentgenol 2022;218:494-504.
[14] Vaswani D, Wallace AN, Eiswirth PS, et al. Radiographic local tumor control and pain palliation of sarcoma metastases within the musculoskeletal system with percutaneous thermal ablation. Cardiovasc Intervent Radiol 2018;41:1223-1232.
[15] Hirbe AC, Jennings J, Saad N, et al. A phase II study of tumor ablation in patients with metastatic sarcoma stable on chemotherapy. Oncologist 2018;23:760-e76.
[16] Redifer Tremblay K, Lea WB, Neilson JC, et al. Percutaneous cryoablation for the treatment of extra-abdominal desmoid tumors. J Surg Oncol 2019;120:366-375.
[17] Schmitz JJ, Schmit GD, Atwell TD, et al. Percutaneous cryoablation of extraabdominal desmoid tumors: a 10-year experience. AJR Am J Roentgenol 2016;207:190-195.
[18] Havez M, Lippa N, Al-Ammari S, et al. Percutaneous image-guided cryoablation in inoperable extra-abdominal desmoid tumors: a study of tolerability and efficacy. Cardiovasc Intervent Radiol 2014;37:1500-1506.
[19] Ilaslan H, Schils J, Joyce M, et al. Radiofrequency ablation: another treatment option for local control of desmoid tumors. Skeletal Radiol 2010;39:169-173.
[20] Cobianchi L, Ravetta V, Viera FT, et al. The challenge of extraabdominal desmoid tumour management in patients with Gardner's syndrome: radiofrequency ablation, a promising option. World J Surg Oncol 2014;12:361.
[21] Ghanouni P, Dobrotwir A, Bazzocchi A, et al. Magnetic resonance-guided focused ultrasound treatment of extra-abdominal desmoid tumors: a retrospective multicenter study. Eur Radiol 2017;27:732-740.
[22] Najafi A, Fuchs B, Binkert CA. Mid-term results of MR-guided high-intensity focused ultrasound treatment for relapsing superficial desmoids. Int J Hyperthermia 2019;36:538-542.
[23] Griffin MO, Kulkarni NM, O'Connor SD, et al. Magnetic resonance-guided focused ultrasound: a brief review with emphasis on the treatment of extra-abdominal desmoid tumors. Ultrasound Q 2019;35:346-354.
[24] Bucknor MD, Rieke V. MRgFUS for desmoid tumors within the thigh: early clinical experiences. J Ther Ultrasound 2017;5:4.
[25] Avedian RS, Bitton R, Gold G, et al. Is MR-guided high-intensity focused ultrasound a feasible treatment modality for desmoid tumors? Clin Orthop Relat Res 2016;474:697-704.
[26] Kurtz JE, Buy X, Deschamps F, et al. CRYODESMO-O1: A prospective, open phase II study of cryoablation in desmoid tumour patients progressing after medical treatment. Eur J Cancer 2021;143:78-87.
[27] Campbell WA, Makary MS. Advances in image-guided ablation therapies for solid tumors. Cancers 2024;16:2560.
[28] Kim D, Keohan ML, Gounder MM, et al. Transarterial chemoembolization with doxorubicin eluting beads for extra-abdominal desmoid tumors: initial experience. Cardiovasc Intervent Radiol 2022;45:1141-1151.

Note: All recommendations are category 2A unless otherwise indicated.

Version 3.2026, 03/12/26 © 2026 National Comprehensive Cancer Network® (NCCN®), All rights reserved. NCCN Guidelines® and this illustration may not be reproduced in any form without the express written permission of NCCN.

PLEASE NOTE that use of this NCCN Content is governed by the End-User License Agreement, and you MAY NOT distribute this Content or use it with any artificial intelligence model or tool.
Printed by Ling Lu on 6/26/2026 6:10:47 AM. Copyright © 2026 National Comprehensive Cancer Network, Inc. All Rights Reserved.

SYSTEMIC THERAPY AGENTS AND REGIMENS WITH ACTIVITY IN SOFT TISSUE SARCOMA SUBTYPES[a,b,c,d] AND AGGRESSIVE SOFT TISSUE NEOPLASMS

Regimens Appropriate for General Soft Tissue Sarcoma[e,f]; see other sections for additional histology-specific recommendations[g]

	Preferred	Other Recommended	Useful in Certain Circumstances
Neoadjuvant/ Adjuvant Therapy	• AIM (Doxorubicin/Ifosfamide/Mesna)[1-4] • Epirubicin/Ifosfamide/Mesna[5] • Neoadjuvant Pembrolizumab[u] with RT[6] followed by adjuvant Pembrolizumab for UPS related sarcomas (limb girdle/extremity UPS/ myxofibrosarcoma [MFS]/dedifferentiated liposarcoma [ddLPS]/pleomorphic liposarcoma)	• AD (Doxorubicin/ Dacarbazine)[1,2,11,12] for leiomyosarcoma (LMS), or if Ifosfamide is not considered appropriate • Doxorubicin[1,2,7,8]	• Ifosfamide/Mesna[5,8,28] • Trabectedin (for myxoid liposarcoma)[32] • Docetaxel/Gemcitabine[25,26] (category 2B)
First-Line Therapy Advanced/ Metastatic	• Anthracycline-based regimens: ▸ Doxorubicin[1,2,7,8] ▸ Epirubicin[9] ▸ Liposomal Doxorubicin[10] ▸ AD (Doxorubicin/Dacarbazine)[1,2,11-13] ▸ AIM (Doxorubicin/Ifosfamide/Mesna)[1-4,7] ▸ Epirubicin/Ifosfamide/Mesna[5] • Doxorubicin/Trabectedin (for LMS)[14,15] • *NTRK* gene fusion-positive sarcomas only (regardless of soft tissue sarcoma subtype) ▸ Larotrectinib[h,16] ▸ Entrectinib[i,17] ▸ Repotrectinib[18]	• Gemcitabine • Docetaxel/Gemcitabine[25,26] (category 2B)	• Pazopanib[k,18] (patients ineligible for IV systemic therapy or patients who are not candidates for anthracycline-based regimens) • Selpercatinib (for *RET* gene fusion-positive tumors[33]) (regardless of soft tissue sarcoma subtype) • Dacarbazine/Gemcitabine[27] (category 2B)
Subsequent Lines of Therapy for Advanced/ Metastatic Disease	• Anthracycline-based regimens as listed above for first-line therapy may be considered with attention to lifetime total Doxorubicin dose • Pazopanib[j,k,19] • Eribulin[j,20,21] (category 1 recommendation for liposarcoma, category 2A for other subtypes) • Trabectedin[j,22-24] (category 1 recommendation for liposarcoma and LMS, category 2A for other subtypes) • Docetaxel/Gemcitabine[25,26] • *NTRK* gene fusion-positive sarcomas only (regardless of soft tissue sarcoma subtype) ▸ Repotrectinib[18] (if not previously given)	• Dacarbazine[22,27] • Ifosfamide/Mesna[5,8,28] • Temozolomide[j,29] • Vinorelbine[j,30] • Regorafenib[k,31] • Gemcitabine • Dacarbazine/Gemcitabine[27]	• Gemcitabine/Vinorelbine[34] (category 2B) • Gemcitabine/Pazopanib[35] (category 2B) • Pembrolizumab[u,36,37] or nivolumab ± ipilimumab[l,38-41] ▸ For MFS, UPS,[f] ddLPS, cutaneous angiosarcoma, and undifferentiated sarcomas OR ▸ For TMB-H (≥10 mutations/megabase [mut/Mb])[m] regardless of soft tissue sarcoma subtype • Pembrolizumab[u,42] ▸ For microsatellite instability-high (MSI-H) or dMMR tumors[n] (regardless of soft tissue sarcoma subtype) • Cabozantinib[43] (category 2B) • Afamitresgene Autoleucel[44] ▸ HLA-A*02:01P, HLA-A*02:02P, HLA-A*02:03P or HLA-A*02:06P positive and whose tumor expresses the MAGE-A4 antigen (synovial sarcomas only)

Note: All recommendations are category 2A unless otherwise indicated.

Footnotes and References (SARC-G, 8 of 14)

Version 3.2026, 03/12/26 © 2026 National Comprehensive Cancer Network® (NCCN®), All rights reserved. NCCN Guidelines® and this illustration may not be reproduced in any form without the express written permission of NCCN.

PLEASE NOTE that use of this NCCN Content is governed by the End-User License Agreement, and you MAY NOT distribute this Content or use it with any artificial intelligence model or tool.
Printed by Ling Lu on 6/26/2026 6:10:47 AM. Copyright © 2026 National Comprehensive Cancer Network, Inc. All Rights Reserved.

SYSTEMIC THERAPY AGENTS AND REGIMENS WITH ACTIVITY IN SOFT TISSUE SARCOMA SUBTYPES[d] AND AGGRESSIVE SOFT TISSUE NEOPLASMS

Desmoid Tumors (Aggressive Fibromatosis)[o]	Non-Pleomorphic Rhabdomyosarcoma
Preferred • Nirogacestat (category 1)[45] • Sorafenib (category 1)[46] • Methotrexate/Vinorelbine[47] • Methotrexate/Vinblastine[48] • Imatinib[49,50] • Liposomal Doxorubicin[51] • Dacarbazine ± Doxorubicin[52-54] • Pazopanib[55] **Useful in certain circumstances** • Sulindac[56] or other nonsteroidal anti-inflammatory drugs (NSAIDs), including Celecoxib (for pain)	**Preferred** • VAC (Vincristine/Dactinomycin/Cyclophosphamide/Mesna)[p,57] • VAI-Europe (Vincristine/Dactinomycin/Ifosfamide/Mesna)[p,58] **Other recommended** • VDC-IE (Vincristine/Doxorubicin/Cyclophosphamide/Mesna alternating with Ifosfamide/Mesna/Etoposide)[59] • Cyclophosphamide/Mesna/Doxorubicin/Vincristine[60] • Doxorubicin/Ifosfamide/Mesna/Vincristine[61] • Cyclophosphamide/Topotecan[62] • Doxorubicin/Ifosfamide/Mesna[63] • Etoposide/Ifosfamide/Mesna[64] • Irinotecan/Vincristine[65,66] • Carboplatin/Etoposide[67] • Oral Low-Dose Cyclophosphamide/Vinorelbine[j,68] • Irinotecan/Temozolomide/Vincristine[69] • Irinotecan[65,66,70] • Topotecan[71] • Vinorelbine[j,72] • Cyclophosphamide/Temsirolimus/Vinorelbine[73] **Useful in certain circumstances** • Maintenance chemotherapy (Cyclophosphamide/Vinorelbine) for patients with intermediate-risk RMS with complete response (CR) following treatment with VAC or VAI regimen (Please note: Children's Oncology Group [COG] has an active prospective ongoing study, but this is considered a reasonable standard of care)[68]

Footnotes and References
(SARC-G, 8 of 14)

Note: All recommendations are category 2A unless otherwise indicated.

Version 3.2026, 03/12/26 © 2026 National Comprehensive Cancer Network® (NCCN®), All rights reserved. NCCN Guidelines® and this illustration may not be reproduced in any form without the express written permission of NCCN.

PLEASE NOTE that use of this NCCN Content is governed by the End-User License Agreement, and you MAY NOT distribute this Content or use it with any artificial intelligence model or tool.
Printed by Ling Lu on 6/26/2026 6:10:47 AM. Copyright © 2026 National Comprehensive Cancer Network, Inc. All Rights Reserved.

SYSTEMIC THERAPY AGENTS AND REGIMENS WITH ACTIVITY IN SOFT TISSUE SARCOMA SUBTYPES[d] AND AGGRESSIVE SOFT TISSUE NEOPLASMS

Alveolar Soft Part Sarcoma (ASPS)	Angiosarcoma
Preferred • Atezolizumab[q,r,74,75] • Pazopanib[76] • Pembrolizumab[u,77] • Axitinib + Pembrolizumab[u,78] • Sunitinib[79,80] **Useful in certain circumstances** • Cabozantinib[43]	**Preferred** • Paclitaxel[l,81,82] • Anthracycline- or gemcitabine-based regimens recommended for soft tissue sarcoma subtypes with non-specific histologies (SARC-G, 1 of 14) **Other recommended** • Docetaxel[83] • Vinorelbine[j] • Pazopanib **Useful in certain circumstances** • Pembrolizumab[u,36] (for cutaneous angiosarcoma) • Regorafenib[84] • Sorafenib[85] • Sunitinib[86] • Bevacizumab[s,87] • Ipilimumab + Nivolumab[l,38]

Footnotes and References
(SARC-G, 8 of 14)

Note: All recommendations are category 2A unless otherwise indicated.

Version 3.2026, 03/12/26 © 2026 National Comprehensive Cancer Network® (NCCN®), All rights reserved. NCCN Guidelines® and this illustration may not be reproduced in any form without the express written permission of NCCN.

PLEASE NOTE that use of this NCCN Content is governed by the End-User License Agreement, and you MAY NOT distribute this Content or use it with any artificial intelligence model or tool.
Printed by Ling Lu on 6/26/2026 6:10:47 AM. Copyright © 2026 National Comprehensive Cancer Network, Inc. All Rights Reserved.

SYSTEMIC THERAPY AGENTS AND REGIMENS WITH ACTIVITY IN SOFT TISSUE SARCOMA SUBTYPES[d] AND AGGRESSIVE SOFT TISSUE NEOPLASMS

Dermatofibrosarcoma Protuberans (DFSP) with Fibrosarcomatous Transformation	Epithelioid Sarcoma	Extraskeletal Osteosarcoma	Dedifferentiated Chordoma
Preferred • Imatinib[88] **Other recommended** • Anthracycline-based regimens: ▸ Doxorubicin[1,2,7,8] ▸ Epirubicin[9] ▸ Liposomal Doxorubicin[10] ▸ AIM (Doxorubicin/Ifosfamide/Mesna)[1-4,7] ▸ Epirubicin/Ifosfamide/Mesna[5] • Gemcitabine-based regimens: ▸ Gemcitabine ▸ Docetaxel/Gemcitabine[25,26] • Pazopanib[19] (patients ineligible for IV systemic therapy or patients who are not candidates for anthracycline-based regimens) **Useful in certain circumstances** • Dacarbazine/Gemcitabine[27] (category 2B) • Gemcitabine/Vinorelbine[34] (category 2B)	**Preferred** • Anthracycline-based regimens for general soft tissue sarcoma (SARC-G, 1 of 14)	**Preferred** • Ifosfamide/Mesna or platinum-based therapy (Cisplatin/Doxorubicin)[89]	• Anthracycline-based regimens for general soft tissue sarcoma (SARC-G, 1 of 14) • Gemcitabine-based regimens recommended for general soft tissue sarcoma (SARC-G, 1 of 14)

Footnotes and References
(SARC-G, 8 of 14)

Note: All recommendations are category 2A unless otherwise indicated.

Version 3.2026, 03/12/26 © 2026 National Comprehensive Cancer Network® (NCCN®), All rights reserved. NCCN Guidelines® and this illustration may not be reproduced in any form without the express written permission of NCCN.

PLEASE NOTE that use of this NCCN Content is governed by the End-User License Agreement, and you MAY NOT distribute this Content or use it with any artificial intelligence model or tool.
Printed by Ling Lu on 6/26/2026 6:10:47 AM. Copyright © 2026 National Comprehensive Cancer Network, Inc. All Rights Reserved.

SYSTEMIC THERAPY AGENTS AND REGIMENS WITH ACTIVITY IN SOFT TISSUE SARCOMA SUBTYPES AND AGGRESSIVE SOFT TISSUE NEOPLASMS

Inflammatory Myofibroblastic Tumor (IMT) with Anaplastic Lymphoma Kinase (ALK) Translocation	Malignant Perivascular Epithelioid Cell Tumor (PEComa) (for locally advanced unresectable or metastatic disease)	Recurrent Angiomyolipoma, Lymphangioleiomyomatosis
Preferred • Alectinib[90] • Brigatinib[91,92] • Ceritinib[93] • Crizotinib[94] • Lorlatinib[95]	**Preferred** • Albumin-bound Sirolimus[96,97] **Other recommended** • Sirolimus[98-101] • Everolimus[102] • Temsirolimus[103,104]	**Preferred** • Sirolimus[98-101] • Everolimus[102] • Temsirolimus[103,104]

See References (SARC-G, 8 of 14)

Note: All recommendations are category 2A unless otherwise indicated.

Version 3.2026, 03/12/26 © 2026 National Comprehensive Cancer Network® (NCCN®), All rights reserved. NCCN Guidelines® and this illustration may not be reproduced in any form without the express written permission of NCCN.

PLEASE NOTE that use of this NCCN Content is governed by the End-User License Agreement, and you MAY NOT distribute this Content or use it with any artificial intelligence model or tool.
Printed by Ling Lu on 6/26/2026 6:10:47 AM. Copyright © 2026 National Comprehensive Cancer Network, Inc. All Rights Reserved.

SYSTEMIC THERAPY AGENTS AND REGIMENS WITH ACTIVITY IN SOFT TISSUE SARCOMA SUBTYPES[d] AND AGGRESSIVE SOFT TISSUE NEOPLASMS

Solitary Fibrous Tumor	Tenosynovial Giant Cell Tumor/Pigmented Villonodular Synovitis	Dedifferentiated Liposarcoma with or without Concurrent Well-Differentiated Liposarcoma
Preferred • Temozolomide + Bevacizumab[s,105] • Sunitinib[86,106] • Sorafenib[107] • Pazopanib[108] **Other recommended** • Anthracycline-based regimens: ▸ Doxorubicin[1,2,7,8] ▸ Epirubicin[9] ▸ Liposomal Doxorubicin[10] ▸ AD (Doxorubicin/Dacarbazine)[1,2,11-13] ▸ AIM (Doxorubicin/Ifosfamide/Mesna)[1-4,7] ▸ Epirubicin/Ifosfamide/Mesna[5] • Gemcitabine-based regimens: ▸ Gemcitabine ▸ Docetaxel/Gemcitabine[25,26] • Trabectedin[j] **Useful in certain circumstances** • Dacarbazine/Gemcitabine[27] (category 2B) • Gemcitabine/Vinorelbine[34] (category 2B)	**Preferred** • Pexidartinib[109] (category 1) • Vimseltinib[110] (category 1) **Useful in certain circumstances** • Imatinib[111] • Nilotinib[112]	**Preferred** • Anthracycline-based regimens for general soft tissue sarcoma (SARC-G, 1 of 14) • Gemcitabine-based regimens recommended for general soft tissue sarcoma (SARC-G, 1 of 14) **Other recommended** • Eribulin[20,21] • Dacarbazine[22] • Trabectedin[22-24] **Useful in certain circumstances** • Palbociclib[t,113] • Abemaciclib[114]

Footnotes and References
(SARC-G, 8 of 14)

Note: All recommendations are category 2A unless otherwise indicated.

Version 3.2026, 03/12/26 © 2026 National Comprehensive Cancer Network® (NCCN®), All rights reserved. NCCN Guidelines® and this illustration may not be reproduced in any form without the express written permission of NCCN.

PLEASE NOTE that use of this NCCN Content is governed by the End-User License Agreement, and you MAY NOT distribute this Content or use it with any artificial intelligence model or tool.
Printed by Ling Lu on 6/26/2026 6:10:47 AM. Copyright © 2026 National Comprehensive Cancer Network, Inc. All Rights Reserved.

SYSTEMIC THERAPY AGENTS AND REGIMENS WITH ACTIVITY IN SOFT TISSUE SARCOMA SUBTYPES[d] AND AGGRESSIVE SOFT TISSUE NEOPLASMS

Extraskeletal Myxoid Chondrosarcoma	Epithelioid Hemangioendothelioma (EHE)
Preferred • Pazopanib[115] **Other recommended** • Sunitinib[116] • Cabozantinib[43]	**Other recommended** • Soft tissue sarcoma regimens[117] (SARC-G 1 of 14) • Pazopanib[117] • Sirolimus[118] • Paclitaxel[117] (category 2B) • Trametinib[119]

Footnotes and References
(SARC-G, 8 of 14)

Note: All recommendations are category 2A unless otherwise indicated.

Version 3.2026, 03/12/26 © 2026 National Comprehensive Cancer Network® (NCCN®), All rights reserved. NCCN Guidelines® and this illustration may not be reproduced in any form without the express written permission of NCCN.

PLEASE NOTE that use of this NCCN Content is governed by the End-User License Agreement, and you MAY NOT distribute this Content or use it with any artificial intelligence model or tool.
Printed by Ling Lu on 6/26/2026 6:10:47 AM. Copyright © 2026 National Comprehensive Cancer Network, Inc. All Rights Reserved.

SYSTEMIC THERAPY AGENTS AND REGIMENS WITH ACTIVITY IN SOFT TISSUE SARCOMA SUBTYPES AND AGGRESSIVE SOFT TISSUE NEOPLASMS
FOOTNOTES

[a] Prior to the initiation of therapy, all patients should be evaluated and treated by a multidisciplinary team with expertise and experience in sarcoma.
[b] For uterine sarcomas, see the NCCN Guidelines for Uterine Neoplasms.
[c] Excluding histologies that are insensitive to cytotoxic chemotherapy including, but not limited to, ASPS, extremity ALT/WDLPS, extraskeletal myxoid chondrosarcoma, and clear cell sarcomas. These regimens are appropriate for many STS histologies, but refer to other sections for additional histology-specific recommendations.
[d] Dexrazoxane may be added as a cardioprotectant for the prevention of cardiotoxicity in patients planning to receive high-dose anthracyclines (eg, doxorubicin >250 mg/m^2). Armenian SH, et al. J Clin Oncol 2017;35:893-911.
[e] Anthracycline-based regimens are preferred in the neoadjuvant and adjuvant settings.
[f] Regimens appropriate for pleomorphic RMS.
[g] See SARC-G 6 of 14 for additional treatment options for dedifferentiated liposarcoma with or without concurrent well-differentiated liposarcoma.
[h] Not intended for neoadjuvant or adjuvant therapy of nonmetastatic disease. Not recommended for angiosarcoma or pleomorphic RMS.
[i] Not intended for adjuvant therapy of nonmetastatic disease.
[j] Recommended only for palliative therapy.
[k] For non-adipocytic sarcoma.
[l] Nivolumab and hyaluronidase-nvhy is not approved for concurrent use with IV ipilimumab; however, for nivolumab monotherapy, nivolumab and hyaluronidase-nvhy subcutaneous injection may be substituted for IV nivolumab. Nivolumab and hyaluronidase-nvhy has different dosing and administration instructions compared to IV nivolumab.
[m] For the treatment of patients with unresectable or metastatic tumor mutational burden-high (TMB-H) (≥10 mut/Mb) tumors, as determined by an FDA-approved test, that have progressed following prior treatment and who have no satisfactory alternative treatment options.
[n] For the treatment of unresectable or metastatic MSI-H or mismatch repair deficient (dMMR) solid tumors as determined by an FDA-approved test, that have progressed following prior treatment and who have no satisfactory alternative treatment options.
[o] Optimal duration of TKI therapy has not been established. Discontinuation of TKI therapy can be considered (with careful monitoring) in patients with stable disease.
[p] For patients with intermediate-risk disease, consider maintenance therapy with vinorelbine and cyclophosphamide for 6 months.
[q] FDA approved for the treatment of adult and pediatric patients ≥2 years of age with unresectable or metastatic ASPS.
[r] Atezolizumab and hyaluronidase-tqjs subcutaneous injection may be substituted for IV atezolizumab. Atezolizumab and hyaluronidase-tqjs has different dosing and administration instructions compared to IV atezolizumab.
[s] An FDA-approved biosimilar is an appropriate substitute for bevacizumab.
[t] Single-agent therapy for the treatment of unresectable WDLPS or dedifferentiated liposarcoma.
[u] Pembrolizumab and berahyaluronidase alfa-pmph subcutaneous injection may be substituted for IV pembrolizumab. Pembrolizumab and berahyaluronidase alfa-pmph has different dosing and administration instructions compared to IV pembrolizumab.

REFERENCES

[1] Adjuvant chemotherapy for localized resectable soft-tissue sarcoma of adults: Meta-analysis of individual data. Sarcoma Meta-analysis Collaboration. Lancet 1997;350:1647-1654.
[2] Pervaiz N, Colterjohn N, Farrokhyar F, et al. A systematic meta-analysis of randomized controlled trials of adjuvant chemotherapy for localized resectable soft-tissue sarcoma. Cancer 2008;113:573-581.
[3] Grobmyer SR, Maki RG, Demetri GD, et al. Neo-adjuvant chemotherapy for primary high-grade extremity soft tissue sarcoma. Ann Oncol 2004;15:1667-1672.

Note: All recommendations are category 2A unless otherwise indicated.

Continued

Version 3.2026, 03/12/26 © 2026 National Comprehensive Cancer Network® (NCCN®), All rights reserved. NCCN Guidelines® and this illustration may not be reproduced in any form without the express written permission of NCCN.

PLEASE NOTE that use of this NCCN Content is governed by the End-User License Agreement, and you MAY NOT distribute this Content or use it with any artificial intelligence model or tool.
Printed by Ling Lu on 6/26/2026 6:10:47 AM. Copyright © 2026 National Comprehensive Cancer Network, Inc. All Rights Reserved.

SYSTEMIC THERAPY AGENTS AND REGIMENS WITH ACTIVITY IN SOFT TISSUE SARCOMA SUBTYPES AND AGGRESSIVE SOFT TISSUE NEOPLASMS
REFERENCES

[4] Edmonson J, Ryan L, Blum R, et al. Randomized comparison of doxorubicin alone versus ifosfamide plus doxorubicin or mitomycin, doxorubicin, and cisplatin against advanced soft tissue sarcomas. J Clin Oncol 1993;11:1269-1275.
[5] Frustaci S, Gherlinzoni F, De Paoli A, et al. Adjuvant chemotherapy for adult soft tissue sarcomas of the extremities and girdles: results of the Italian randomized cooperative trial. J Clin Oncol 2001;19:1238-1247.
[6] Mowery YM, Ballman KV, Hong AM, et al. Safety and efficacy of pembrolizumab, radiation therapy, and surgery versus radiation therapy and surgery for stage III soft tissue sarcoma of the extremity (SU2C-SARC032): an open-label, randomised clinical trial. Lancet 2024;404:2053-2064.
[7] Mack LA, Crowe PJ, Yang JL, et al. Neoadjuvant chemoradiotherapy (modified Eilber protocol) provides maximum local control and minimal morbidity in patients with soft tissue sarcoma. Ann Surg Oncol 2005;12:646-653.
[8] Judson I, Verweij J, Gelderblom H, et al. Doxorubicin alone versus intensified doxorubicin plus ifosfamide for first-line treatment of advanced or metastatic soft-tissue sarcoma: a randomised controlled phase 3 trial. Lancet Oncol 2014;15:415-423
[9] Petrioli R, Coratti A, Correale P, et al. Adjuvant epirubicin with or without Ifosfamide for adult soft-tissue sarcoma. Am J Clin Oncol 2002;25:468-473.
[10] Judson I, Radford J, Harris M, et al. Randomised phase II trial of pegylated liposomal doxorubicin versus doxorubicin in the treatment of advanced or metastatic soft tissue sarcoma: a study by the EORTC Soft Tissue and Bone Sarcoma Group. Eur J Cancer 2001;37:870-877.
[11] Zalupski M, Metch B, Balcerzak S, et al. Phase III comparison of doxorubicin and dacarbazine given by bolus versus infusion in patients with soft-tissue sarcomas: A Southwest Oncology Group Study. J Natl Cancer Inst 1991;83:926-932.
[12] Antman K, Crowley J, Balcerzak SP, et al. An intergroup phase III randomized study of doxorubicin and dacarbazine with or without ifosfamide and mesna in advanced soft tissue and bone sarcomas. J Clin Oncol 1993;11:1276-1285.
[13] D'Ambrosio L, Touati N, Blay JY, et al. Doxorubicin plus dacarbazine, doxorubicin plus ifosfamide, or doxorubicin alone as a first-line treatment for advanced leiomyosarcoma: a propensity score matching analysis from the European Organization for Research and Treatment of Cancer Soft Tissue and Bone Sarcoma Group. Cancer 2020;126:2637-2647.
[14] Pautier P, Italiano A, Piperno-Neumann S, et al. Doxorubicin alone versus doxorubicin with trabectedin followed by trabectedin alone as first-line therapy for metastatic or unresectable leiomyosarcoma (LMS-04): a randomised, multicentre, open-label phase 3 trial. Lancet Oncol 2022;23:1044-1054.
[15] Pautier P, Floquet A, Chevreau C, et al. A single-arm multicentre phase II trial of doxorubicin in combination with trabectedin in the first-line treatment for leiomyosarcoma with long-term follow-up and impact of cytoreductive surgery. ESMO 2021;6:100209.
[16] Drilon A, Laetsch TW, Kummar S, et al. Efficacy of larotrectinib in TRK fusion-positive cancers in adult and children. N Engl J Med 2018;378:731-739.
[17] Demetri GD, Paz-Ares L, Farago AF, et al. Efficacy and safety of entrectinib in patients with NTRK fusion-positive tumours: pooled analysis of STARTRK-2, STARTRK-1 and ALKA-372-001. Presented at the European Society for Medical Oncology Meeting in Munich, Germany; October 12-23, 2018. Oral Presentation.
[18] Solomon BJ, Drilon A, Lin JJ, et al. Repotrectinib in patients (pts) with NTRK fusion-positive (NTRK+) advanced solid tumors, including non-small cell lung cancer: update from the phase 1/2 TRIDENT-1 trial. Ann Oncol 2023;34:S787-S788.
[19] Grünwald V, Kardh A, Schuler M, et al. Randomized comparison of pazopanib and doxorubicin as first-line treatment in patients with metastatic soft tissue sarcoma age 60 years or older: results of a German Intergroup Study. J Clin Oncol 2020;38:3555-3564.
[20] Schöffski P, Chwala S, Maki RG, at al. Eribulin versus dacarbazine in previously treated patients with advanced liposarcoma or leiomyosarcoma: a randomised, open-label, multicentre, phase 3 trial Lancet. 2016; 387(10028):1629-1637.
[21] Schöffski P, Ray-Coquard IL, Cioffi A, et al. Activity of eribulin mesylate in patients with soft-tissue sarcoma: a phase 2 study in four independent histological subtypes. Lancet Oncol 2011;12:1045-1052.
[22] Demetri GD, von Mehren M, Jones RL, et al. Efficacy and safety of trabectedin or dacarbazine for metastatic liposarcoma or leiomyosarcoma after failure of conventional chemotherapy: results of a phase III randomized multicenter clinical trial. J Clin Oncol 2016;34:786-793.
[23] Kawai A, Araki N, Sugiura H, et al. Trabectedin monotherapy after standard chemotherapy versus best supportive care in patients with advanced, translocation-related sarcoma: a randomised, open-label, phase 2 study. Lancet Oncol 2015;16:406-416.

Continued

Note: All recommendations are category 2A unless otherwise indicated.

Version 3.2026, 03/12/26 © 2026 National Comprehensive Cancer Network® (NCCN®), All rights reserved. NCCN Guidelines® and this illustration may not be reproduced in any form without the express written permission of NCCN.

PLEASE NOTE that use of this NCCN Content is governed by the End-User License Agreement, and you MAY NOT distribute this Content or use it with any artificial intelligence model or tool.
Printed by Ling Lu on 6/26/2026 6:10:47 AM. Copyright © 2026 National Comprehensive Cancer Network, Inc. All Rights Reserved.

SYSTEMIC THERAPY AGENTS AND REGIMENS WITH ACTIVITY IN SOFT TISSUE SARCOMA SUBTYPES AND AGGRESSIVE SOFT TISSUE NEOPLASMS
REFERENCES

[24] Samuels BL, Chawla S, Patel S, et al. Clinical outcomes and safety with trabectedin therapy in patients with advanced soft tissue sarcomas following failure of prior chemotherapy: results of a worldwide expanded access program study. Ann Oncol 2013;24:1703-1709.
[25] Hensley ML, Maki R, Venkatraman E, et al. Gemcitabine and docetaxel in patients with unresectable leiomyosarcoma: results of a phase II trial. J Clin Oncol 2002;20:2824-2831.
[26] Maki RG, Wathen JK, Patel SR, et al. Randomized phase II study of gemcitabine and docetaxel compared with gemcitabine alone in patients with metastatic soft tissue sarcomas: results of sarcoma alliance for research through collaboration study 002. J Clin Oncol 2007;25:2755-2763.
[27] Garcia-Del-Muro X, Lopez-Pousa A, Maurel J, et al. Randomized phase II study comparing gemcitabine plus dacarbazine versus dacarbazine alone in patients with previously treated soft tissue sarcoma: a Spanish Group for Research on Sarcomas study. J Clin Oncol 2011;29:2528-2533.
[28] Antman KH, Elias A. Dana-Farber Cancer Institute studies in advanced sarcoma. Semin Oncol 1990;1:7-15.
[29] Talbot SM, Keohan ML, Hesdorffer M, et al. A phase II trial of temozolomide in patients with unresectable or metastatic soft tissue sarcoma. Cancer 2003;98:1942-1946.
[30] Kuttesch JF Jr, Krailo MD, Madden T, et al. Phase II evaluation of intravenous vinorelbine (navelbine) in recurrent or refractory pediatric malignancies: a Children's Oncology Group study. Pediatr Blood Cancer 2009;53:590-593.
[31] Berry V, Basson L, Bogart E, et al. REGOSARC: Regorafenib versus placebo in doxorubicin-refractory soft-tissue sarcoma-A quality-adjusted time without symptoms of progression or toxicity analysis. Cancer 2017;123:2294-2302.
[32] Gronchi A, Palmerini E, Quagliuolo V, et al. Neoadjuvant chemotherapy in high-risk soft tissue sarcomas: Final results of a Randomized Trial From Italian (ISG), Spanish (GEIS), French (FSG), and Polish (PSG) Sarcoma Groups. J Clin Oncol 2020;38:2178-2186.
[33] Subbiah V, Wolf J, Konda B, et al. Tumor-agnostic efficacy and safety of selpercatinib in patients with RET fusion-positive solid tumours other than lung or thyroid tumours (LIBRETTO-001): a phase 1/2, open-label, basket trial. Lancet Oncol 2022;23:1261-1273.
[34] Dileo P, Morgan JA, Zahrieh D, et al. Gemcitabine and vinorelbine combination chemotherapy for patients with advanced soft tissue sarcomas: results of a phase II trial. Cancer 2007;109:1863-1869.
[35] Somaiah N, Van Tine BA, Wahlquist AE, et al. A randomized, open-label, phase 2, multicenter trial of gemcitabine with pazopanib or gemcitabine with docetaxel in patients with advanced soft-tissue sarcoma. Cancer 2021;127:894-904.
[36] Burgess MA, Bolejack V, Van Tine BA, et al. Multicenter phase II study of pembrolizumab (P) in advanced soft tissue sarcoma (STS) and bone sarcomas (BS): Final results of SARC028 and biomarker analyses [abstract]. J Clin Oncol 2017;35(Suppl): Abstract 11008.
[37] Florou V, Rosenberg AE, Wieder E, et al. Angiosarcoma patients treated with immune checkpoint inhibitors: a case series of seven patients from a single institution. J Immunother Cancer 2019;7:285.
[38] Schenker M, Burotto M, Richardet M, et al. Randomized, open label, phase 2 study of nivolumab plus ipilimumab or nivolumab monotherapy in patients with advanced or metastatic solid tumors of high tumor mutational burden. J Immunother Cancer 2024;12:e008872.
[39] Wagner MJ, Othus M, Patel SP, et al. Multicenter phase II trial (SWOG S1609, cohort 51) of ipilimumab and nivolumab in metastatic or unresectable angiosarcoma: a substudy of dual anti-CTLA-4 and anti-PD-1 blockade in rare tumors (DART). J Immunother Cancer 2021;9:e002990.
[40] Li Y, Liu Y, Qu Y, et al. Case report: Two cases of soft-tissue sarcomas: High TMB as a potential predictive biomarker for anlotinib combined with toripalimab therapy. Front Immunol 2022;13:832593.
[41] Cheung LS, Chen L, Oke TF, et al. Anti-PD-1 elicits regression of undifferentiated pleomorphic sarcomas with UV-mutation signatures. J Immunother Cancer 2021;9:e002345.
[42] Maio M, Ascierto PA, Manzyuk L, et al. Pembrolizumab in microsatellite instability high or mismatch repair deficient cancers: updated analysis from the phase II KEYNOTE-158 study. Ann Oncol 2022;33:929-938.
[43] O'Sullivan Coyne G, Kummar S, Hu J, et al. Clinical activity of single-agent cabozantinib (XL184), a multi-receptor tyrosine kinase inhibitor, in patients with refractory soft-tissue sarcomas. Clin Cancer Res 2022;28:279-288.
[44] D'Angelo SP, Araujo DM, Abdul Razak AR, et al. Afamitresgene autoleucel for advanced synovial sarcoma and myxoid round cell liposarcoma (SPEARHEAD-1): an international, open-label, phase 2 trial. Lancet 2024;403:1460-1471.
[45] Gounder M, Ratan R, Alcindor T, et al. Nirogacestat, a gamma-secretase inhibitor for desmoid tumors. N Engl J Med 2023;388:898-912.

Continued

Note: All recommendations are category 2A unless otherwise indicated.

Version 3.2026, 03/12/26 © 2026 National Comprehensive Cancer Network® (NCCN®), All rights reserved. NCCN Guidelines® and this illustration may not be reproduced in any form without the express written permission of NCCN.

PLEASE NOTE that use of this NCCN Content is governed by the End-User License Agreement, and you MAY NOT distribute this Content or use it with any artificial intelligence model or tool.
Printed by Ling Lu on 6/26/2026 6:10:47 AM. Copyright © 2026 National Comprehensive Cancer Network, Inc. All Rights Reserved.

SYSTEMIC THERAPY AGENTS AND REGIMENS WITH ACTIVITY IN SOFT TISSUE SARCOMA SUBTYPES AND AGGRESSIVE SOFT TISSUE NEOPLASMS
REFERENCES

[46] Gounder MM, Mahoney MR, Van Tine BA, et al. Sorafenib for advanced and refractory desmoid tumor. N Engl J Med 2018;379:2417-2428.
[47] Weiss AJ, Horowitz S, Lackman RD. Therapy of desmoid tumors and fibromatosis using vinorelbine. Am J Clin Oncol 1999;22:193-195.
[48] Azzarelli A, Gronchi A, Bertulli R, et al. Low-dose chemotherapy with methotrexate and vinblastine for patients with advanced aggressive fibromatosis. Cancer 2001;92:1259-1264.
[49] Chugh R, Wathen JK, Patel SR, et al. Efficacy of imatinib in aggressive fibromatosis: Results of a phase II multicenter Sarcoma Alliance for Research through Collaboration (SARC) trial. Clin Cancer Res 2010;16:4884-4891.
[50] Penel N, Le Cesne A, Bui BN, et al. Imatinib for progressive and recurrent aggressive fibromatosis (desmoid tumors): an FNCLCC/French Sarcoma Group phase II trial with a long-term follow-up. Ann Oncol 2011;22:452-457.
[51] Constantinidou A, Jones RL, Scurr M, et al. Pegylated liposomal doxorubicin, an effective, well-tolerated treatment for refractory aggressive fibromatosis. Eur J Cancer 2009;45:2930-2934.
[52] Seiter K, Kemeny N. Successful treatment of a desmoid tumor with doxorubicin. Cancer 1993;71:2242-2244.
[53] Patel SR, Evans HL, Benjamin RS. Combination chemotherapy in adult desmoid tumors. Cancer 1993;72:3244-3247.
[54] de Camargo VP, Keohan ML, D'Adamo DR, et al. Clinical outcomes of systemic therapy for patients with deep fibromatosis (desmoid tumor). Cancer 2010;116:2258-2265.
[55] Toulmonde M, Pulido M, Ray-Coquard I, et al. Pazopanib or methotrexate-vinblastine combination chemotherapy in adult patients with progressive desmoid tumours (DESMOPAZ): a non-comparative, randomised, open-label, multicentre, phase 2 study. Lancet Oncol 2019;20:1263-1272.
[56] Tsukada K, Church JM, Jagelman D, et al. Noncytotoxic therapy for intra-abdominal desmoid tumor in patients with familial adenomatous polyposis. Dis Colon Rectum 1992;35:29-33.
[57] Arndt CAS, Stoner JA, Hawkins DS, et al. Vincristine, actinomycin, and cyclophosphamide compared with vincristine, actinomycin, and cyclophosphamide alternating with vincristine, topotecan, and cyclophosphamide for intermediate-risk rhabdomyosarcoma: children's oncology group study D9803. J Clin Oncol 2009;27:5182-5188.
[58] Schoot RA, Chisholm JC, Casanova M, et al. Metastatic rhabdomyosarcoma: results of the European Paediatric Soft Tissue Sarcoma Study Group MTS 2008 study and pooled analysis with the concurrent BERNIE study. J Clin Oncol 2022;40:3730-3740.
[59] Arndt CAS, Hawkins DS, Meyer WH, et al. Comparison of results of a pilot study of alternating vincristine/doxorubicin/cyclophosphamide and etoposide/ifosfamide with IRS-IV in intermediate risk rhabdomyosarcoma: a report from the Children's Oncology Group. Pediatr Blood Cancer 2008;50:33-36.
[60] Little DJ, Ballo MT, Zagars GK, et al. Adult rhabdomyosarcoma: outcome following multimodality treatment. Cancer 2002;95:377-388.
[61] Ogilvie CM, Crawford EA, Slotcavage RL, et al. Treatment of adult rhabdomyosarcoma. Am J Clin Oncol 2010;33:128-131.
[62] Saylors RL, Stine KC, Sullivan J, et al. Cyclophosphamide plus topotecan in children with recurrent or refractory solid tumors: a Pediatric Oncology Group phase II study. J Clin Oncol 2001;19:3463-3469.
[63] Sandler E, Lyden E, Ruymann F, et al. Efficacy of ifosfamide and doxorubicin given as a phase II "window" in children with newly diagnosed metastatic rhabdomyosarcoma: a report from the Intergroup Rhabdomyosarcoma Study Group. Med Pediatr Oncol 2001;37:442-448.
[64] Breitfeld PP, Lyden E, Raney RB, et al. Ifosfamide and etoposide are superior to vincristine and melphalan for pediatric metastatic rhabdomyosarcoma when administered with irradiation and combination chemotherapy: a report from the Intergroup Rhabdomyosarcoma Study Group. J Pediatr Hematol Oncol 2001;23:225-233.
[65] Pappo AS, Lyden E, Breitfeld P, et al. Two consecutive phase II window trials of irinotecan alone or in combination with vincristine for the treatment of metastatic rhabdomyosarcoma: the Children's Oncology Group. J Clin Oncol 2007;25:362-369.
[66] Mascarenhas L, Lyden ER, Breitfeld PP, et al. Randomized phase II window trial of two schedules of irinotecan with vincristine in patients with first relapse or progression of rhabdomyosarcoma: a report from the Children's Oncology Group. J Clin Oncol 2010;28:4658-4663. Erratum in J Clin Oncol 2011;4629:1394.
[67] Klingebiel T, Pertl U, Hess CF, et al. Treatment of children with relapsed soft tissue sarcoma: report of the German CESS/CWS REZ 91 trial. Med Pediatr Oncol 1998;30:269-275.

Continued

Note: All recommendations are category 2A unless otherwise indicated.

Version 3.2026, 03/12/26 © 2026 National Comprehensive Cancer Network® (NCCN®), All rights reserved. NCCN Guidelines® and this illustration may not be reproduced in any form without the express written permission of NCCN.

PLEASE NOTE that use of this NCCN Content is governed by the End-User License Agreement, and you MAY NOT distribute this Content or use it with any artificial intelligence model or tool.
Printed by Ling Lu on 6/26/2026 6:10:47 AM. Copyright © 2026 National Comprehensive Cancer Network, Inc. All Rights Reserved.

SYSTEMIC THERAPY AGENTS AND REGIMENS WITH ACTIVITY IN SOFT TISSUE SARCOMA SUBTYPES AND AGGRESSIVE SOFT TISSUE NEOPLASMS
REFERENCES

[68] Bisogno G, De Salvo GL, Bergeron C, et al. Vinorelbine and continuous low-dose cyclophosphamide as maintenance chemotherapy in patients with high-risk rhabdomyosarcoma (RMS 2005): a multicentre, open-label, randomised, phase 3 trial. Lancet Oncol 2019;20:1566-1575.70

[69] McNall-Knapp RY, Williams CN, Reeves EN, et al. Extended phase I evaluation of vincristine, irinotecan, temozolomide, and antibiotic in children with refractory solid tumors. Pediatr Blood Cancer 2010;54:909-915.

[70] Vassal G, Couanet D, Stockdale E, et al. Phase II trial of irinotecan in children with relapsed or refractory rhabdomyosarcoma: a joint study of the French Society of Pediatric Oncology and the United Kingdom Children's Cancer Study Group. J Clin Oncol 2007;25:356-361.

[71] Pappo AS, Lyden E, Breneman J, et al. Up-front window trial of topotecan in previously untreated children and adolescents with metastatic rhabdomyosarcoma: an intergroup rhabdomyosarcoma study. J Clin Oncol 2001;19:213-219.

[72] Casanova M, Ferrari A, Spreafico F, et al. Vinorelbine in previously treated advanced childhood sarcomas: evidence of activity in rhabdomyosarcoma. Cancer 2002;94:3263-3268.

[73] Mascarenhas L, Chi YY, Hingorani P, et al. Randomized phase II trial of bevacizumab or temsirolimus in combination with chemotherapy for first relapse rhabdomyosarcoma: a report from the Children's Oncology Group. J Clin Oncol 2019;37:2866-2874.

[74] Naqash AR, Coyne GH, Moore N, et al. Phase II study of atezolizumab in advanced alveolar soft part sarcoma (ASPS) [abstract]. J Clin Oncol 2021;39(Suppl): Abstract 11519.

[75] Burotto M, Zvirbule A, Mochalova A, et al. A randomised phase III, open-label, multicentre study examining the pharmacokinetics (PK), efficacy, immunogenicity, and safety of atezolizumab subcutaneous vs intravenous in previously treated locally advanced or metastatic non-small-cell lung cancer and pharmacokinetics comparison with other approved indications. Ann Oncol 2023;34:693-702.

[76] Stacchiotti S, Mir O, Le Cesne A, et al. Activity of pazopanib and trabectedin in advanced alveolar soft part sarcoma. Oncologist 2018;23:62-70.

[77] Wilky BA, Trucco MM, Subhawong TK, et al. Axitinib plus pembrolizumab in patients with advanced sarcomas including alveolar soft-part sarcoma: a single-centre, single-arm, phase 2 trial. Lancet Oncol 2019;20:837-848.

[78] Groisberg R, Hong DS, Behrang A, et al. Characteristics and outcomes of patients with advanced sarcoma enrolled in early phase immunotherapy trials. J Immunother Cancer 2017;5:100.

[79] Stacchiotti S, Negri T, Zaffaroni N, et al. Sunitinib in advanced alveolar soft part sarcoma: evidence of a direct antitumor effect. Ann Oncol 2011;22:1682-1690.

[80] Stacchiotti S, Tamborini E, Marrari A, et al. Response to sunitinib malate in advanced alveolar soft part sarcoma. Clin Cancer Res 2009;15:1096-1104.

[81] Penel N, Bui BN, Bay J-O, et al. Phase II trial of weekly paclitaxel for unresectable angiosarcoma: the ANGIOTAX Study. J Clin Oncol 2008;26:5269-5274.

[82] Schlemmer M, Reichardt P, Verweij J, et al. Paclitaxel in patients with advanced angiosarcomas of soft tissue: a retrospective study of the EORTC soft tissue and bone sarcoma group. Eur J Cancer 2008;44:2433-2436.

[83] Van Hoesel QG, Verweij J, Catimel G, et al. Phase II study with docetaxel (Taxotere) in advanced soft tissue sarcomas of the adult. EORTC Soft Tissue and Bone Sarcoma Group. Ann Oncol 1994;5:539-542.

[84] Agulnik M, Schulte B, Robinson S, et al. An open-label single-arm phase II study of regorafenib for the treatment of angiosarcoma. Eur J Cancer 2021;154:201-208.

[85] Maki RG, D'Adamo DR, Keohan ML, et al. Phase II study of sorafenib in patients with metastatic or recurrent sarcomas. J Clin Oncol 2009;27:3133-3140.

[86] George S, Merriam P, Maki RG, et al. Multicenter phase II trial of sunitinib in the treatment of nongastrointestinal stromal tumor sarcomas. J Clin Oncol 2009;27:3154-3160.

[87] Agulnik M, Yarber JL, Okuno SH, et al. An open-label, multicenter, phase II study of bevacizumab for the treatment of angiosarcoma and epithelioid hemangioendotheliomas. Ann Oncol 2013;24:257-263.

Continued

Note: All recommendations are category 2A unless otherwise indicated.

Version 3.2026, 03/12/26 © 2026 National Comprehensive Cancer Network® (NCCN®), All rights reserved. NCCN Guidelines® and this illustration may not be reproduced in any form without the express written permission of NCCN.

PLEASE NOTE that use of this NCCN Content is governed by the End-User License Agreement, and you MAY NOT distribute this Content or use it with any artificial intelligence model or tool.
Printed by Ling Lu on 6/26/2026 6:10:47 AM. Copyright © 2026 National Comprehensive Cancer Network, Inc. All Rights Reserved.

SYSTEMIC THERAPY AGENTS AND REGIMENS WITH ACTIVITY IN SOFT TISSUE SARCOMA SUBTYPES AND AGGRESSIVE SOFT TISSUE NEOPLASMS
REFERENCES

[88] Rutkowski P, Klimczak A, Lugowski I, et al. Long-term results of treatment of advanced dermatofibrosarcoma protuberans (DFSP) with imatinib mesylate - The impact of fibrosarcomatous transformation. Eur J Surg Oncol 2017;43:1134-1141.
[89] Paludo J, Fritchie K, Haddox CL, et al. Extraskeletal osteosarcoma: outcomes and the role of chemotherapy. Am J Clin Oncol 2018;41:832-837.
[90] Peters S, Camidge DR, Shaw AT, et al. Alectinib versus crizotinib in untreated ALK-positive non-small-cell lung cancer. N Engl J Med 2017;377:829-838.
[91] Camidge DR, Kim HR, Ahn MJ, et al. Brigatinib versus crizotinib in ALK-positive non-small-cell lung cancer. N Engl J Med 2018;379:2027-2039.
[92] Gettinger SN, Bazhenova LA, Langer CJ, et al. Activity and safety of brigatinib in ALK-rearranged non-small–cell lung cancer and other malignancies: a single-arm, open-label, phase 1/2 trial. Lancet Oncol 2016;17:1683-1696.
[93] Shaw AT, Kim DW, Mehra R, et al. Ceritinib in ALK-rearranged non-small-cell lung cancer. N Engl J Med 2014;370:1189-1197.
[94] Gambacorti-Passerini C, Orlov S, Zhang L, et al. Long-term effects of crizotinib in ALK-positive tumors (excluding NSCLC): A phase 1b open-label study. Am J Hematol 2018;93:607-614.
[95] Shaw AT, Bauer TM, de Marinis F, et al. First-line lorlatinib or crizotinib in advanced ALK-positive lung cancer. N Engl J Med 2020;383;2018-2029
[96] Wagner AJ, Ravi V, Riedel RF, et al. *nab*-Sirolimus for patients with malignant perivascular epithelioid cell tumors. J Clin Oncol 2021;39:3660-3670.
[97] Wagner AJ, Ravi V, Riedel RF, et al. Long-term follow-up for duration of response (DoR) after weekly nab-sirolimus for patients with advanced malignant perivascular epithelioid cell tumors (PEComa): Results from a registrational open label phase II trial, AMPECT [abstract]. J Clin Oncol 2020;38(Suppl):Abstract 11516.
[98] Bissler JJ, McCormack FX, Young LR, et al. Sirolimus for angiomyolipoma in tuberous sclerosis complex or lymphangioleiomyomatosis. N Engl J Med 2008;358:140-151.
[99] Davies DM, de Vries PJ, Johnson SR, et al. Sirolimus therapy for angiomyolipoma in tuberous sclerosis and sporadic lymphangioleiomyomatosis: a phase 2 trial. Clin Cancer Res 2011;17:4071-4081.
[100] Wagner AJ, Malinowska-Kolodziej I, Morgan JA, et al. Clinical activity of mTOR inhibition with sirolimus in malignant perivascular epithelioid cell tumors: targeting the pathogenic activation of mTORC1 in tumors. J Clin Oncol 2010;28:835-840.
[101] McCormack FX, Inoue Y, Moss J, et al. Efficacy and safety of sirolimus in lymphangioleiomyomatosis. N Engl J Med 2011;364:1595-1606.
[102] Gennatas C, Michalaki V, Kairi PV, et al. Successful treatment with the mTOR inhibitor everolimus in a patient with perivascular epithelioid cell tumor. World J Surg Oncol 2012;10:181.
[103] Benson C, Vitfell-Rasmussen J, Maruzzo M, et al. A retrospective study of patients with malignant PEComa receiving treatment with sirolimus or temsirolimus: the Royal Marsden Hospital experience. Anticancer Res 2014;34:3663-3668.
[104] Italiano A, Delcambre C, Hostein I, et al. Treatment with the mTOR inhibitor temsirolimus in patients with malignant PEComa. Ann Oncol 2010;21:1135-1137.
[105] Park MS, Patel SR, Ludwig JA, et al. Activity of temozolomide and bevacizumab in the treatment of locally advanced, recurrent, and metastatic hemangiopericytoma and malignant solitary fibrous tumor. Cancer 2011;117:4939-4947.
[106] Stacchiotti S, Negri T, Libertini M, et al. Sunitinib malate in solitary fibrous tumor (SFT). Ann Oncol 2012;23:3171-3179.
[107] Valentin T, Fournier C, Penel N, et al. Sorafenib in patients with progressive malignant solitary fibrous tumors: a subgroup analysis from a phase II study of the French Sarcoma Group (GSF/GETO). Invest New Drugs 2013;31:1626-1627.
[108] Ebata T, Shimoi T, Bun S, et al. Efficacy and safety of pazopanib for recurrent or metastatic solitary fibrous tumor. Oncology 2018;94:340-344.
[109] Tap WD, Gelderblom H, Palmerini E, et al. Pexidartinib versus placebo for advanced tenosynovial giant cell tumor (ENLIVEN): a randomized phase 3 trial. Lancet 2019;394:478-487.
[110] Gelderblom H, Bhadri V, Stacchiotti S, et al. Vimseltinib versus placebo for tenosynovial giant cell tumour (MOTION): a multicentre, randomised, double-blind, placebo-controlled, phase 3 trial. Lancet 2024;403:2709-2719.
[111] Cassier PA, Gelderblom H, Stacchiotti S, et al. Efficacy of imatinib mesylate for the treatment of locally advanced and/or metastatic tenosynovial giant cell tumor/pigmented villonodular synovitis. Cancer 2012;118:1649-1655.
[112] Gelderblom H, Cropet C, Chevreau C, et al. Nilotinib in locally advanced pigmented villonodular synovitis: a multicentre, open-label, single-arm, phase 2 trial. Lancet Oncol 2018;19:639-648.

Continued

Note: All recommendations are category 2A unless otherwise indicated.

Version 3.2026, 03/12/26 © 2026 National Comprehensive Cancer Network® (NCCN®), All rights reserved. NCCN Guidelines® and this illustration may not be reproduced in any form without the express written permission of NCCN.

PLEASE NOTE that use of this NCCN Content is governed by the End-User License Agreement, and you MAY NOT distribute this Content or use it with any artificial intelligence model or tool.
Printed by Ling Lu on 6/26/2026 6:10:47 AM. Copyright © 2026 National Comprehensive Cancer Network, Inc. All Rights Reserved.

SYSTEMIC THERAPY AGENTS AND REGIMENS WITH ACTIVITY IN SOFT TISSUE SARCOMA SUBTYPES AND AGGRESSIVE SOFT TISSUE NEOPLASMS
REFERENCES

[113] Dickson MA, Tap WD, Keohan ML, et al. Phase II trial of the CDK4 inhibitor PD0332991 in patients with advanced CDK4-amplified well differentiated or dedifferentiated liposarcoma. J Clin Oncol 2013;31:2024-2028.
[114] Gleason CE, Dickson MA, Klein Dooley ME, et al. Therapy-induced Senescence contributes to the efficacy of Abemaciclib in patients with dedifferentiated liposarcoma. Clin Cancer Res 2024;30:703-718.
[115] Stacchiotti S, Ferrari S, Redondo A, et al. Pazopanib for treatment of advanced extraskeletal myxoid chondrosarcoma: a multicentre, single-arm, phase 2 trial. Lancet Oncol 2019;20:1252-1262.
[116] Stacchiotti S, Pantaleo MA, Astolfi A, et al. Activity of sunitinib in extraskeletal myxoid chondrosarcoma. Eur J Cancer 2014;50:1657-1664.
[117] Frezza AM, Ravi V, LoVullo S, et al. Systemic therapies in advanced epithelioid haemangioendothelioma: A retrospective international case series from the World Sarcoma Network and a review of literature. Cancer Med 2021;10:2645-2659.
[118] Stacchiotti S, Simeone N, Lo Vullo S, et al. Activity of sirolimus in patients with progressive epithelioid hemangioendothelioma: A case-series analysis within the Italian Rare Cancer Network. Cancer 2021;127:569-576.
[119] Schuetze SM, Ballman KV, Heise R, et al. A Single-arm Phase 2 trial of Trametinib in patients with locally advanced or metastatic epithelioid hemangioendothelioma. Clin Cancer Res 2024;30:4584-4592.

Note: All recommendations are category 2A unless otherwise indicated.

Version 3.2026, 03/12/26 © 2026 National Comprehensive Cancer Network® (NCCN®), All rights reserved. NCCN Guidelines® and this illustration may not be reproduced in any form without the express written permission of NCCN.

PLEASE NOTE that use of this NCCN Content is governed by the End-User License Agreement, and you MAY NOT distribute this Content or use it with any artificial intelligence model or tool.
Printed by Ling Lu on 6/26/2026 6:10:47 AM. Copyright © 2026 National Comprehensive Cancer Network, Inc. All Rights Reserved.

PRINCIPLES OF CANCER RISK ASSESSMENT AND COUNSELING

- See the following for a thorough discussion of how and when to consider testing, important elements of pre-test counseling, points to consider when using multigene testing, how tumor testing can inform germline testing, important elements in post-test counseling, and the importance of family communication:
  - Principles of Cancer Risk Assessment and Counseling (NCCN Guidelines for Genetic/Familial High-Risk Assessment: Breast, Ovarian, Pancreatic, and Prostate [EVAL-A])
- For pedigree development, see Pedigree: First-, Second-, and Third-Degree Relatives of Proband (NCCN Guidelines for Genetic/Familial High-Risk Assessment: Breast, Ovarian, Pancreatic, and Prostate [EVAL-B])

- When to consider genetic testing for inherited soft tissue sarcomas:
  - For Li-Fraumeni syndrome, see NCCN Guidelines for Genetic/Familial High-Risk Assessment: Breast, Ovarian, Pancreatic, and Prostate
  - For HNPCC (or Lynch syndrome) and FAP/attenuated FAP (AFAP) for desmoid tumors, see NCCN Guidelines for Genetic/Familial High-Risk Assessment: Colorectal, Endometrial, and Gastric
  - For patients with personal/family history suggestive of other cancer predisposition syndromes, consider further genetics assessment.

Note: All recommendations are category 2A unless otherwise indicated.

PLEASE NOTE that use of this NCCN Content is governed by the End-User License Agreement, and you MAY NOT distribute this Content or use it with any artificial intelligence model or tool.
Printed by Ling Lu on 6/26/2026 6:10:47 AM. Copyright © 2026 National Comprehensive Cancer Network, Inc. All Rights Reserved.

Table 1
Histopathologic Type
Tumors included in the soft tissue category are listed below as per the 2020 World Health Organization classification of tumors:

Adipocytic Tumors
- Lipoma
- Lipomatosis
- Lipomatosis of nerve
- Lipoblastoma and lipoblastomatosis
- Angiolipoma
- Myolipoma of soft tissue
- Chondroid lipoma
- Spindle cell lipoma and pleomorphic lipoma
- Hibernoma
- Atypical spindle cell/pleomorphic lipomatous tumor
- Atypical lipomatous tumor/well-differentiated liposarcoma
- Dedifferentiated liposarcoma
- Myxoid liposarcoma
- Pleomorphic liposarcoma
- Myxoid pleomorphic liposarcoma

Fibroblastic and Myofibroblastic Tumors
- Nodular fasciitis
- Proliferative fasciitis and proliferative myositis
- Myositis ossificans and fibro-osseous pseudotumor of digits
- Ischemic fasciitis
- Elastofibroma
- Fibrous hamartoma of infancy
- Fibromatosis colli
- Juvenile hyaline fibromatosis
- Inclusion body fibromatosis
- Fibroma of tendon sheath
- Desmoplastic fibroblastoma
- Myofibroblastoma
- Calcifying aponeurotic fibroma
- *EWSR1::SMAD3*-positive fibroblastic tumor (emerging)
- Angiomyofibroblastoma
- Cellular angiofibroma
- Angiofibroma of soft tissue
- Nuchal-type fibroma
- Acral fibromyxoma
- Gardner fibroma
- Palmar fibromatosis and plantar fibromatosis
- Desmoid fibromatosis
- Lipofibromatosis
- Giant cell fibroblastoma
- Dermatofibrosarcoma protuberans
- Solitary fibrous tumor
- Inflammatory myofibroblastic tumor
- Low-grade myofibroblastic sarcoma
- Superficial CD34-positive fibroblastic tumor
- Myxoinflammatory fibroblastic sarcoma
- Infantile fibrosarcoma
- Adult fibrosarcoma
- Myxofibrosarcoma
- Low-grade fibromyxoid sarcoma
- Sclerosing epithelioid fibrosarcoma

So-called Fibrohistiocytic Tumors
- Tenosynovial giant cell tumor
- Deep fibrous histiocytoma
- Plexiform fibrohistiocytic tumor
- Giant cell tumor of soft tissue

Used with permission, WHO Classification of Tumours Editorial Board. Soft tissue and bone tumours. Lyon, France: International Agency for Research on Cancer; 2020. (WHO classification of tumours series, 5th ed.; vol. 3).

Version 3.2026, 03/12/26 © 2026 National Comprehensive Cancer Network® (NCCN®), All rights reserved. NCCN Guidelines® and this illustration may not be reproduced in any form without the express written permission of NCCN.

PLEASE NOTE that use of this NCCN Content is governed by the End-User License Agreement, and you MAY NOT distribute this Content or use it with any artificial intelligence model or tool.
Printed by Ling Lu on 6/26/2026 6:10:47 AM. Copyright © 2026 National Comprehensive Cancer Network, Inc. All Rights Reserved.

Table 1 (continued)
Histopathologic Type
Tumors included in the soft tissue category are listed below as per the 2020 World Health Organization classification of tumors:

Vascular Tumors
- Haemangiomas
  - Synovial haemangioma
  - Intramuscular angioma
  - Arteriovenous malformation/haemangioma
  - Venous haemangioma
- Anastomosing haemangioma
- Epithelioid haemangioma
- Lymphangioma and lymphangiomatosis
- Tufted angioma and kaposiform haemangioendothelioma
- Retiform haemangioendothelioma
- Papillary intralymphatic angioendothelioma
- Composite haemangioendothelioma
- Kaposi sarcoma
- Pseudomyogenic haemangioendothelioma
- Epithelioid haemangioendothelioma
- Angiosarcoma

Pericytic (perivascular) Tumors
- Glomus tumor
- Myopericytoma including myofibroma
- Angioleiomyoma

Smooth Muscle Tumors
- Leiomyoma
- EBV-associated smooth muscle tumor
- Inflammatory leiomyosarcoma
- Leiomyosarcoma

Skeletal Muscle Tumors
- Rhabdomyoma
- Embryonal rhabdomyosarcoma
- Alveolar rhabdomyosarcoma
- Pleomorphic rhabdomyosarcoma
- Spindle cell/sclerosing rhabdomyosarcoma
- Ectomesenchymoma

Chondro-osseous Tumors
- Soft tissue chondroma
- Extraskeletal osteosarcoma

Peripheral Nerve Sheath Tumors
- Schwannoma
- Neurofibroma
- Perineurioma
- Granular cell tumor
- Dermal nerve sheath myxoma
- Solitary circumscribed neuroma
- Ectopic meningioma and meningothelial hamartoma
- Benign triton tumor/neuromuscular choristoma
- Hybrid nerve sheath tumor
- Malignant peripheral nerve sheath tumor
- Malignant melanotic nerve sheath tumour

Used with permission, WHO Classification of Tumours Editorial Board. Soft tissue and bone tumours. Lyon, France: International Agency for Research on Cancer; 2020. (WHO classification of tumours series, 5th ed.; vol. 3).

Version 3.2026, 03/12/26 © 2026 National Comprehensive Cancer Network® (NCCN®), All rights reserved. NCCN Guidelines® and this illustration may not be reproduced in any form without the express written permission of NCCN.

PLEASE NOTE that use of this NCCN Content is governed by the End-User License Agreement, and you MAY NOT distribute this Content or use it with any artificial intelligence model or tool.
Printed by Ling Lu on 6/26/2026 6:10:47 AM. Copyright © 2026 National Comprehensive Cancer Network, Inc. All Rights Reserved.

Table 1 (continued)
Histopathologic Type
Tumors included in the soft tissue category are listed below as per the 2020 World Health Organization classification of tumors:

Tumors of Uncertain Differentiation
- Intramuscular myxoma
- Juxta-articular myxoma
- Deep (aggressive) angiomyxoma
- Atypical fibroxanthoma
- Angiomatoid fibrous histiocytoma
- Ossifying fibromyxoid tumor
- Myoepithelioma myoepithelial carcinoma, and mixed tumor
- Pleomorphic hyalinizing angiectatic tumor of soft parts
- Haemosiderotic fibrolipomatous tumor
- Phosphaturic mesenchymal tumor
- *NTRK*-rearranged spindle cell neoplasm (emerging)
- Synovial sarcoma Epithelioid sarcoma
- Alveolar soft part sarcoma
- Clear cell sarcoma of soft tissue
- Extraskeletal myxoid chondrosarcoma
- Desmoplastic small round cell tumor
- Extrarenal rhabdoid tumor
- PEComa
- Intimal sarcoma
- Undifferentiated sarcoma

Used with permission, WHO Classification of Tumours Editorial Board. Soft tissue and bone tumours. Lyon, France: International Agency for Research on Cancer; 2020. (WHO classification of tumours series, 5th ed.; vol. 3).

Version 3.2026, 03/12/26 © 2026 National Comprehensive Cancer Network® (NCCN®), All rights reserved. NCCN Guidelines® and this illustration may not be reproduced in any form without the express written permission of NCCN.

PLEASE NOTE that use of this NCCN Content is governed by the End-User License Agreement, and you MAY NOT distribute this Content or use it with any artificial intelligence model or tool.
Printed by Ling Lu on 6/26/2026 6:10:47 AM. Copyright © 2026 National Comprehensive Cancer Network, Inc. All Rights Reserved.

American Joint Committee on Cancer (AJCC) Staging System for Soft Tissue Sarcoma of the Head and Neck (8th ed, 2017)

Definitions for T, N, M

T	**Primary Tumor**
TX	Primary tumor cannot be assessed
T1	Tumor ≤2 cm
T2	Tumor >2 cm to ≤4 cm
T3	Tumor >4 cm
T4	Tumor with invasion of adjoining structures
T4a	Tumor with orbital invasion, skull base/dural invasion, invasion of central compartment viscera, involvement of facial skeleton, or invasion of pterygoid muscles
T4b	Tumor with brain parenchymal invasion, carotid artery encasement, prevertebral muscle invasion, or central nervous system involvement via perineural spread

N	**Regional Lymph Nodes**
N0	No regional lymph node metastasis or unknown lymph node status
N1	Regional lymph node metastasis

M	**Distant Metastasis**
M0	No distant metastasis
M1	Distant metastasis

G	**Definition of Grade** **FNCLCC Histologic Grade - see Histologic Grade (G)**
GX	Grade cannot be assessed
G1	Total differentiation, mitotic count and necrosis score of 2 or 3
G2	Total differentiation, mitotic count and necrosis score of 4 or 5
G3	Total differentiation, mitotic count and necrosis score of 6, 7, or 8

Anatomic Stage/Prognostic Groups
This is a new classification that needs data collection before defining a stage grouping for head and neck sarcomas.

Histologic Grade (G)
The FNCLCC grade is determined by three parameters: differentiation, mitotic activity, and extent of necrosis. Each parameter is scored as follows: differentiation (1-3), mitotic activity (1-3), and necrosis (0-2). The scores are added to determine the grade.

Tumor Differentiation

1	Sarcomas closely resembling normal adult mesenchymal tissue (e.g., low-grade leiomyosarcoma)
2	Sarcomas for which histologic typing is certain (e.g., myxoid/round cell liposarcoma)
3	Embryonal and undifferentiated sarcomas, sarcomas of doubtful type, synovial sarcomas, soft tissue osteosarcoma, Ewing sarcoma/primitive neuroectodermal tumor (PNET) of soft tissue

Mitotic Count

In the most mitotically active area of the sarcoma, 10 successive high-power fields (HPF; one HPF at 400× magnification = 0.1734 mm^2) are assessed using a 40× objective.

1	0-9 mitoses per 10 HPF
2	10-19 mitoses per 10 HPF
3	≥20 mitoses per 10 HPF

Tumor Necrosis

Evaluated on gross examination and validated with histologic sections.

0	No necrosis
1	<50% tumor necrosis
2	≥50% tumor necrosis

Histopathologic Type
Please see the WHO Classification of Tumors (ST-1)

Used with permission of the American College of Surgeons, Chicago, Illinois. The original source for this information is the AJCC Cancer Staging Manual, Eighth Edition (2017) published by Springer International Publishing.

Version 3.2026, 03/12/26 © 2026 National Comprehensive Cancer Network® (NCCN®), All rights reserved. NCCN Guidelines® and this illustration may not be reproduced in any form without the express written permission of NCCN.

PLEASE NOTE that use of this NCCN Content is governed by the End-User License Agreement, and you MAY NOT distribute this Content or use it with any artificial intelligence model or tool.
Printed by Ling Lu on 6/26/2026 6:10:47 AM. Copyright © 2026 National Comprehensive Cancer Network, Inc. All Rights Reserved.

American Joint Committee on Cancer (AJCC) Staging System for Soft Tissue Sarcoma of the Trunk and Extremities (8th ed, 2017)

Definitions for T, N, M

T	**Primary Tumor**
TX	Primary tumor cannot be assessed
T0	No evidence for primary tumor
T1	Tumor 5 cm or less in greatest dimension
T2	Tumor more than 5 cm and less than or equal to 10 cm in greatest dimension
T3	Tumor more than 10 cm and less than or equal to 15 cm in greatest dimension
T4	Tumor more than 15 cm in greatest dimension
N	**Regional Lymph Nodes**
N0	No regional lymph node metastasis or unknown lymph node status
N1	Regional lymph node metastasis
M	**Distant Metastasis**
M0	No distant metastasis
M1	Distant metastasis
G	**Definition of Grade** **FNCLCC Histologic Grade - See Histologic Grade (G)**
GX	Grade cannot be assessed
G1	Total differentiation, mitotic count and necrosis score of 2 or 3
G2	Total differentiation, mitotic count and necrosis score of 4 or 5
G3	Total differentiation, mitotic count and necrosis score of 6, 7, or 8

AJCC Anatomic Stage/Prognostic Groups

	T	N	M	G
Stage IA	T1	N0	M0	G1, GX
Stage IB	T2	N0	M0	G1, GX
	T3	N0	M0	G1, GX
	T4	N0	M0	G1, GX
Stage II	T1	N0	M0	G2, G3
Stage IIIA	T2	N0	M0	G2, G3
Stage IIIB	T3	N0	M0	G2, G3
	T4	N0	M0	G2, G3
Stage IV	Any T	N1	M0	Any G
	Any T	Any N	M1	Any G

Histologic Grade (G)

The FNCLCC grade is determined by three parameters: differentiation, mitotic activity, and extent of necrosis. Each parameter is scored as follows: differentiation (1-3), mitotic activity (1-3), and necrosis (0-2). The scores are added to determine the grade.

Tumor Differentiation

1	Sarcomas closely resembling normal adult mesenchymal tissue (e.g., low-grade leiomyosarcoma)
2	Sarcomas for which histologic typing is certain (e.g., myxoid/round cell liposarcoma)
3	Embryonal and undifferentiated sarcomas, sarcomas of doubtful type, synovial sarcomas, soft tissue osteosarcoma, Ewing sarcoma/primitive neuroectodermal tumor (PNET) of soft tissue

Mitotic Count

In the most mitotically active area of the sarcoma, 10 successive high-power fields (HPF; one HPF at 400× magnification = 0.1734 mm^2) are assessed using a 40× objective.

1	0-9 mitoses per 10 HPF
2	10-19 mitoses per 10 HPF
3	≥20 mitoses per 10 HPF

Tumor Necrosis

Evaluated on gross examination and validated with histologic sections.

0	No necrosis
1	<50% tumor necrosis
2	≥50% tumor necrosis

Used with permission of the American College of Surgeons, Chicago, Illinois. The original source for this information is the AJCC Cancer Staging Manual, Eighth Edition (2017) published by Springer International Publishing.

PLEASE NOTE that use of this NCCN Content is governed by the End-User License Agreement, and you MAY NOT distribute this Content or use it with any artificial intelligence model or tool.
Printed by Ling Lu on 6/26/2026 6:10:47 AM. Copyright © 2026 National Comprehensive Cancer Network, Inc. All Rights Reserved.

American Joint Committee on Cancer (AJCC) Staging System for Soft Tissue Sarcoma of the Abdomen and Thoracic Visceral Organs (8th ed, 2017)

Definitions for T, N, M

T	**Primary Tumor**
TX	Primary tumor cannot be assessed
T1	Organ confined
T2	Tumor extension into tissue beyond organ
T2a	Invades serosa or visceral peritoneum
T2b	Extension beyond serosa (mesentery)
T3	Invades another organ
T4	Multifocal involvement
T4a	Multifocal (2 sites)
T4b	Multifocal (3-5 sites)
T4c	Multifocal (>5 sites)

N	**Regional Lymph Nodes**
N0	No regional lymph node involvement or unknown lymph node status
N1	Lymph node involvement present

M	**Distant Metastasis**
M0	No metastasis
M1	Metastases present

G	**Definition of Grade** **FNCLCC Histologic Grade - See Histologic Grade (G)**
GX	Grade cannot be assessed
G1	Total differentiation, mitotic count and necrosis score of 2 or 3
G2	Total differentiation, mitotic count and necrosis score of 4 or 5
G3	Total differentiation, mitotic count and necrosis score of 6, 7, or 8

Anatomic Stage/Prognostic Groups

There is no recommended prognostic stage grouping at this time.

Histologic Grade (G)

The FNCLCC grade is determined by three parameters: differentiation, mitotic activity, and extent of necrosis. Each parameter is scored as follows: differentiation (1-3), mitotic activity (1-3), and necrosis (0-2). The scores are added to determine the grade.

Tumor Differentiation

1	Sarcomas closely resembling normal adult mesenchymal tissue (e.g., low-grade leiomyosarcoma)
2	Sarcomas for which histologic typing is certain (e.g., myxoid/round cell liposarcoma)
3	Embryonal and undifferentiated sarcomas, sarcomas of doubtful type, synovial sarcomas, soft tissue osteosarcoma, Ewing sarcoma/primitive neuroectodermal tumor (PNET) of soft tissue

Mitotic Count

In the most mitotically active area of the sarcoma, 10 successive high-power fields (HPF; one HPF at 400× magnification= 0.1734 mm^2) are assessed using a 40× objective.

1	0-9 mitoses per 10 HPF
2	10-19 mitoses per 10 HPF
3	≥20 mitoses per 10 HPF

Tumor Necrosis

Evaluated on gross examination and validated with histologic sections.

0	No necrosis
1	<50% tumor necrosis
2	≥50% tumor necrosis

Used with permission of the American College of Surgeons, Chicago, Illinois. The original source for this information is the AJCC Cancer Staging Manual, Eighth Edition (2017) published by Springer International Publishing.

PLEASE NOTE that use of this NCCN Content is governed by the End-User License Agreement, and you MAY NOT distribute this Content or use it with any artificial intelligence model or tool.
Printed by Ling Lu on 6/26/2026 6:10:47 AM. Copyright © 2026 National Comprehensive Cancer Network, Inc. All Rights Reserved.

American Joint Committee on Cancer (AJCC) Staging System for Soft Tissue Sarcoma of the Retroperitoneum (8th ed, 2017)

Definitions for T, N, M

T	**Primary Tumor**
TX	Primary tumor cannot be assessed
T0	No evidence of primary tumor
T1	Tumor 5 cm or less in greatest dimension
T2	Tumor more than 5 cm and less than or equal to 10 cm in greatest dimension
T3	Tumor more than 10 cm and less than or equal to 15 cm in greatest dimension
T4	Tumor more than 15 cm in greatest dimension
N	**Regional Lymph Nodes**
N0	No regional lymph node metastasis or unknown lymph node status
N1	Regional lymph node metastases
M	**Distant Metastasis**
M0	No distant metastasis
M1	Distant metastases

G	**Definition of Grade** **FNCLCC Histologic Grade - See Histologic Grade (G)**
GX	Grade cannot be assessed
G1	Total differentiation, mitotic count and necrosis score of 2 or 3
G2	Total differentiation, mitotic count and necrosis score of 4 or 5
G3	Total differentiation, mitotic count and necrosis score of 6, 7, or 8

AJCC Anatomic Stage/Prognostic Groups

	T	N	M	G
Stage IA	T1	N0	M0	G1, GX
Stage IB	T2	N0	M0	G1, GX
	T3	N0	M0	G1, GX
	T4	N0	M0	G1, GX
Stage II	T1	N0	M0	G2, G3
Stage IIIA	T2	N0	M0	G2, G3
Stage IIIB	T3	N0	M0	G2, G3
	T4	N0	M0	G2, G3
	Any T	N1	M0	Any G
Stage IV	Any T	Any N	M1	Any G

Histologic Grade (G)

The FNCLCC grade is determined by three parameters: differentiation, mitotic activity, and extent of necrosis. Each parameter is scored as follows: differentiation (1-3), mitotic activity (1-3), and necrosis (0-2). The scores are added to determine the grade.

Tumor Differentiation

1	Sarcomas closely resembling normal adult mesenchymal tissue (e.g., low-grade leiomyosarcoma)
2	Sarcomas for which histologic typing is certain (e.g., myxoid/round cell liposarcoma)
3	Embryonal and undifferentiated sarcomas, sarcomas of doubtful type, synovial sarcomas, soft tissue osteosarcoma, Ewing sarcoma/primitive neuroectodermal tumor (PNET) of soft tissue

Mitotic Count

In the most mitotically active area of the sarcoma, 10 successive high-power fields (HPF; one HPF at 400× magnification = 0.1734 mm^2) are assessed using a 40× objective.

1	0-9 mitoses per 10 HPF
2	10-19 mitoses per 10 HPF
3	≥20 mitoses per 10 HPF

Tumor Necrosis

Evaluated on gross examination and validated with histologic sections.

0	No necrosis
1	<50% tumor necrosis
2	≥50% tumor necrosis

Used with permission of the American College of Surgeons, Chicago, Illinois. The original source for this information is the AJCC Cancer Staging Manual, Eighth Edition (2017) published by Springer International Publishing.

PLEASE NOTE that use of this NCCN Content is governed by the End-User License Agreement, and you MAY NOT distribute this Content or use it with any artificial intelligence model or tool.
Printed by Ling Lu on 6/26/2026 6:10:47 AM. Copyright © 2026 National Comprehensive Cancer Network, Inc. All Rights Reserved.

ABBREVIATIONS

ALT	atypical lipomatous tumor
AFAP	attenuated familial adenomatous polyposis
ASPS	alveolar soft part sarcoma
C/A/P	chest/abdomen/pelvis
CNS	central nervous system
COG	Children's Oncology Group
CR	complete response
cTACE	conventional transarterial chemoembolization
CTV	clinical target volume
CXR	chest radiograph
ddLPS	dedifferentiated liposarcoma
DEB	drug-eluting bead
DEB-TACE	drug-eluting bead transarterial chemoembolization
DFSP	dermatofibrosarcoma protuberans
dMMR	mismatch repair deficient
EBRT	external beam radiation therapy
EDTA	ethylenediamine tetraacetic acid
EHE	epithelioid hemangioendothelioma
FAP	familial adenomatous polyposis
FISH	fluorescence in situ hybridization
FNCLCC	Fédération Nationale des Centres de Lutte Contre le Cancer
GIST	gastrointestinal stromal tumor
H&P	history and physical
HNPCC	hereditary non-polyposis colorectal cancer
HPF	high-power field
IGRT	image-guided radiation therapy
IHC	immunohistochemistry
IMRT	intensity-modulated radiation therapy
IMT	inflammatory myofibroblastic tumor
IORT	intraoperative radiation therapy
LMS	leiomyosarcoma
MFS	myxofibrosarcoma
MPNST	malignant peripheral nerve sheath tumor
MSI-H	microsatellite instability-high
NGS	next-generation sequencing
NSAID	nonsteroidal anti-inflammatory drug
OS	overall survival
PCR	polymerase chain reaction
PEComa	perivascular epithelioid cell tumor
PM&R	physical medicine and rehabilitation
PNET	primitive neuroectodermal tumor
PVNS	pigmented villonodular synovitis
RMS	rhabdomyosarcoma
SBRT	stereotactic body radiation therapy
SIB	simultaneous integrated boost
STS	soft tissue sarcoma
TACE	transarterial chemoembolization
TAE	transarterial embolization
TARE	transarterial radioembolization
TGCT	tenosynovial giant cell tumor
TMB-H	tumor mutational burden-high
TNM	tumor node metastasis
UPS	undifferentiated pleomorphic sarcoma
WB	whole body
WDLPS	well-differentiated liposarcoma

Version 3.2026, 03/12/26 © 2026 National Comprehensive Cancer Network® (NCCN®), All rights reserved. NCCN Guidelines® and this illustration may not be reproduced in any form without the express written permission of NCCN.

PLEASE NOTE that use of this NCCN Content is governed by the End-User License Agreement, and you MAY NOT distribute this Content or use it with any artificial intelligence model or tool.
Printed by Ling Lu on 6/26/2026 6:10:47 AM. Copyright © 2026 National Comprehensive Cancer Network, Inc. All Rights Reserved.

NCCN Categories of Evidence and Consensus	
Category 1	Based upon high-level evidence (≥1 randomized phase 3 trials or high-quality, robust meta-analyses), there is uniform NCCN consensus (≥85% support of the Panel) that the intervention is appropriate.
Category 2A	Based upon lower-level evidence, there is uniform NCCN consensus (≥85% support of the Panel) that the intervention is appropriate.
Category 2B	Based upon lower-level evidence, there is NCCN consensus (≥50%, but <85% support of the Panel) that the intervention is appropriate.
Category 3	Based upon any level of evidence, there is major NCCN disagreement that the intervention is appropriate.

All recommendations are category 2A unless otherwise indicated.

NCCN Categories of Preference	
Preferred	Interventions that are based on superior efficacy, safety, and evidence; and, when appropriate, affordability.
Other recommended	Other interventions that may be somewhat less efficacious, more toxic, or based on less mature data; or significantly less affordable for similar outcomes.
Useful in certain circumstances	Other interventions that may be used for selected patient populations (defined with recommendation).

All recommendations are considered appropriate.

Note: All recommendations are category 2A unless otherwise indicated.

PLEASE NOTE that use of this NCCN Content is governed by the End-User License Agreement, and you MAY NOT distribute this Content or use it with any artificial intelligence model or tool.
Printed by Ling Lu on 6/26/2026 6:10:47 AM. Copyright © 2026 National Comprehensive Cancer Network, Inc. All Rights Reserved.

Discussion

This discussion corresponds to the NCCN Guidelines for Soft Tissue Sarcoma. Sections of this discussion were updated on May 16, 2022 to correspond with the latest algorithm. The remainder of the discussion was last updated on March 27, 2018.

Table of Contents

Overview MS-2
Literature Search Criteria and Guidelines Update Methodology MS-2
Genetic Cancer Syndromes with Predisposition to Soft Tissue Sarcoma MS-3
Pathology of Soft Tissue Sarcomas MS-4
Staging MS-6
Surgery MS-6
Radiation Therapy MS-7
Chemotherapy/Chemoradiation MS-8
Targeted Therapy MS-11
Soft Tissue Sarcomas of the Extremities, Superficial Trunk, or Head and Neck MS-12
Retroperitoneal/Intra-abdominal Soft Tissue Sarcomas MS-22
Desmoid Tumors (Aggressive Fibromatoses) MS-30
Rhabdomyosarcoma MS-34
References MS-37

Discussion update in progress

Version 3.2026 © 2026 National Comprehensive Cancer Network® (NCCN©), All rights reserved. NCCN Guidelines® and this illustration may not be reproduced in any form without the express written permission of NCCN.

PLEASE NOTE that use of this NCCN Content is governed by the End-User License Agreement, and you MAY NOT distribute this Content or use it with any artificial intelligence model or tool.
Printed by Ling Lu on 6/26/2026 6:10:47 AM. Copyright © 2026 National Comprehensive Cancer Network, Inc. All Rights Reserved.

Overview

Sarcomas are a rare and heterogeneous group of solid tumors of mesenchymal origin accounting for only 1% of all adult malignancies and 15% of childhood malignancies. They can be divided broadly into:

- Sarcomas of soft tissues (including fat, muscle, nerve and nerve sheath, blood vessels, and other connective tissues) and
- Sarcomas of bone

In 2022, an estimated 13,190 people will be diagnosed with soft tissue sarcoma (STS) in the United States, with approximately 5130 deaths.[1] The true incidence of STS is underestimated, especially because a large proportion of patients with gastrointestinal stromal tumors (GIST) may not have been included in tumor registry databases before 2001. Prior radiation therapy (RT) to the affected area is a risk factor for the development of STS.[2-4] Other risk factors that are associated with the development of STS include various chemicals (eg, herbicides, such as agent orange) as well as genetic syndromes (eg, Li-Fraumeni syndrome, neurofibromatosis).[5] More than 50 different histologic subtypes of STS have been identified. STS most commonly metastasizes to the lungs; tumors arising in the abdominal cavity more commonly metastasize to the liver and peritoneum.

The NCCN Guidelines® for Soft Tissue Sarcoma address the management of STS in adult patients from the perspective of the following disease subtypes:

- STS of extremity, superficial/trunk, or head and neck
- Retroperitoneal or intra-abdominal STS
- Desmoid tumors (aggressive fibromatoses)
- Rhabdomyosarcoma (RMS)

The anatomic site of the primary disease represents an important variable that influences treatment and outcome. Extremities (43%), the trunk (10%), visceral (19%), retroperitoneum (15%), or head and neck (9%) are the most common primary sites.[6] Desmoid tumors, or aggressive fibromatosis (AF), are a unique soft tissue tumor subtype that is characterized by local infiltration rather than distant metastasis. RMS is the most common STS of children and adolescents, and is less common in adults.

Prior to initiation of treatment, all patients should be evaluated and managed by a multidisciplinary team with extensive expertise and experience in the treatment of STS.[7] Because STS is rare and often complex, adherence to evidence-based recommendations is particularly important. Analysis of data from 15,957 patients with STS in the National Cancer Database (NCDB) showed that NCCN Guidelines-adherent treatment was associated with improved survival outcomes.[8]

Literature Search Criteria and Guidelines Update Methodology

Prior to the update of this version of the NCCN Guidelines for Soft Tissue Sarcoma, an electronic search of the PubMed database was performed to obtain key literature in STS, using the following search terms: soft tissue sarcoma OR desmoid OR aggressive fibromatosis OR rhabdomyosarcoma OR *sarcoma. The PubMed database was chosen as it remains the most widely used resource for medical literature and indexes only peer-reviewed biomedical literature.

The search results were narrowed by selecting studies in humans published in English. Results were confined to the following article types: Clinical Study; Clinical Trial; Guideline; Randomized Controlled Trial; Meta-Analysis; Systematic Reviews; and Validation Studies.

Discussion update in progress

Version 3.2026 © 2026 National Comprehensive Cancer Network® (NCCN©), All rights reserved. NCCN Guidelines® and this illustration may not be reproduced in any form without the express written permission of NCCN.

PLEASE NOTE that use of this NCCN Content is governed by the End-User License Agreement, and you MAY NOT distribute this Content or use it with any artificial intelligence model or tool.
Printed by Ling Lu on 6/26/2026 6:10:47 AM. Copyright © 2026 National Comprehensive Cancer Network, Inc. All Rights Reserved.

The PubMed search resulted in 50 citations and their potential relevance was examined. The data from key PubMed articles as well as articles from additional sources deemed as relevant to these guidelines and discussed by the panel have been included in this version of the Discussion section (eg, e-publications ahead of print, meeting abstracts). Recommendations for which high-level evidence is lacking are based on the panel's review of lower-level evidence and expert opinion.

The complete details of the Development and Update of the NCCN Guidelines are available at www.NCCN.org.

Genetic Cancer Syndromes with Predisposition to Soft Tissue Sarcoma

Genetic cancer syndromes caused by germline mutations in a number of different genes are also associated with an inherited predisposition for the development of STS.[3,9-13]

Li-Fraumeni syndrome (resulting from germline mutations in the *TP53* tumor suppressor gene) is characterized by an increased risk of developing multiple primary malignancies, predominantly STS, osteosarcomas, breast cancer, leukemia, brain tumors, and adrenocortical carcinoma before 45 years of age.[9,14-16] The incidence of STS ranges from 12% to 21% in individuals with *TP53* germline mutations.[17-19] In general, STS associated with Li-Fraumeni syndrome is diagnosed at significantly younger ages than sporadic STS. The mean age at diagnosis, however, varies with the histologic subtype. In an analysis of 475 tumors in 91 families with *TP53* germline mutations, Kleihues and colleagues reported RMS, fibrosarcomas, and UPS as the most frequent histologic subtypes identified in 55%,13%, and 10% of patients, respectively.[17] The mean age at diagnosis for RMS was younger than 6 years, and the mean age at diagnosis for UPS was older than 50 years.

Familial adenomatous polyposis (FAP) is an inherited autosomal-dominant colorectal cancer syndrome resulting from the germline mutations in the adenomatous polyposis coli [*APC*] gene on chromosome 5q21.[10,12] FAP is characterized by adenomatous colorectal polyps that progress to colorectal cancer at 35 to 40 years of age. Gardner's syndrome is considered a variant of FAP with extracolonic manifestations such as osteomas, skin cysts, congenital hypertrophy of the retinal pigmented epithelium, and desmoid tumors (aggressive fibromatosis).[20] Desmoid tumors have been reported to occur in 7.5% to 16% of patients with FAP, and the relative risk of developing desmoid tumors is much higher in patients with FAP than the general population.[21-24] In an International Dutch Cohort study involving 2260 patients with FAP, positive family history for desmoid tumors, abdominal surgery, and the *APC* mutation site were identified as significant risk factors for the development of desmoid tumors.[24] The median age at diagnosis was 31 years, with the majority of desmoid tumors arising in the intra-abdominal and abdominal wall locations (53% and 24%, respectively).

Carney-Stratakis syndrome is an autosomal-dominant familial syndrome characterized by a predisposition to GIST and paragangliomas.[25] Germline loss-of-function mutations within the succinate dehydrogenase (*SDH*) gene subunits (*SDHB*, *SDHC,* and *SDHD*) have been identified in individuals with GIST associated with Carney-Stratakis syndrome.[26] In an analysis of 11 patients from 9 families presenting with GIST and paragangliomas associated with Carney-Stratakis syndrome, Pasini and colleagues identified germline mutations in *SDHB*, *SDHC,* or *SDHD* genes in 8 patients (from 7 untreated families) with GIST.[26] The tumors also lacked activating *KIT* or platelet-derived growth factor receptor alpha (*PDGFRA*) mutations associated with sporadic GIST. GIST associated with Carney-Stratakis syndrome are also reported to be negative for SDHB protein expression by immunohistochemistry (IHC), in contrast to GIST with *KIT* or *PDGFRA* mutations or sporadic GIST.[27,28]

Discussion update in Progress

Version 3.2026 © 2026 National Comprehensive Cancer Network® (NCCN©), All rights reserved. NCCN Guidelines® and this illustration may not be reproduced in any form without the express written permission of NCCN.

PLEASE NOTE that use of this NCCN Content is governed by the End-User License Agreement, and you MAY NOT distribute this Content or use it with any artificial intelligence model or tool.
Printed by Ling Lu on 6/26/2026 6:10:47 AM. Copyright © 2026 National Comprehensive Cancer Network, Inc. All Rights Reserved.

Hereditary retinoblastoma caused by a germline mutation in the retinoblastoma tumor suppressor gene (*RB1*) is also associated with an increased risk for the development of STS.[11,29] LMS is the most frequent STS subtype (with 78% of LMS diagnosed 30 or more years after the diagnosis of retinoblastoma). Although patients with RT for retinoblastoma are at significantly increased risk of developing STS, the risks of developing STS are also increased in non-irradiated patients as well, indicating a genetic predisposition to STS that is independent of RT in patients with hereditary retinoblastoma.[11]

Neurofibromatoses are hereditary conditions caused by mutations in the neurofibromin 1 gene (NF1) or neurofibromin 2 gene (NF2).[30] Approximately 5% of patients with neurofibromatosis are thought to develop STS. Most commonly occurring are malignant peripheral nerve sheath tumors (MPNSTs), a type of sarcoma that can arise from previously benign neurofibromas.[31] For information on the treatment of MPNSTs, see the NCCN Guidelines for Central Nervous System Cancers at www.NCCN.org.

NCCN Recommendations for Genetic Testing and Counseling for Patients with Germline Mutations

- Patients (and their families) with a personal and/or family history suggestive of Li-Fraumeni syndrome should be considered for further genetics assessment as outlined in the NCCN Guidelines for Genetic/Familial High-Risk Assessment: Breast and Ovarian.

- *SDH* gene mutational analysis for the identification of germline mutations in the *SDH* gene subunits should be considered for patients with GIST lacking KIT or PDGFRA mutations. Loss of SDHB protein expression by IHC is a useful screen to identify patients who would be appropriate for germline mutation testing, but it is not diagnostic of a germline mutation.

- Evaluation for family history of FAP or Gardner's syndrome is recommended for patients diagnosed with desmoid tumors (aggressive fibromatoses).

Pathology of Soft Tissue Sarcomas

Biopsy

A pretreatment biopsy is highly preferred for the diagnosis and grading of STS. Biopsy should be performed by an experienced surgeon or radiologist, placed along the future resection axis with minimal dissection and careful attention to hemostasis. The goal of biopsy is to establish the malignancy and provide a specific diagnosis where possible and a grade where appropriate or feasible, recognizing that limited biopsy material may underestimate grade. It may be accomplished by open incisional or core needle technique. Core needle biopsy is preferred; however, an open incisional biopsy may be considered by an experienced surgeon. In patients without a definitive diagnosis following initial biopsy due to limited sampling size, repeat image-guided core needle biopsy should be considered to make a diagnosis. Although fine-needle aspiration (FNA) is a convenient technique, it can be difficult to make an accurate primary diagnosis with FNA alone due to small specimen size and is thus discouraged.[32] FNA may be acceptable in select institutions with clinical and pathologic expertise. Endoscopic or needle biopsy may be indicated for deep thoracic, abdominal, or pelvic STS.

Principles of Pathologic Assessment

Pathologists with expertise in STS should review the pathologic assessment of biopsies and resected specimens, especially for initial histopathologic classification. Margins must be thoroughly evaluated in these specimens. Morphologic assessment based on microscopic examination of histologic sections remains the gold standard of sarcoma diagnosis. The differential diagnosis of a soft tissue mass includes malignant lesions (such as primary or metastatic carcinoma, melanoma, or

Version 3.2026 © 2026 National Comprehensive Cancer Network® (NCCN©), All rights reserved. NCCN Guidelines® and this illustration may not be reproduced in any form without the express written permission of NCCN.

PLEASE NOTE that use of this NCCN Content is governed by the End-User License Agreement, and you MAY NOT distribute this Content or use it with any artificial intelligence model or tool.
Printed by Ling Lu on 6/26/2026 6:10:47 AM. Copyright © 2026 National Comprehensive Cancer Network, Inc. All Rights Reserved.

lymphoma), desmoids, and benign lesions (such as lipomas, lymphangiomas, leiomyomas, and neuromas). However, since the identification of the histopathologic type of a sarcoma is often difficult, several ancillary techniques have been used as an adjunct to morphologic diagnosis. These techniques include conventional cytogenetics, IHC, electron microscopy, and molecular genetic testing. Pathologists should have access to optimal cytogenetic and molecular diagnostic techniques. The results of appropriate ancillary studies used as an adjunct to morphologic diagnosis should be included in the pathology report.

The pathology report should include specific details about the primary diagnosis (using standardized nomenclature according to the WHO Classification of STS tumor); the organ and site of sarcoma; depth, size, and histologic grade of the tumor; presence or absence of necrosis; status of excision margins and lymph nodes; tumor, node, and metastasis (TNM) stage; and additional features such as mitotic rate, presence or absence of vascular invasion, and the type and extent of inflammatory infiltration.

Molecular Diagnosis of Soft Tissue Sarcomas

Molecular genetic testing has emerged as a particularly useful ancillary technique since many subtypes of STS are associated with characteristic genetic aberrations including single base-pair substitutions, deletions, amplifications, and translocations. STS can be divided into two major genetic groups: 1) sarcomas with specific genetic alterations (eg, chromosomal translocations or point mutations) and usually simple karyotypes; and 2) sarcomas with non-specific genetic alterations and complex unbalanced karyotypes.[33]

STS with recurrent chromosomal translocations can be classified into subtypes depending on the presence of fusion gene transcripts (eg, *EWSR1-ATF1* in clear cell sarcoma, *TLS-CHOP* [also known as *FUS-DDIT3*] in myxoid or round cell LPS, *SS18-SSX* [*SS18-SSX1 or SS18-SSX2*] in synovial sarcoma, and *PAX-FOXO1* [*PAX3-FOXO1 or PAX7-FOXO1*] in alveolar RMS). The fusion genes resulting from chromosomal translocations can provide useful diagnostic and prognostic information. See *Principles of Ancillary Techniques Useful in the Diagnosis of Sarcomas* in the guidelines for a list of recurrent genetic aberrations associated with other subtypes.

Conventional cytogenetic analysis, fluorescence in situ hybridization (FISH), and polymerase chain reaction (PCR) are the most common techniques used in the molecular diagnosis of STS.[34] In a prospective study, Hill and colleagues concluded that PCR-based molecular analysis is more sensitive than conventional cytogenetics and is a useful adjunct for the diagnosis of alveolar RMS, synovial sarcoma, and myxoid LPS that have variation in fusion gene partners.[35] Molecular genetic testing was analyzed in a prospective, multicenter study (GENSARC) that enrolled 395 patients with histologic diagnoses of various sarcoma subtypes.[36] Molecular classification of samples from these patients was performed using FISH, comparative genomic hybridization, and PCR, resulting in modified diagnoses in 53 cases. The modified molecular diagnosis reportedly shifted prognosis and primary management in 45 of these cases.

The molecular heterogeneity of fusion gene transcripts has been suggested to predict prognosis in certain sarcoma subtypes. In patients with alveolar RMS presenting with metastatic disease, *PAX7-FOXO1* was associated with a favorable prognosis compared to *PAX3-FOXO1*.[37] In patients with synovial sarcoma, the prognostic impact of *SS18-SSX1* or *SS18-SSX2* is less clear with two large studies showing conflicting results.[38,39] In myxoid LPS, the variability of fusion gene transcript has no effect on clinical outcome.[40]

While molecular genetic testing appears promising, it involves highly complex techniques and the methods are not absolutely sensitive or they

Version 3.2026 © 2026 National Comprehensive Cancer Network® (NCCN©), All rights reserved. NCCN Guidelines® and this illustration may not be reproduced in any form without the express written permission of NCCN.

PLEASE NOTE that use of this NCCN Content is governed by the End-User License Agreement, and you MAY NOT distribute this Content or use it with any artificial intelligence model or tool.
Printed by Ling Lu on 6/26/2026 6:10:47 AM. Copyright © 2026 National Comprehensive Cancer Network, Inc. All Rights Reserved.

do not provide specific results. Molecular testing should be performed by a pathologist with expertise in the use of molecular diagnostic techniques for the diagnosis of STS. In addition, technical limitations associated with molecular testing suggest that molecular evaluation should be considered only as an ancillary technique. Molecular test results should therefore only be interpreted in the context of the clinical and pathologic features of a sarcoma.[34]

Staging

The revised AJCC Cancer Staging Manual, Eighth Edition (2017), effective January 2018, is based on TNM and tumor grade. AJCC follows the grading system of the French Federation of Cancer Centers Sarcoma Group (FNCLCC), a 3-tiered system based on tumor cell differentiation, mitotic activity, and extent of necrosis.[41] The panel recommends determination of histologic grade using the FNCLCC or AJCC/National Cancer Institute (NCI) system or appropriate diagnosis-specific grading system if applicable.

Surgery

Surgical resection (with appropriately negative margins) is the standard primary treatment for most patients with STS, although close margins may be necessary to preserve uninvolved critical neurovascular structures. RT and/or chemotherapy (in the case of chemosensitive histologies) are often used prior to surgery in many centers to downstage large high-grade tumors to enable effective surgical resection, because the risk of failure in the surgical bed can be high. Postoperative RT should be considered following resections with close soft tissue margins (<1 cm) or a microscopically positive margin on bone, major blood vessels, or a nerve. In selected cases when margin status is uncertain, consultation with a radiation oncologist is recommended.

The biopsy site should be excised en bloc with the definitive surgical specimen. Dissection should be through grossly normal tissue planes uncontaminated by tumor. If the tumor is close to or displaces major vessels or nerves, these need not be resected if the adventitia or perineurium is removed and the underlying neurovascular structures are not involved with gross tumor. Radical excision or entire anatomic compartment resection is not routinely necessary. If resections with microscopically positive or grossly positive margins are anticipated, surgical clips should be left in place to identify high-risk areas for recurrence, particularly for retroperitoneal or intra-abdominal sarcomas to help guide future RT. If closed suction drainage is used, the drains should exit the skin close to the edge of the surgical incision (in case re-resection or RT is indicated).

Both the surgeon and the pathologist should document surgical margins while evaluating a resected specimen. Complete tumor resection is a primary prognostic factor for local recurrence (LR). If surgical margins are positive on final pathology, re-resection to obtain negative margins should be strongly considered if it will not have a significant impact on functionality.[42,43] In an analysis of 666 consecutive patients with localized STS treated with an apparent macroscopic total tumor resection, residual tumor was found in 46% of patients, including macroscopic tumor in 28%. A total of 295 patients underwent reresection of their tumor bed. Local control rates at 5, 10, and 15 years were 85%, 85%, and 82%, respectively, for patients who underwent reresection, versus 78%, 73%, and 73%, respectively (P = .03) for patients who did not undergo reresection. Recent studies of tumor margin classification systems provide insight into LR risk assessment and may help to guide surgical planning and decisions regarding re-resection.[44,45]

The implications of lymph node evaluation were recently examined based on data from 2993 patients with resected STS in the NCDB (5.9% nodal

Version 3.2026 © 2026 National Comprehensive Cancer Network® (NCCN©), All rights reserved. NCCN Guidelines® and this illustration may not be reproduced in any form without the express written permission of NCCN.

PLEASE NOTE that use of this NCCN Content is governed by the End-User License Agreement, and you MAY NOT distribute this Content or use it with any artificial intelligence model or tool.
Printed by Ling Lu on 6/26/2026 6:10:47 AM. Copyright © 2026 National Comprehensive Cancer Network, Inc. All Rights Reserved.

metastasis rate).[46] Omission of nodal evaluation was associated with risk of death, and pathologic identification of nodal disease was related to lower median OS in histologic subtypes such as epithelioid and clear cell sarcomas.

Radiation Therapy

RT can be administered either as primary, preoperative, or postoperative treatment. Total RT doses are always determined based on the tissue tolerance. Newer RT techniques such as brachytherapy, intraoperative RT (IORT), and intensity-modulated RT (IMRT) have led to the improvement of treatment outcomes in patients with STS. Brachytherapy involves the direct application of radioactive seeds into the tumor bed through catheters placed during surgery. Options include low dose-rate (LDR) brachytherapy, fractionated high dose-rate (HDR) brachytherapy, or intraoperative HDR brachytherapy.[47] LDR and HDR brachytherapy are associated with similar rates of local control.[48] It has been suggested that HDR brachytherapy may be associated with lower incidences of severe toxicity; however, this has not been proven in randomized clinical trials.[48] The main advantage of IMRT is its ability to more closely contour the high-dose radiation volume thereby minimizing the volume of high-dose radiation to the surrounding normal tissues.[49] Additionally, image-guided techniques may allow for reduced target volumes, further minimizing toxicity.[50,51] IORT is the delivery of radiation during surgery and it can be performed using different techniques such as electron beam RT or brachytherapy.[52]

A recent systematic review and meta-analysis examined the effects of external beam RT (EBRT) (vs. no EBRT) on LR and OS, also comparing preoperative to postoperative approaches for STS.[53] Data analysis from 16 studies (n = 3958) indicated that EBRT reduced LR and improved OS for retroperitoneal STS, and reduced LR for STS of the extremity, head and neck, or trunk wall (OR, 0.49; 95% CI, 0.31–0.77; *P* = .002). Based on a subset of 11 studies, LR rates were lower with preoperative RT than for postoperative RT for retroperitoneal STS (OR, 0.03; *P* = .02) and other tumor locations (OR, 0.67; *P* =.01). Results of a randomized study showed a non-significant trend toward reduced late toxicities (fibrosis, edema, and joint stiffness) with preoperative compared to postoperative radiation and a significant association between these toxicities and increasing treatment field size. Because postoperative radiation fields are typically larger than preoperative fields, the panel has expressed a general preference for preoperative radiation, particularly when treatment volumes are large.[54,55]

Preoperative RT may reduce seeding during the surgical manipulation of the tumor. The tumor may or may not regress with preoperative RT, but the pseudocapsule may thicken and become acellular, easing resection and decreasing the risk of recurrence.[56-58] Most institutions include the entire operative bed within the RT field. The main disadvantage of preoperative RT, however, is its effect on wound healing.[59,60] Wound complications in patients with sarcoma are more frequently associated with pre- vs. postoperative RT.[53] After preoperative RT, a 3- to 6-week interval is necessary before resection to allow acute reactions to subside and decrease the risk of wound complications.[61] Involvement of a plastic surgeon on the team may be necessary to reduce wound complications when preoperative RT is contemplated.

Postoperative RT is associated with higher rates of long-term treatment-related side effects. In one retrospective analysis, although there was no evidence for differences in disease outcome associated with the use of either preoperative or postoperative RT, there was a slight increase in late treatment-related side effects with postoperative RT, mainly due to the higher doses used.[62] Positive surgical margins are associated with higher rates of LR.[63] Postoperative RT has been shown to improve local control in patients with positive surgical margins.[64] Of those with positive margins, RT doses >64 Gy, microscopically positive

Version 3.2026 © 2026 National Comprehensive Cancer Network® (NCCN©), All rights reserved. NCCN Guidelines® and this illustration may not be reproduced in any form without the express written permission of NCCN.

PLEASE NOTE that use of this NCCN Content is governed by the End-User License Agreement, and you MAY NOT distribute this Content or use it with any artificial intelligence model or tool.
Printed by Ling Lu on 6/26/2026 6:10:47 AM. Copyright © 2026 National Comprehensive Cancer Network, Inc. All Rights Reserved.

margins, superficial location, and extremity site are associated with improved local control.

Postoperative RT boost of 16 Gy has been used in patients with positive surgical margins after the wound has healed. However, the results of a retrospective analysis showed that postoperative RT boost did not provide any advantage in preventing LR in some patients with positive surgical margins (such as those with low-grade, well-differentiated LPS [WDLS] and a focally "planned" positive margin on an anatomically fixed critical structure).[65] Similarly, another retrospective matched cohort of patients with extremity STS found no added benefit of postoperative RT boost when evaluating LR, distant metastasis, and mortality.[66]

The advantage of adding postoperative RT boost has not yet been evaluated in a randomized clinical trial. Intervals beyond 8 weeks between resection and postoperative RT are not recommended because of the development of late fibrosis and the proliferation of malignant cells. The risk of LR versus the toxicity of postoperative RT should be assessed before making a decision regarding the use of postoperative RT.

Chemotherapy/Chemoradiation

Resectable Disease

Preoperative Therapy

Preoperative chemotherapy[67-71] or chemoradiation[72-81] has been evaluated in single and multicenter studies in patients with high-grade tumors.

Studies that have evaluated preoperative chemotherapy followed by surgery have reported inconsistent findings. The results of a randomized study that compared surgery alone vs. preoperative chemotherapy followed by surgery in 134 evaluable patients with high-risk tumors (tumors ≥8 cm of any grade, grade II/III tumors <8 cm, grade II/III locally recurrent tumors, or tumors with inadequate surgery) did not show a major survival benefit for patients receiving chemotherapy.[68] At a median follow-up of 7.3 years, the estimated 5-year disease-free survival (DFS) rate was 52% for the no chemotherapy arm and 56% for the chemotherapy arm (P = .3548). The corresponding 5-year overall survival (OS) rate for both arms was 64% and 65%, respectively (P = .2204). A cohort analysis of 674 patients with stage III STS of extremity treated at a single institution revealed that clinical benefits associated with preoperative or postoperative doxorubicin-based chemotherapy were not sustained beyond one year.[69] In another retrospective study, the benefit of preoperative chemotherapy was only seen in patients with high-grade extremity tumors larger than 10 cm but not in patients with tumors 5 to 10 cm.[70]

In a single-institution study involving 48 patients with high-grade extremity STS (8 cm or larger), the outcome of patients treated with preoperative chemoradiation with the MAID (mesna, doxorubicin, ifosfamide, and dacarbazine) regimen followed by surgery and postoperative chemotherapy with the same regimen was superior to that of historical controls.[74] The 5-year actuarial local control, freedom from distant metastasis, DFS, and OS rates were 92% and 86% (P = .1155), 75% and 44% (P = .0016), 70% and 42% (P = .0002), and 87% and 58% (P = .0003) for the MAID and control groups, respectively.[74] The same protocol was later evaluated in the RTOG 9514 study of 66 patients with large (8 cm or larger), high-grade (stage II or III; grade 2 or 3 in a 3-tier grading system), primary, or locally recurrent STS of the extremities or trunk.[76,77] The 5-year rates of locoregional failure (including amputation) and distant metastasis were 22% and 28%, respectively, with a median follow-up of 7.7 years. The estimated 5-year DFS, distant DFS, and OS rates were 56%, 64%, and 71%, respectively.[77] Long-term follow-up data of these studies confirmed that preoperative chemoradiation followed by resection and postoperative chemotherapy with a doxorubicin-based regimen improves local control and OS and DFS rates in patients with high-grade

Discussion update in progress

Version 3.2026 © 2026 National Comprehensive Cancer Network® (NCCN©), All rights reserved. NCCN Guidelines® and this illustration may not be reproduced in any form without the express written permission of NCCN.

PLEASE NOTE that use of this NCCN Content is governed by the End-User License Agreement, and you MAY NOT distribute this Content or use it with any artificial intelligence model or tool.
Printed by Ling Lu on 6/26/2026 6:10:47 AM. Copyright © 2026 National Comprehensive Cancer Network, Inc. All Rights Reserved.

STS of extremity and body wall; however, preoperative chemoradiation was associated with significant short-term toxicities.[77,78]

Postoperative Therapy

Available evidence from meta-analyses[82-86] and randomized clinical trials[87-92] suggests that postoperative chemotherapy improves relapse-free survival (RFS) in patients with STS of extremities. However, data regarding OS advantage are conflicting.

The Sarcoma Meta-Analysis Collaboration (SMAC) performed a meta-analysis of 14 randomized studies (1568 patients), which compared postoperative chemotherapy to follow-up and in some cases RT after surgery with a variety of sarcomas.[83] The result of the meta-analysis showed that doxorubicin-based chemotherapy prolongs local and distant recurrence and overall RFS in adults with localized, resectable STS of the extremity and is associated with decreased recurrence rates. The OS advantage was not significant, although there was a trend in favor of postoperative chemotherapy.

An updated meta-analysis also confirmed the marginal efficacy of postoperative chemotherapy in terms of local, distant, and overall recurrence as well as OS (which is contrary to that reported in the SMAC meta-analysis) in patients with localized STS (n = 1953).[85] A recent large, cohort-based analysis with a median follow-up of 9 years indicated that postoperative chemotherapy may be associated with significantly improved 5-year metastasis-free survival (58% vs. 49%, *P* = .01) and 5-year OS (58% vs. 45%, *P* = .0002) in patients with FNCLCC grade 3 STS, whereas it was not significantly different in those with FNCLCC grade 2 STS (5-year metastasis-free survival: 76% vs. 73%, *P* = .27; 5-year OS: 75% vs. 65%, *P* = .15).[86]

In the Italian randomized cooperative study (n = 104), which randomized patients with high-grade or recurrent extremity sarcoma to receive postoperative chemotherapy with epirubicin and ifosfamide or observation alone, after a median follow-up of 59 months, median DFS (48 vs. 16 months) and median OS (75 months vs. 46 months) were significantly better in the treatment group; the absolute benefit for OS from chemotherapy was 13% at 2 years and increased to 19% at 4 years for patients receiving chemotherapy.[88] After a median follow-up of 90 months, the estimated 5-year OS rate was 66% and 46%, respectively (*P* = .04), for the treatment group and the control group; however, the difference was not statistically different in the intent-to-treat analysis.[93]

In another phase III randomized study (EORTC-62931), 351 patients with macroscopically resected grade II-III tumors with no metastases were randomized to observation or postoperative chemotherapy with ifosfamide and doxorubicin with lenograstim.[90] A planned interim analysis of this study showed no survival advantage for postoperative chemotherapy in patients with resected high-grade STS. The estimated 5-year RFS was 52% in both arms and the corresponding OS rates were 64% and 69%, respectively, for patients assigned to postoperative chemotherapy and observation. These findings are consistent with the results reported in an earlier EORTC study by Bramwell and colleagues.[87] In that study, postoperative chemotherapy with CYVADIC (cyclophosphamide, vincristine, doxorubicin, and dacarbazine) was associated with higher RFS rates (56% vs. 43% for the control group; *P* = .007) and significantly lower LR rates (17% vs. 31% for the control group; *P* = .004). However, there were no differences in distant metastases (32% and 36%, respectively, for CYVADIC and the control group; *P* = .42) and OS rates (63% and 56%, respectively, for CYVADIC and the control group; *P* = .64).

A recent pooled analysis of these two randomized EORTC studies (pooled n = 819) evaluated whether adjuvant doxorubicin-based chemotherapy provided survival benefits in any particular subset of patients with resected STS in these trials.[92] Postoperative doxorubicin-based chemotherapy was

Discussion update in progress

Version 3.2026 © 2026 National Comprehensive Cancer Network® (NCCN©), All rights reserved. NCCN Guidelines® and this illustration may not be reproduced in any form without the express written permission of NCCN.

PLEASE NOTE that use of this NCCN Content is governed by the End-User License Agreement, and you MAY NOT distribute this Content or use it with any artificial intelligence model or tool.
Printed by Ling Lu on 6/26/2026 6:10:47 AM. Copyright © 2026 National Comprehensive Cancer Network, Inc. All Rights Reserved.

associated with improved RFS in male patients and those aged >40 years, although female patients and those aged <40 years who received adjuvant chemotherapy had marginally worse OS. However, RFS and OS were significantly improved in patients with R1 resection who received adjuvant chemotherapy compared with those who did not.

Long-term follow-up results of another prospective randomized study also showed that postoperative chemotherapy with IFADIC (ifosfamide, dacarbazine, and doxorubicin) given every 14 days with growth factor support did not result in significant benefit in terms of RFS (39% for IFADIC and 44% for the control group; *P* = .87) as well as OS (*P* = .99) for patients with grade 2 or 3 STS.[91]

Advanced, Unresectable, or Metastatic Disease

Chemotherapy with single agents (dacarbazine, doxorubicin, epirubicin, or ifosfamide) or anthracycline-based combination regimens (doxorubicin or epirubicin with ifosfamide and/or dacarbazine) have been widely used for patients with advanced, unresectable, or metastatic disease.[94-106] Other chemotherapeutic agents such as gemcitabine, docetaxel, vinorelbine, pegylated liposomal doxorubicin, and temozolomide have also been evaluated in clinical trials. The recently published METASARC observational study, which explored “real-world” outcomes among 2225 patients with metastatic STS, found a positive association of OS with front-line combination chemotherapy, LMS histology, and locoregional treatment of metastases. However, with the exception of LMS, the benefits of systemic therapy beyond the second-line setting were very limited.[107]

Gemcitabine in combination with docetaxel, vinorelbine, or dacarbazine has been shown to be active in patients with unresectable or metastatic STS of various histologic subtypes.[108-112] In a randomized phase II study, the combination of gemcitabine and docetaxel was associated with superior progression-free survival (PFS) (6.2 months and 3.0 months, respectively) and OS (17.9 months and 11.5 months, respectively) compared to gemcitabine alone in patients with metastatic STS.[109] In another phase II study, the combination of gemcitabine and vinorelbine was also associated with clinically meaningful rates of disease control in patients with advanced STS.[110] Clinical benefit (complete response [CR], partial response [PR], or stable disease at 4 months or more) was seen in 25% of patients. The combination of gemcitabine and dacarbazine resulted in superior PFS (4.2 months vs. 2 months; *P* = .005), OS (16.8 months vs. 8.2 months; *P* = .014), and objective response rate (49% vs. 25%; *P* = .009) compared to dacarbazine alone in patients with previously treated advanced STS.[111]

However, gemcitabine combination therapy was not superior to single-agent doxorubicin in the randomized phase III GeDDiS trial. Among patients with previously untreated advanced or metastatic disease (n = 257), combination therapy with gemcitabine and docetaxel did not result in superior PFS compared with doxorubicin (23.7 weeks vs. 23.3 weeks, *P* = .06).[112]

Temozolomide,[113-115] pegylated liposomal doxorubicin,[116] and vinorelbine[117,118] have also shown activity as single agents in patients with advanced, metastatic, relapsed, or refractory disease. In a phase II study by the Spanish Group for Research on Sarcomas, temozolomide resulted in an overall response rate of 15.5% with a median OS of 8 months in patients with advanced pretreated STS.[115] The PFS rates at 3 months and 6 months were 39.5% and 26%, respectively. In a prospective randomized phase II study, pegylated liposomal doxorubicin had equivalent activity and improved toxicity profile compared to doxorubicin; response rates were 9% and 10% for doxorubicin and pegylated liposomal doxorubicin, respectively, in patients with advanced or metastatic STS.[116] In a retrospective study of pretreated patients with metastatic STS, vinorelbine induced overall response in 6% of patients and 26% had stable disease.[117]

Discussion Update in progress

Version 3.2026 © 2026 National Comprehensive Cancer Network® (NCCN©), All rights reserved. NCCN Guidelines® and this illustration may not be reproduced in any form without the express written permission of NCCN.

PLEASE NOTE that use of this NCCN Content is governed by the End-User License Agreement, and you MAY NOT distribute this Content or use it with any artificial intelligence model or tool.
Printed by Ling Lu on 6/26/2026 6:10:47 AM. Copyright © 2026 National Comprehensive Cancer Network, Inc. All Rights Reserved.

Trabectedin is a novel DNA-binding agent that has shown objective responses in phase II and III studies of patients with advanced STS.[119-127] Recent phase III data from a randomized, multicenter trial revealed a 2.7-month PFS benefit versus dacarbazine in metastatic LPS or LMS that progressed after anthracycline-based therapy; the study is ongoing to determine OS.[125] Another recent study supported the efficacy of trabectedin in translocation-related sarcoma.[127] A phase III trial comparing trabectedin and doxorubicin-based chemotherapy revealed that neither arm showed superiority for PFS and OS; however, the trial was underpowered.[128] Preliminary results from the randomized phase III T-SAR trial revealed a PFS benefit for trabectedin over best supportive care in both "L-type" (LPS and LMS) and non–L-type pretreated advanced sarcoma.[129] However, trabectedin plus doxorubicin failed to demonstrate superiority over doxorubicin alone in a randomized phase II study of patients with advanced STS.[130] Trabectedin is included for palliative therapy as a category 1 recommendation for LPS and LMS (L-type) and as category 2A for non–L-type sarcomas.

Eribulin is a novel microtubule-inhibiting agent that has been evaluated as a single-agent therapy for STS, including LMS, adipocytic sarcoma, synovial sarcoma, and other tumor types.[131] Recent data from a phase III trial compared the survival benefit of eribulin and dacarbazine in 452 patients with advanced LMS or LPS, revealing a median OS of 13.5 months and 11.5 months, respectively (HR, 0.77; 95% CI, 0.62–0.95; P = .017).[132] Eribulin is included for palliative therapy as a category 1 recommendation for LPS.

Targeted Therapy

More recently, a number of targeted therapies have shown promising results in patients with certain histologic types of advanced or metastatic STS.

Pazopanib, a multitargeted tyrosine kinase inhibitor (TKI), has demonstrated single-agent activity in patients with advanced STS subtypes except LPS.[133-136] In a phase III study (EORTC 62072), 369 patients with metastatic non-lipogenic STS who had failed at least one anthracycline-based chemotherapy regimen were randomized to either pazopanib or placebo.[135] Pazopanib significantly prolonged median PFS (4.6 months vs.1.6 months for placebo; P < .0001) and there was also a trend toward improved OS (12.5 months and 11 months, respectively; P = .25), although it was not statistically significant. Health-related quality-of-life measures did not improve or decline with the PFS benefit.[137] Pooled data from individuals who received pazopanib in phase II and III trials (n = 344) revealed a subset of long-term responders/survivors presenting at baseline with good performance status, low-/intermediate-grade primary tumor, and normal hemoglobin level.[138] The guidelines have included pazopanib as an option for palliative therapy for patients with progressive, unresectable, or metastatic non-lipogenic STS.

Imatinib[139] and sunitinib[140,141] have also shown efficacy in patients with advanced and/or metastatic STS other than GIST. Sorafenib appeared to be active in a small cohort of patients with solitary fibrous tumor.[142] Crizotinib, an anaplastic lymphoma kinase (ALK) inhibitor, was active in inflammatory myofibroblastic tumor (IMT) with ALK translocation.[143] The updated guidelines also include ceritinib, a next-generation ALK inhibitor that has been successful in treating ALK-rearranged non-small cell lung cancer.[144]

mTOR inhibitors such as sirolimus, temsirolimus, and everolimus have also shown promising results in patients with metastatic perivascular epithelioid cell tumors (PEComas) and in patients with recurrent lymphangioleiomyomatosis or angiomyolipomas.[145-151] Additionally, sorafenib may be active in select subtypes of advanced and/or metastatic STS other than GIST (eg, LMS, desmoid tumors).[152,153]

Discussion update in progress

Version 3.2026 © 2026 National Comprehensive Cancer Network® (NCCN©), All rights reserved. NCCN Guidelines® and this illustration may not be reproduced in any form without the express written permission of NCCN.

PLEASE NOTE that use of this NCCN Content is governed by the End-User License Agreement, and you MAY NOT distribute this Content or use it with any artificial intelligence model or tool.
Printed by Ling Lu on 6/26/2026 6:10:47 AM. Copyright © 2026 National Comprehensive Cancer Network, Inc. All Rights Reserved.

Bevacizumab either alone or in combination with temozolomide was well tolerated and effective in patients with metastatic or locally advanced or recurrent epithelioid hemangiopericytoma and malignant solitary fibrous tumor.[154,155]

Palbociclib, an inhibitor of cyclin-dependent kinases (CDKs) 4 and 6, induced objective tumor response and a favorable PFS of 56% to 66% in patients with CDK-4–amplified, well-differentiated or dedifferentiated liposarcoma (WD/DDLS).[156,157]

The randomized, phase II REGOSARC trial examined regorafenib, an agent approved for treating GIST, in cohorts of patients with advanced LPS, LMS, synovial sarcoma, and other non-GIST STS subtypes (REGOSARC, n = 182).[158,159] Compared to placebo, regorafenib significantly extended PFS in all but the LPS cohort. In patients with nonadipocytic STS, overall PFS for regorafenib and placebo-treated patients was 4 months vs. 1 month (HR 0.36, $P < .0001$).

Soft Tissue Sarcomas of the Extremities, Superficial Trunk, or Head and Neck

Evaluation and Workup

The differential diagnosis of STS of the extremities includes ruling out desmoid tumors (aggressive fibromatosis), as well as the other malignant and benign lesions. An essential element of the workup is a history and physical (H&P) examination, imaging of the primary tumor and distant metastases, and a carefully planned biopsy (core needle or incisional biopsy). Adequate and high-quality imaging studies are crucial to good clinical management of patients, because the presence of metastatic disease may change the management of the primary lesion and the overall approach to the patient's disease management. The propensities to spread to various locations vary between the subtypes of sarcoma. Therefore, imaging should be individualized based on the subtype of sarcoma. Laboratory tests have a limited role.

Imaging studies should include cross-sectional imaging to provide details about tumor size and contiguity to nearby visceral structures and neurovascular landmarks. The panel recommends MRI with contrast, with or without CT with contrast. Other imaging studies such as CT angiogram and plain radiograph may be warranted in selected circumstances. Given the risk for hematogenous spread from a high-grade sarcoma to the lungs, imaging of the chest (CT without contrast [preferred] or x-ray) is essential for accurate staging. Abdominal/pelvic CT should be considered for angiosarcoma, LMS, myxoid/round cell LPS, or epithelioid sarcoma as well as STS without definitive pathology prior to final resection. MRI of the total spine should be considered for myxoid/round cell LPS due to the higher risk of metastasis to the spine compared to other STSs.[160-162] Alveolar soft part sarcoma has a relatively increased propensity to metastasize to the brain, especially in patients with stage IV disease in the presence of pulmonary metastases.[163] Central nervous system MRI (or CT if MRI is contraindicated) should be considered for patients with alveolar soft part sarcoma and angiosarcoma.

PET scans may be useful in staging, prognostication, grading, and determining histopathologic response to chemotherapy.[164-169] The maximum standardized uptake value (SUVmax) of F18-deoxyglucose has been shown to correlate with tumor grade and prognostication.[170,171] In a retrospective study, tumor SUVmax determined by PET was an independent predictor of survival and disease progression.[164] Schuetze and colleagues reported that the pretreatment SUVmax and change in SUVmax after preoperative chemotherapy independently identified patients with a high risk of recurrence.[165] Patients with a change in the SUVmax of 40% or more in response to chemotherapy were at a significantly lower risk of recurrence and death after complete resection

Discussion update in progress

Version 3.2026 © 2026 National Comprehensive Cancer Network® (NCCN©), All rights reserved. NCCN Guidelines® and this illustration may not be reproduced in any form without the express written permission of NCCN.

PLEASE NOTE that use of this NCCN Content is governed by the End-User License Agreement, and you MAY NOT distribute this Content or use it with any artificial intelligence model or tool.
Printed by Ling Lu on 6/26/2026 6:10:47 AM. Copyright © 2026 National Comprehensive Cancer Network, Inc. All Rights Reserved.

and postoperative RT; the projected 5-year RFS rate for this group of patients was 80% compared to 40% for those with a less than 40% reduction in SUVmax.[165] PET was useful in the early assessment of response to preoperative chemotherapy and was also significantly more accurate than the RECIST criteria in the assessment of histopathologic response to preoperative chemotherapy.[167,168] In a prospective study of 50 patients with resectable, high-grade STS, a 35% reduction in the SUV after first cycle of chemotherapy was a sensitive predictor of histopathologic response.[168] The value of combined PET/CT in predicting DFS in patients receiving preoperative chemotherapy for STS is being evaluated in an ongoing large prospective study.

Based on the initial workup, the patients are assigned to one of the following categories:

- Stage I
- Stage II-III
- Unresectable disease
- Stage IV (Synchronous Metastatic Disease)
- Recurrent disease

General Principles of Treatment

Surgery

Positive surgical margin is a strong predictor of LR for patients with extremity STS.[172-177] Microscopically positive margins are associated with a higher rate of LR and a lower rate of DFS in patients with extremity sarcomas.[172,173,175] In a large cohort study (1668 patients) that examined the clinical significance of the main predictors of LR in patients with STS of extremity and trunk, the 10-year cumulative possibility of LR was significantly higher for patients with positive surgical margins (23.9 vs. 9.2 for those with negative margins; $P < .001$).[176] In a recent retrospective study that evaluated 278 patients with STS of the extremities treated between 2000 and 2006, patients with a positive margin were 3.76 times more likely to develop LR than those with negative margins (38% risk of LR after 6 years if the margins were positive compared to 12% if the margins were negative).[177] Careful preoperative planning by an experienced sarcoma surgical team may enable anticipated planned positive margins in order to save critical structures without affording a worse oncologic outcome.[43]

Amputation was once considered the standard treatment to achieve local control in patients with extremity sarcomas.[178] Technical advances in reconstructive surgical procedures, implementation of multimodality therapy, and improved selection of patients for adjuvant therapy have minimized the functional deficits in patients who might otherwise require amputation. In 1982, a randomized control study of 43 patients showed that limb-sparing surgery with RT was an effective treatment in patients with high-grade STS of the extremities, with a LR rate of 15% and no difference in OS and DFS as compared to amputation.[179] In another series of 77 patients treated with limb-sparing surgery without RT, the LR rate was only 7% and resection margin status was a significant predictor of LR.[180] The LR rate was 13% when the resection margin was 1 cm or less as compared to 0% when the resection margin was 1 cm or more. In a retrospective study of 115 patients with an STS of hand or foot, radical amputation as an initial treatment did not decrease the probability of regional metastasis and also did not improve the disease-specific survival.[181]

Collectively, the data suggest that limb-sparing surgery with or without postoperative RT is an effective treatment option for extremity STS and amputation should be reserved only for cases where resection or reresection with adequate margins cannot be performed without sacrificing the functional outcome. The guidelines recommend that the goal of surgery for patients with STS of extremities should be functional limb

Discussion update in progress

Version 3.2026 © 2026 National Comprehensive Cancer Network® (NCCN©), All rights reserved. NCCN Guidelines® and this illustration may not be reproduced in any form without the express written permission of NCCN.

PLEASE NOTE that use of this NCCN Content is governed by the End-User License Agreement, and you MAY NOT distribute this Content or use it with any artificial intelligence model or tool.
Printed by Ling Lu on 6/26/2026 6:10:47 AM. Copyright © 2026 National Comprehensive Cancer Network, Inc. All Rights Reserved.

preservation, if possible, within the realm of an appropriate oncologic resection. Limb-sparing surgery is recommended for most patients with STS of extremities to achieve local tumor control with minimal morbidity. Amputation may improve local control in patients who might not be candidates for limb-sparing surgery and it should be considered with patient preference, or if the gross total resection of the tumor is expected to render the limb nonfunctional.[182-185] Prior to considering amputation, the patient should be evaluated by a surgeon with expertise in the treatment of STS. Evaluation for postoperative rehabilitation is recommended for all patients with extremity sarcoma. If indicated, rehabilitation should be continued until maximum function is achieved.

Radiation Therapy

Data from randomized studies[63,186,187] and retrospective analyses[59,188-191] support the use of preoperative or postoperative EBRT in appropriately selected patients. Brachytherapy (alone or in combination with EBRT)[188,192,193] and IMRT[194,195] have also been evaluated as an adjunct to surgery.

Preoperative vs. Postoperative EBRT

Various studies have examined the benefits and risks for preoperative and postoperative RT approached for treating STS of the extremity, head and neck, or superficial trunk.

Recently, examination of data from 27,969 patients with extremity STS in the NCDB identified both preoperative and postoperative RT as factors associated with increased OS.[191] However, that data showed that preoperative RT was predictive of achieving R0 resection.[191] In a phase III randomized study conducted by the Canadian Sarcoma Group, local control and PFS rates were similar in patients receiving either preoperative or postoperative RT in patients with localized primary or recurrent disease.[187,196] However, preoperative RT was associated with a greater incidence of acute wound complications (35% vs.17% for postoperative RT), especially in lower extremity tumors (43% vs. 5% for upper extremity tumors). Late-treatment–related side effects were more common in patients receiving postoperative RT, which is believed to be related to the higher RT dose (66 Gy vs. 50 Gy for preoperative RT) and the larger treatment volume.[54,187]

The efficacy of postoperative EBRT following limb-sparing surgery was demonstrated in a prospective randomized study (91 patients with high-grade lesions and 51 patients with low-grade lesions).[186,197] Postoperative RT significantly reduced the 10-year LR rate among patients with high-grade lesions (no LRs in patients who underwent surgery plus RT vs. 22% in those who underwent surgery alone; P = .0028). Among patients with low-grade lesions, the corresponding recurrence rates were 5% and 32%, respectively.[186] The probability of reduction in the LR rate in patients receiving EBRT was not significant in patients with low-grade lesions, suggesting postoperative RT after limb-sparing surgery may not be necessary for this group of patients. Outcomes at 20-year follow-up favored patients who received EBRT, but differences were not statistically significant. Ten-year OS was 82% and 77% for patients who received surgery alone versus surgery plus EBRT, and 20-year OS was 71% and 64% for these groups, respectively (P = .22).[197]

The French Sarcoma Group recently reported on a cohort of 283 patients with resectable atypical lipomatous tumor (ALT)/WDLS of the extremity or superficial trunk from the Conticabase database. In these patients, postoperative RT significantly improved 5-year local RFS (98.3% vs. 80.3%, with and without adjuvant RT, respectively; P < .001).[198] Along with RT, tumor site and resection margin status were predictors of time to LR, but no difference in OS was observed.

In a report from the Memorial Sloan Kettering Cancer Center (MSKCC) that reviewed the long-term outcomes of 200 patients treated with

Discussion update in progress

Version 3.2026 © 2026 National Comprehensive Cancer Network® (NCCN©), All rights reserved. NCCN Guidelines® and this illustration may not be reproduced in any form without the express written permission of NCCN.

PLEASE NOTE that use of this NCCN Content is governed by the End-User License Agreement, and you MAY NOT distribute this Content or use it with any artificial intelligence model or tool.
Printed by Ling Lu on 6/26/2026 6:10:47 AM. Copyright © 2026 National Comprehensive Cancer Network, Inc. All Rights Reserved.

limb-sparing surgery, pathologically negative re-resection without RT was associated with a 5-year overall LR rate of 9%, at a median follow-up of 82 months.[199] Old age and/or stage III disease were associated with a higher rate of LR. Therefore, treatment decisions regarding the use of postoperative RT should be individualized and should not be solely based on the findings of margin-negative re-resection.

Brachytherapy

In a prospective randomized study, 164 patients with completely resected STS of the extremity or superficial trunk were randomized intraoperatively to receive either brachytherapy or no brachytherapy.[192] With a median follow-up time of 76 months, the 5-year local control rates were 82% and 69% in the brachytherapy and no brachytherapy groups, respectively. Patients with high-grade lesions who received brachytherapy had higher local control rates compared to those who received no brachytherapy (89% and 66%, respectively). However, brachytherapy had no impact on local control in patients with low-grade lesions. The 5-year freedom-from-distant-recurrence rates were 83% and 76%, respectively, in the two groups. In a retrospective analysis of 202 adult patients with primary high-grade STS of the extremity, brachytherapy following limb-sparing surgery resulted in lower rates of wound complications, favorable 5-year local control, and distant RFS and OS rates (84%, 63%, and 70%, respectively).[193]

IMRT

In a retrospective analysis of 41 patients with STS of extremity treated with limb-sparing surgery, postoperative IMRT resulted in a 5-year local control rate of 94% in patients with negative as well as positive or close margins, in selected patients with high-risk features.[194] The risk of complications such as edema and joint stiffness were also favorable when compared with conventional RT. In a more recent phase II study, O'Sullivan and colleagues reported that preoperative IMRT resulted in lower wound complication rate in patients with high-grade lesions (30.5% vs. 43% reported in earlier study using conventional EBRT).[200] In a nonrandomized comparison of IMRT and brachytherapy in patients with high-grade, primary, nonmetastatic STS of extremity, local control was significantly better with IMRT than brachytherapy (5-year local control rates were 92% and 81%, respectively; $P = .04$) despite higher rates of adverse features for IMRT.[195]

IORT

Recent reports from a retrospective study suggest that IORT provides excellent local control to STS of the extremity.[201,202] Call and colleagues recently reported long-term outcome of patients with STS of upper extremity treated with EBRT, surgery, and IORT. The 10-year local control and OS rates were 88% and 58%, respectively.[202] The 10-year local control rates were 89% and 86%, respectively, following margin-negative (R0) and margin-positive (R1 and R2) resections. IORT was also retrospectively examined in cohorts of patients with STS of the superficial trunk or extremity who received surgery, IORT, and EBRT at 3 Spanish institutions.[203,204] Five-year IORT in-field control was 86% and 70% for extremity and trunk wall STS, respectively. However, 5-year DFS was 62% in the extremity STS cohort and 45% in the trunk wall STS. Incomplete resection significantly impacted in-field control in both cohorts, and higher IORT dose was positively associated with in-field disease control in extremity STS.

Although the use of IMRT and IORT has resulted in excellent clinical outcomes, their efficacy needs to be confirmed in larger cohorts of patients with longer follow-up. Additionally, image guidance may continue to improve RT outcomes for patients with STS of the extremity. In a recent phase II trial (RTOG-0630; n = 86), the use of preoperative image-guided RT to a reduced target volume resulted in significantly reduced late toxicity

Discussion Update in Progress

Version 3.2026 © 2026 National Comprehensive Cancer Network® (NCCN®), All rights reserved. NCCN Guidelines® and this illustration may not be reproduced in any form without the express written permission of NCCN.

PLEASE NOTE that use of this NCCN Content is governed by the End-User License Agreement, and you MAY NOT distribute this Content or use it with any artificial intelligence model or tool.
Printed by Ling Lu on 6/26/2026 6:10:47 AM. Copyright © 2026 National Comprehensive Cancer Network, Inc. All Rights Reserved.

without any marginal field recurrences.[51] Additional studies will be required.

Panel Recommendations

When EBRT is used, sophisticated treatment planning with IMRT, tomotherapy, and/or proton therapy can be used to improve therapeutic effect. RT is not a substitute for definitive surgical resection with negative margins, and re-resection to negative margins is preferable.

The usual dose of preoperative RT is 50 Gy in 1.8 to 2.0 Gy per fraction. If the patient has not previously received RT, one could attempt to control microscopic residual disease with postoperative RT if re-resection is not feasible. If wide margins are obtained, postoperative RT may not be necessary. For patients treated with preoperative RT followed by surgery, the guidelines recommend consideration of observation in addition to postoperative RT boost for patients with positive margins. There are data to suggest that boost for positive margins does not improve local control.[65,205] Given no clear evidence to suggest added benefit, the panel recommends that the decision to provide boost be individualized with careful consideration of potential toxicities.

The recommended EBRT boost doses are 16 to 18 Gy for microscopic residual disease, and 20 to 26 Gy for macroscopic residual disease. Brachytherapy boosts should be delivered several days after surgery, through catheters placed at operation, with doses of 16 to 26 Gy for LDR brachytherapy and 14 to 24 Gy for HDR brachytherapy, based on the margin status. Alternatively, IORT (10–12.5 Gy for microscopic residual disease and 15 Gy for gross residual disease) can be delivered immediately after resection to the area at risk, avoiding the uninvolved organs.[201]

For patients who have not received preoperative RT, the postoperative choices include EBRT (50 Gy irrespective of surgical margins in 1.8–2.0 Gy per fraction), IORT (10–16 Gy followed by 50 Gy EBRT), or brachytherapy. The guidelines recommend 45 Gy LDR brachytherapy or HDR equivalent for patients with negative margins. LDR brachytherapy (16–20 Gy) or HDR equivalent is recommended for patients with positive margins followed by EBRT. EBRT following IORT or brachytherapy is delivered to the target volume to a total dose of 50 Gy, after surgical healing is complete (3–8 weeks).

For patients treated with postoperative EBRT, the guidelines recommend an additional EBRT boost (unless prior IORT) to the original tumor bed based on the margin status (10–16 Gy for negative surgical margin; 16–18 Gy for microscopic residual disease; and 20–26 Gy for grossly positive margins). However, many institutions are no longer giving a boost after preoperative RT to patients who have widely negative margins, based on local control rates approaching 95% with preoperative RT at 50 Gy and negative margins. The panel also emphasizes that RT is not a substitute for suboptimal surgical resection and re-resection is preferred for patients with positive surgical margins.

Treatment Guidelines by Stage

Stage I

Surgical wide resection (with intent to obtain negative margins) is the primary treatment for stage IA (T1, N0, M0, low grade) and IB (T2-4, N0, M0, low grade) tumors and is considered definitive if margins are greater than 1 cm or the fascial plane is intact.[206,207] If the surgical margins are 1.0 cm or less and without an intact fascial plane, re-resection may be necessary.[199] Treatment options including revision surgery versus observation should be presented at an experienced multidisciplinary sarcoma tumor board to determine advantages and disadvantages of the decision.

Discussion update in progress

Version 3.2026 © 2026 National Comprehensive Cancer Network® (NCCN©), All rights reserved. NCCN Guidelines® and this illustration may not be reproduced in any form without the express written permission of NCCN.

PLEASE NOTE that use of this NCCN Content is governed by the End-User License Agreement, and you MAY NOT distribute this Content or use it with any artificial intelligence model or tool.
Printed by Ling Lu on 6/26/2026 6:10:47 AM. Copyright © 2026 National Comprehensive Cancer Network, Inc. All Rights Reserved.

Data from prospective studies support the use of RT as an adjunct to surgery in appropriately selected patients based on an improvement in DFS although not OS.[173,175,192] Postoperative RT is recommended for patients with final surgical margins of 1.0 cm or less and without an intact fascial plane (category 2B for stage IA tumors and category 1 for stage IB). RT may not be necessary in patients with small low-grade lesions (5 cm or less), because these tumors are less frequently associated with LR.[186] Therefore, observation is included as an option for patients with stage IA disease with final surgical margins of 1.0 cm or less and with an intact fascial plane.

En bloc resection with negative margins is generally sufficient to obtain long-term local control in patients with ALT/WDLS; RT is not indicated in most cases.[208,209] In one report that reviewed 91 patients with ALT/WDLS of the extremity and trunk, positive surgical margins were associated with reduced local RFS, suggesting that function-preserving re-resection when possible or adjuvant RT could be considered for selected patients with positive surgical margins.[210] RT may also be an appropriate treatment option for selected patients with recurrent disease or deeply infiltrative primary lesions with a risk of LR, depending on the tumor location and patient's age.[211]

Stage II-III

Treatment options should be decided by a multidisciplinary team with extensive experience in the treatment of patients with STS, based on the patient's age, performance status, comorbidities, location, and histologic subtype of the tumor.

Preoperative chemoradiation has been shown to improve OS, DFS, and local control rates in patients with high-grade STS of extremity and trunk, although acute reactions must be considered.[77,78] An earlier randomized study showed that preoperative chemotherapy was not associated with a major survival benefit for patients with high-grade tumors.[68] Histotype-specific neoadjuvant chemotherapy was examined in a recent international RCT of patients with high-risk STS (n = 287; ISG-STS 1001).[71] Standard neoadjuvant chemotherapy (epirubicin/ifosfamide) was compared with histotype-specific regimens for myxoid LPS (trabectedin), LMS (gemcitabine/dacarbazine), synovial sarcoma (high-dose ifosfamide), MPNST (etoposide/ifosfamide), and UPS (gemcitabine/docetaxel). At 46 months, DFS was 62% for standard chemotherapy versus 38% for the histotype-tailored regimens (HR, 2.00; 95% CI, 1.22–3.26; *P* = .006). Trial enrollment was closed due to futility.

The results of a recent phase III randomized study (EORTC 62961) showed that regional hyperthermia (RHT) increases the benefit of preoperative chemotherapy in patients with localized high-risk STS.[212] In this study, 341 patients were randomized to receive either preoperative chemotherapy with etoposide, ifosfamide, and doxorubicin (EIA) alone, or combined with RHT (EIA plus RHT). After a median follow-up of 34 months, among 149 patients with STS of the extremity, the 2-year DFS and local PFS rates were 70% and 92%, respectively, for patients treated with EIA plus RHT. The corresponding survival rates were 57% and 80% for those treated with EIA alone. However, these results need to be confirmed in large cohort studies and the use of RHT with preoperative chemotherapy is not recommended in the guidelines.

Available evidence, although underpowered, suggests that anthracycline-based postoperative chemotherapy (now most commonly given as doxorubicin and ifosfamide or epirubicin and ifosfamide) would improve DFS in selected patients with good performance status who are at high risk of recurrence.[87-91] Preoperative or postoperative EBRT has been shown to improve local control in patients with high-grade lesions.[53,186,188]

Large stage II or III high-grade extremity resectable tumors (greater than 8–10 cm) that are at high risk for LR and metastases should be considered for preoperative and postoperative therapy. However, there

Version 3.2026 © 2026 National Comprehensive Cancer Network® (NCCN®), All rights reserved. NCCN Guidelines® and this illustration may not be reproduced in any form without the express written permission of NCCN.

PLEASE NOTE that use of this NCCN Content is governed by the End-User License Agreement, and you MAY NOT distribute this Content or use it with any artificial intelligence model or tool.
Printed by Ling Lu on 6/26/2026 6:10:47 AM. Copyright © 2026 National Comprehensive Cancer Network, Inc. All Rights Reserved.

are data supporting that surgery alone is an adequate treatment option in selected patients with high-grade lesions. Long-term results of a prospective study demonstrated that selected patients with high-grade T1 lesions can be treated by surgery alone (R0 resection) with acceptable local control and excellent long-term survival.[213] In the surgery alone arm, the cumulative incidence rates of LR at 5 and 10 years were 7.9% and 10.6%, respectively, in patients who underwent R0 resection, and the 5- and 10-year sarcoma-specific death rates were 3.2%. In an analysis of 242 patients with localized STS of the trunk and extremity treated with limb-sparing surgery, the 10-year local control rate was 87% to 93% for patients with resection margins of less than 1 cm compared with 100% for those with resection margins of 1 cm or more (P = .04).[180] Al-Refaie and colleagues also reported that the addition of RT did not result in any significant difference in OS or sarcoma-specific survival in patients with early-stage STS of the extremity.[214]

Surgery preceded or followed by RT is recommended for patients with stage II tumors (T1, N0, M0, G2-3) that are resectable with acceptable functional outcomes (category 1 for preoperative or postoperative RT).[186,187,196] Surgery alone may be an option for patients with small tumors that can be resected with wider surgical margins.

Surgery followed by RT (category 1) with or without postoperative chemotherapy is the primary treatment for patients with stage IIIA (T2, N0, M0, G2-3) or IIIB (T3-4, N0, M0, G2-3) tumors that are resectable with acceptable functional outcomes. The impact of RT was analyzed in a SEER cohort of 2606 patients with stage III soft-tissue extremity sarcoma. Similarly to smaller prospective studies and reviews, RT was associated with a significant 5-year survival benefit (65% vs. 60%, P = .002). However, the timing of RT (ie, preoperative vs. postoperative) was not a significant factor for survival.[215] Since there are only limited and conflicting data regarding the potential benefits of postoperative chemotherapy for stage II or III patients, postoperative chemotherapy is included as a category 2B recommendation.[87-91] Preoperative RT (category 1), preoperative chemotherapy (category 2B), or chemoradiation (category 2B) are also included as options for this group of patients.

Radical lymphadenectomy may provide long-term survival benefit for patients with isolated lymph node involvement. In a study that examined the natural history of lymph node metastasis in patients with STS, the median survival was 4.3 months for patients not treated with radical lymphadenectomy compared to 16.3 months in patients who underwent radical lymphadenectomy.[216] The 5-year survival rate for the latter group of patients was 46%. The guidelines recommend regional lymph node dissection at the time of primary surgery for patients with stage III tumors with lymph node involvement.

Patients with stage II or III tumors that are resectable with adverse functional outcomes should be managed as described below for unresectable disease.

Unresectable Disease

Patients with unresectable tumors can be treated primarily with RT, chemoradiation, chemotherapy, or regional limb therapy. Tumors that become resectable with acceptable functional outcomes following primary treatment can be treated with surgery followed by RT (if not previously irradiated) with or without postoperative chemotherapy. Since there are only limited and conflicting data regarding the potential benefits of postoperative chemotherapy, it is included as a category 2B recommendation. For patients whose tumors remain resectable with adverse functional outcomes or unresectable following primary treatment, a subsequent distinction is made between asymptomatic and symptomatic patients. Observation is an option for asymptomatic patients. For symptomatic patients, the treatment options include chemotherapy, palliative surgery, amputation, or best supportive care.

Discussion update in progress

Version 3.2026 © 2026 National Comprehensive Cancer Network® (NCCN©), All rights reserved. NCCN Guidelines® and this illustration may not be reproduced in any form without the express written permission of NCCN.

PLEASE NOTE that use of this NCCN Content is governed by the End-User License Agreement, and you MAY NOT distribute this Content or use it with any artificial intelligence model or tool.
Printed by Ling Lu on 6/26/2026 6:10:47 AM. Copyright © 2026 National Comprehensive Cancer Network, Inc. All Rights Reserved.

A randomized phase III trial examining intensified doxorubicin plus ifosfamide versus doxorubicin alone did not find an OS benefit for combination therapy in patients with unresectable, advanced, or metastatic STS (14.3 months vs. 12.8 months; *P* = .076). However, response rates and PFS were improved for doxorubicin/ifosfamide compared with doxorubicin alone (26% vs. 14%, *P* = .0006; 7.4 months vs. 4.6 months, *P* = .003).[217] However, subset analyses (n = 310) indicated an OS benefit for doxorubicin/ifosfamide versus single-agent doxorubicin in patients with UPS.[218]

Definitive RT (70–80 Gy) can be considered for selected patients with unresectable tumors following primary treatment. In a single-institution study (112 patients, 43% extremity STS) tumor size and the dose of RT influenced local control and survival in patients with unresectable STS.[219] The local control rate was 51% for tumors less than 5 cm and 9% for tumors greater than 10 cm. Patients who received 63 Gy or more had better 5-year local control, DFS, and OS rates (60%, 36%, and 52%, respectively) compared to patients who received less than 63 Gy (22%, 10%, and 14%, respectively). Local control for patients receiving more than 63 Gy was 72% for lesions 5 cm or less, 42% for lesions 5 to 10 cm, and 25% for lesions more than 10 cm.

Regional limb therapy (isolated limb perfusion [ILP] and isolated limb infusion [ILI]) has been evaluated as a limb-sparing treatment for unresectable intermediate or high-grade extremity STS. ILP requires the use of tumor necrosis factor-α (TNF-α) along with chemotherapy, which is not approved in the United States. ILI is a less invasive alternative to ILP for patients with unresectable STS of the extremities and can be used without TNF-α. Data from clinical trials suggest that ILP with melphalan or doxorubicin in combination with TNF-α[220-223] or ILI with doxorubicin or melphalan and dactinomycin[224-228] may be effective in the treatment of patients with unresectable STS of extremity.[229] Further prospective clinical trials are needed to better define the role for ILP or ILI in the management of patients with unresectable STS of the extremity.[229] The panel recommends that ILP for isolated regional or nodal disease be accompanied by surgical resection. ILP for recurrent disease should only be performed at institutions with experience in regional limb therapy.

Stage IV (Synchronous Metastatic Disease)

Patients with metastatic stage IV disease (any T, N1, M0, any G; or any T, any N, M1, any G) have a poor prognosis with no disease-free interval.[230,231] Conflicting data exist on the potential survival benefit of metastasectomy. In a retrospective study of 48 patients with synchronous metastases, there was no improvement in OS for patients treated with metastasectomy compared to those with unresectable disease.[230] In a more recent retrospective study involving 112 patients with metastatic disease at presentation, resection of metastatic disease, less than 4 pulmonary metastases, and the presence of lymph node metastases vs. pulmonary metastases were identified as statistically significant variables for improved OS. The 5-year survival rate was 59% and 8%, respectively, for patients presenting with lymph node metastases and pulmonary metastases.[231] Pulmonary metastasectomy resulted in a median OS of 25.5 months in a retrospective analysis of 66 patients with sarcoma; however, recurrent metastasis was associated with poor prognosis.[232] Although recurrence is common after initial metastasectomy, data from a prospective review (n = 539) suggested a potential survival benefit for repeat pulmonary metastasectomy in appropriately selected patients.[233]

Since there are no data to support the optimal management of patients presenting with metastatic disease, the guidelines are intentionally nonspecific about the treatment options for this group of patients. Referral to a medical oncologist with extensive experience in the treatment of STS is recommended. Treatment options should be based on many factors, including performance status, patient preferences, specific clinical

Version 3.2026 © 2026 National Comprehensive Cancer Network® (NCCN©), All rights reserved. NCCN Guidelines® and this illustration may not be reproduced in any form without the express written permission of NCCN.

PLEASE NOTE that use of this NCCN Content is governed by the End-User License Agreement, and you MAY NOT distribute this Content or use it with any artificial intelligence model or tool.
Printed by Ling Lu on 6/26/2026 6:10:47 AM. Copyright © 2026 National Comprehensive Cancer Network, Inc. All Rights Reserved.

problems from the metastases, and treatment availability. In addition, clinical trial is the preferred treatment option for patients with metastatic disease.

Limited Metastases

Patients with limited metastasis confined to a single organ and limited tumor bulk that are amenable to local therapy should receive primary tumor management as described for stage II or III tumors. Another option is to consider metastasectomy with or without chemotherapy with or without RT. The guidelines do not specify rules governing metastasectomy, which remains controversial.[230,232,233] Several variables, including tumor resectability, number and location of metastases, and performance status influence the decision to use metastasectomy.[231] In addition, patients can also receive stereotactic body RT (SBRT) or chemotherapy as an alternate method for control of metastatic lesions. Several recent reviews and case series support the use of SBRT for local control, with potential survival benefits in selected patients.[234-236]

Disseminated Metastases

For patients presenting with disseminated disease, a subsequent distinction is made between asymptomatic and symptomatic patients. Observation with a “watchful waiting” strategy is a reasonable management option for asymptomatic patients, especially if patients have only a minimal burden of metastases (eg, sub-centimeter pulmonary nodules). Symptomatic patients can be treated with palliative RT, surgery, or chemotherapy. Palliative RT involves expedient treatment with sufficient dose to halt tumor growth or cause tumor regression. The outcome of this approach depends on the rapidity of growth and the status of systemic disease. In addition, the guidelines have included ablation procedures (eg, radiofrequency ablation [RFA] or cryotherapy) or SBRT as options for symptomatic patients.

Surveillance

Surveillance is deemed important to detect recurrences that might still be potentially curable. However, very limited data are available in the literature on effective surveillance strategies.[237-240] Because patient risk never returns to zero, long-term follow-up is indicated, including consideration of MRI or CT scan.[241] There has never been a study to prove that the use of more sensitive CT scans in routine surveillance would improve clinical outcomes. According to the report from MD Anderson Cancer Center, routine use of chest CT adds little clinical benefit when risk of pulmonary metastases is low.[242] However, in certain subsets of patients in whom chest radiographs are difficult to interpret because of anatomic considerations (eg, scarring, emphysema), chest CT may be indicated. A retrospective review examined surveillance imaging in 94 patients with intermediate or high-grade localized extremity/trunk STS who underwent radical resection and RT.[240] Thirty patients (32%) recurred after a median follow-up of 60 months (5 local, 26 distant). Surveillance imaging led to the detection of LR in 2 out of 5 cases and distant recurrence (lung) in 22 out of 26 cases. The authors concluded that surveillance chest imaging may be most useful for the detection of asymptomatic distant recurrence (ie, in the lung), while primary site imaging may only be useful for patients at high risk of LR.

Ultrasound has been used for the detection of early LRs and for the detection of micronodules less than 0.5 cm in diameter.[243-245] In a retrospective analysis that evaluated the value of MRI and ultrasound for the detection of LR after surgery in 21 patients with STS of extremities, the sensitivity of ultrasound was slightly higher than that of MRI (100% vs. 83%) and the specificity was slightly lower than that of MRI (79% vs. 93%).[243] However, the differences were not statistically significant, suggesting that both MRI and ultrasound were equally useful in the detection of LR after surgery. In a subsequent report, Arya and colleagues also reported that ultrasound is associated with high sensitivity and

Discussion update in progress

Version 3.2026 © 2026 National Comprehensive Cancer Network® (NCCN©), All rights reserved. NCCN Guidelines® and this illustration may not be reproduced in any form without the express written permission of NCCN.

PLEASE NOTE that use of this NCCN Content is governed by the End-User License Agreement, and you MAY NOT distribute this Content or use it with any artificial intelligence model or tool.
Printed by Ling Lu on 6/26/2026 6:10:47 AM. Copyright © 2026 National Comprehensive Cancer Network, Inc. All Rights Reserved.

specificity (92% and 94%, respectively) in the detection of early LR in patients with STS.[244] These results confirm that ultrasound can be useful for the detection of LR. However, as reported by Choi and colleagues, ultrasound may be more difficult to interpret than MRI during the early postoperative period.[243] Therefore, MRI should be used if ultrasound results are inconclusive.

The guidelines outline a prudent follow-up schedule by disease stage that avoids excessive testing. Higher grade and larger tumors have a higher risk of dissemination; therefore, the surveillance recommendations for patients with these tumors are somewhat more intensive, particularly for the first 3 years after resection. After 10 years, the likelihood of developing a recurrence is small and follow-up should be individualized.

Stage I tumors are routinely followed with H&P every 3 to 6 months for 2 to 3 years and then annually. Chest imaging is recommended every 6 to 12 months by CT [preferred] or x-ray. Postoperative baseline and periodic imaging of the primary tumor site is recommended based on estimated risk of locoregional recurrence. MRI with and without contrast and/or CT with contrast is recommended; ultrasound can be considered for the detection of LR in patients with smaller, superficial lesions and should be performed by an ultrasonographer with experience in musculoskeletal disease.[243,244] However, in situations where the area is easily followed by physical examination, imaging may not be required.[246]

For stage II/III and synchronous stage IV disease, postoperative re-imaging using MRI with and without contrast (preferred) or CT with contrast should be used to assess the primary tumor site and rule out metastatic disease. Baseline and periodic imaging of the primary site are recommended based on risk of locoregional recurrence; ultrasound can be considered for small, superficial lesions. H&P and imaging of the chest and other known sites of metastatic disease should be performed every 2 to 6 months for 2 to 3 years, then every 6 months for the next 2 years, and then annually.

Recurrent Disease

The management of recurrent disease encompasses a heterogeneous group of patients and clinical scenarios. In retrospective studies, isolated LR at sites other than the head and neck and deep trunk, resectability of recurrent and metastatic disease, disease-free interval, and number of metastases were identified as important predictive factors for long-term survival.[247-249]

For a patient with a LR, treatment decisions should be made using the same algorithm as for patients with a new primary lesion.[250] In patients with LR, some case series suggest that combined conservative surgery and re-irradiation provide superior local control compared to local re-excision alone.[251] However, others have reported that conservative surgery alone results in local control in a minority of patients with locally recurrent disease after previous excision and EBRT,[252] likely reflecting differences in patient selection for surgery and RT or surgery alone. Therefore, the guidelines recommend that if LR can be excised, a decision regarding the use of re-irradiation will need to be made on a case-by-case basis. Traditionally, the re-irradiation has been done with postoperative brachytherapy, but now brachytherapy may be used in combination with IMRT to reduce the risks of morbidity with re-irradiation.

For patients with metastatic recurrences the guidelines distinguish between limited metastases confined to a single organ, disseminated metastases, and isolated regional disease with nodal involvement. The treatment options for patients with limited metastases confined to a single organ or disseminated metastases are similar to that described for stage IV disease at presentation. In patients with isolated regional disease or nodal involvement, options include: 1) regional node dissection with or without RT or chemotherapy; 2) metastasectomy with or without pre- or

Discussion update in progress

Version 3.2026 © 2026 National Comprehensive Cancer Network® (NCCN©), All rights reserved. NCCN Guidelines® and this illustration may not be reproduced in any form without the express written permission of NCCN.

PLEASE NOTE that use of this NCCN Content is governed by the End-User License Agreement, and you MAY NOT distribute this Content or use it with any artificial intelligence model or tool.
Printed by Ling Lu on 6/26/2026 6:10:47 AM. Copyright © 2026 National Comprehensive Cancer Network, Inc. All Rights Reserved.

postoperative chemotherapy and/or RT; 3) SBRT; or 4) ILP/ILI with surgery. Limited data are available on the use of chemotherapy in patients undergoing metastasectomy. Results from a recent retrospective analysis suggest that chemotherapy has minimal impact on the survival of patients with metastatic extremity STS undergoing pulmonary metastasectomy.[253]

Retroperitoneal/Intra-abdominal Soft Tissue Sarcomas

Evaluation and Workup

The initial evaluation and workup for retroperitoneal/intra-abdominal STS (see RETSARC-1) are similar to that for the extremity sarcomas. This workup involves a thorough history and physical examination (H&P) and appropriate imaging studies. CT is the preferred imaging modality, although MRI can also be utilized in certain situations. Chest imaging should be performed for histologies that have the potential for lung metastases. If possible, a multidisciplinary sarcoma panel should review the patient.

The differential diagnosis of retroperitoneal/intra-abdominal soft tissue mass includes malignant lesions (such as other sarcomas, GIST, lymphomas, or germ cell tumors), desmoids, and benign lesions. Pre-resection biopsy is not necessary for all patients. However, confirmation of a sarcoma diagnosis (including histologic subtype) is required for patients being considered for neoadjuvant therapy. Image-guided (CT or ultrasound) core needle biopsy is preferred over open surgical biopsy, and should be performed if neoadjuvant therapy is being considered or for suspicion of malignancy other than sarcoma. The goal of this strategy is to avoid inappropriate major resection of another tumor, such as an intra-abdominal lymphoma or germ cell tumor. If a retroperitoneal STS is encountered unexpectedly when a laparotomy is performed for some other reason, a core needle biopsy should be done to establish the diagnosis as well as the histopathologic type and grade of tumor. Then, the optimal subsequent resection could be performed at a center with sarcoma expertise.

For additional information on the *Principles of Pathologic Assessment of Sarcoma Specimens*, please refer to SARC-B.

Radiation Therapy

RT can be administered either as neoadjuvant treatment for patients with resectable disease or as a primary treatment for those with unresectable disease. In general, the panel discourages adjuvant RT for retroperitoneal/intra-abdominal STS except for highly selected cases where local recurrence (LR) would cause undue morbidity. The panel emphasizes that RT is not a substitute for definitive surgical resection with oncologically appropriate margins and re-resection may be necessary. If re-resection is not feasible, adjuvant RT may be considered in highly selected patients, who have not received neoadjuvant RT, to attempt to control microscopic residual disease; however, this approach has not been validated in randomized trials and may be associated with toxicity, given the predilection for normal bowel to occupy the void left by resection of the sarcoma.

Newer RT techniques such as intensity-modulated RT (IMRT) and protons may allow tumor target coverage and acceptable clinical outcomes within normal tissue dose constraints to adjacent organs at risk.[190,254-257] When external beam RT (EBRT) is used, sophisticated treatment planning with IMRT, image-guided RT (IGRT), and/or proton therapy can be used to improve therapeutic effect. However, the safety and efficacy of adjuvant RT techniques have yet to be evaluated in multicenter randomized controlled studies.

Neoadjuvant RT

If radiation is being considered for highly selected cases as part of the multimodality therapy for retroperitoneal/intra-abdominal STS, a

Discussion update in progress

Version 3.2026 © 2026 National Comprehensive Cancer Network® (NCCN©), All rights reserved. NCCN Guidelines® and this illustration may not be reproduced in any form without the express written permission of NCCN.

PLEASE NOTE that use of this NCCN Content is governed by the End-User License Agreement, and you MAY NOT distribute this Content or use it with any artificial intelligence model or tool.
Printed by Ling Lu on 6/26/2026 6:10:47 AM. Copyright © 2026 National Comprehensive Cancer Network, Inc. All Rights Reserved.

neoadjuvant approach is favored as there is a defined tumor target, displacement of the adjacent bowel, the potential to reduce the risk of tumor seeding at the time of surgery, and may render tumors more amenable to resection.[53,258,259] Long-term results of two small non-randomized prospective studies showed favorable 5-year local recurrence-free survival (RFS) (60%), disease-free survival (DFS) (46%), and overall survival (OS) rates (61%) following R0 or R1 resection after neoadjuvant RT in patients with intermediate or high-grade retroperitoneal STS.[260] Analysis of data from 11 studies of retroperitoneal STS in a recent systematic review and meta-analysis indicated lower rates of LR with neoadjuvant versus adjuvant RT (odds ratio [OR], 0.03; *P* = .02).[53]

However, results from another study suggested that neoadjuvant RT may not be as effective for treating retroperitoneal/intra-abdominal STS as previously thought. EORTC-62092 (STRASS) was an open-label, randomized, phase 3 study that evaluated the efficacy and safety of neoadjuvant RT in 266 patients with primary localized retroperitoneal sarcoma.[261] The primary endpoint of the trial was not met, as the neoadjuvant RT + surgery group had a median abdominal recurrence-free survival of 4.5 versus 5 years in the surgery only group (hazard ratio [HR], 1.01; log rank *P* = .95). The most common grade 3 or 4 adverse events were lymphopenia (77%), anemia (12%), and hypoalbuminemia (12%) in the neoadjuvant RT + surgery group, and anemia (8%) and hypoalbuminemia (4%) in the surgery only group.

Although the authors stated that neoadjuvant RT should not be considered standard-of-care for retroperitoneal STS based on the STRASS data, this conclusion has drawn controversy.[261-264] Some have criticized the study design and interpretation of the data, including the use of a composite primary endpoint that defined a variety of events as abdominal recurrence. Additionally, information relevant to understanding the patient population, such as R0 versus R1 resection status, was not reported. The rate of grade 3 or 4 adverse events in the neoadjuvant RT group was also observed to be higher than that reported in another trial with a similar patient population, and could potentially be related to the rate of protocol compliance for RT reported in the STRASS trial (65%). Despite these limitations, it should be noted that the STRASS trial remains one of the few large randomized studies that has evaluated neoadjuvant RT for retroperitoneal STS.

Results from an exploratory post-hoc analysis of the STRASS data suggested that neoadjuvant RT may be favorable for certain patients with retroperitoneal sarcomas, such as those with liposarcoma.[261] Additional data from the trial also suggested that neoadjuvant RT may be effective in reducing the risk of LR.[261,263] Based on these observations, further investigation is needed to confirm which patients with retroperitoneal/intra-abdominal STS would benefit the most from neoadjuvant RT.

Based on the available evidence, the current guidelines recommend that neoadjuvant RT can be considered for selected patients with retroperitoneal/intra-abdominal STS who are at high risk for LR. If neoadjuvant RT is considered an appropriate treatment option, the guidelines recommend 50 Gy external beam radiation therapy (EBRT) (in 1.8–2 Gy per fraction), followed by surgery with clips and consideration of intraoperative RT (IORT) boost for known or suspected positive margins at the time of surgery (SARC-E 3 of 4). Adjuvant EBRT boost is discouraged in this setting. An alternative approach to be considered in experienced centers only is 45–50 Gy in 25–28 fractions to the entire clinical target volume (CTV) with dose-painted simultaneous integrated boost to total dose of 57.5 Gy in 25 fractions.[265,266] Since this approach is used in many NCCN Member Institutions, the guidelines have included this dosing schedule and recommend that higher-risk retroperitoneal margins should be jointly defined by the surgeon and the radiation oncologist, with no boost to be given after surgery.

Discussion update in progress

Version 3.2026 © 2026 National Comprehensive Cancer Network® (NCCN©), All rights reserved. NCCN Guidelines® and this illustration may not be reproduced in any form without the express written permission of NCCN.

PLEASE NOTE that use of this NCCN Content is governed by the End-User License Agreement, and you MAY NOT distribute this Content or use it with any artificial intelligence model or tool.
Printed by Ling Lu on 6/26/2026 6:10:47 AM. Copyright © 2026 National Comprehensive Cancer Network, Inc. All Rights Reserved.

Adjuvant RT

The panel discourages providing an adjuvant EBRT boost for retroperitoneal/intra-abdominal STS (SARC-E 3 of 4). If RT is not given prior to surgical resection, consider follow-up with possible neoadjuvant EBRT at time of localized recurrence. If adjuvant RT is deemed necessary in highly selected cases, a coordinated effort by the surgeon and the radiation oncologist to displace bowel from the tumor bed with omentum or other tissue displacers is recommended to reduce the risk of RT-related bowel toxicity.

Intraoperative RT

The use of IORT for retroperitoneal STS is provocative, but interpretation of the results is limited by the nature of the small and heterogenous studies.[267-274] In a prospective single institution study of patients with retroperitoneal STS treated with a protocol involving maximal tumor resection, high-dose-rate (HDR) IORT, and adjuvant EBRT, the overall 5-year local control rate for the whole group was 62%; local control rate was better for patients with primary tumors than for those with recurrent tumors (74% vs. 54%; $P = .40$).[268] The overall 5-year distant metastasis-free survival rate was 82% (100% for those with low-grade tumors vs. 70% for those with high-grade tumors; $P = .05$). The 5-year DFS and OS rates were 55% and 45%, respectively. IORT with or without EBRT has been effective in terms of local control and survival in patients with primary and recurrent retroperitoneal STS.[269-271,273] In a study that assessed the long-term outcome of patients with retroperitoneal STS treated by neoadjuvant RT, resection, and IORT with intraoperative electron beam RT (IOERT), OS (74% and 30%, respectively) and local control (83% and 61%, respectively) were better in patients undergoing gross total resection and IOERT compared to those who had only gross total resection.[269] An ongoing phase I/II study (NCT01566123) is examining neoadjuvant RT, followed by surgery with IORT in patients with high-risk retroperitoneal sarcoma. Preliminary results suggest promising local control and OS rates.[275]

Chemotherapy/Chemoradiation

Resectable Disease

Neoadjuvant Therapy

Neoadjuvant chemotherapy[67-71] or chemoradiation[72-81] has been evaluated in single and multicenter studies in patients with high-grade tumors; however, much of the available randomized data speaks to the management of extremity sarcomas.

Studies that have evaluated neoadjuvant chemotherapy followed by surgery have reported inconsistent findings. The results of a randomized study that compared surgery alone versus neoadjuvant chemotherapy followed by surgery in 134 evaluable patients with high-risk tumors (tumors ≥8 cm of any grade, grade II/III tumors <8 cm, grade II/III locally recurrent tumors, or tumors with inadequate surgery) did not show a major survival benefit for patients receiving chemotherapy.[68] At a median follow-up of 7.3 years, the estimated 5-year disease-free survival (DFS) rate was 52% for the no chemotherapy arm and 56% for the chemotherapy arm ($P = .3548$). The corresponding 5-year OS rate for both arms was 64% and 65%, respectively ($P = .2204$). A cohort analysis of 674 patients with stage III STS of extremity treated at a single institution revealed that clinical benefits associated with neoadjuvant or adjuvant doxorubicin-based chemotherapy were not sustained beyond 1 year.[69] In another retrospective study, the benefit of neoadjuvant chemotherapy was only seen in patients with high-grade extremity tumors larger than 10 cm but not in patients with tumors 5 to 10 cm.[70]

In a single-institution study involving 48 patients with high-grade extremity STS (≥8 cm), the outcome of patients treated with neoadjuvant chemoradiation with the MAID (mesna, doxorubicin, ifosfamide, and

Discussion update in progress

Version 3.2026 © 2026 National Comprehensive Cancer Network® (NCCN©), All rights reserved. NCCN Guidelines® and this illustration may not be reproduced in any form without the express written permission of NCCN.

PLEASE NOTE that use of this NCCN Content is governed by the End-User License Agreement, and you MAY NOT distribute this Content or use it with any artificial intelligence model or tool.
Printed by Ling Lu on 6/26/2026 6:10:47 AM. Copyright © 2026 National Comprehensive Cancer Network, Inc. All Rights Reserved.

dacarbazine) regimen followed by surgery and adjuvant chemotherapy with the same regimen was superior to that of historical controls.[74] The 5-year actuarial local control, freedom from distant metastasis, DFS, and OS rates were 92% and 86% (*P* = .1155), 75% and 44% (*P* = .0016), 70% and 42% (*P* = .0002), and 87% and 58% (*P* = .0003) for the MAID and control groups, respectively.[74] The same protocol was later evaluated in the RTOG 9514 study of 66 patients with large (≥8 cm), high-grade (stage II or III; grade 2 or 3 in a 3-tier grading system), primary, or locally recurrent STS of the extremities or trunk.[76,77] The 5-year rates of locoregional failure (including amputation) and distant metastasis were 22% and 28%, respectively, with a median follow-up of 7.7 years. The estimated 5-year DFS, distant DFS, and OS rates were 56%, 64%, and 71%, respectively.[77] Long-term follow-up data of these studies confirmed that neoadjuvant chemoradiation followed by resection and adjuvant chemotherapy with a doxorubicin-based regimen improves local control and OS and DFS rates in patients with high-grade STS of extremity and body wall; however, neoadjuvant chemoradiation was associated with significant short-term toxicities.[77,78]

An ongoing prospective randomized trial, STRASS II (NCT04031677), is evaluating the role of neoadjuvant chemotherapy in high-risk retroperitoneal STS.[276] Those randomized to chemotherapy will receive doxorubicin and ifosfamide, unless they have a diagnosis of leiomyosarcoma (LMS), in which case they will receive doxorubicin and dacarbazine. The study will randomize 250 patients and assess the difference in DFS with or without neoadjuvant chemotherapy.

Adjuvant Therapy

Available evidence from meta-analyses[82-86] and randomized clinical trials[87-92] suggests that adjuvant chemotherapy improves RFS in patients with STS of extremities. However, data regarding OS advantage are conflicting. It is not clear if the conclusions from these trials are applicable to retroperitoneal/intra-abdominal sarcomas, and thus care should be individualized.

The Sarcoma Meta-Analysis Collaboration (SMAC) performed a meta-analysis of 14 randomized studies (1568 patients), which compared adjuvant chemotherapy to follow-up and in some cases RT after surgery with a variety of sarcomas.[83] The result of the meta-analysis showed that doxorubicin-based chemotherapy prolongs local and distant recurrence and overall RFS in adults with localized, resectable STS of the extremity and is associated with decreased recurrence rates. The OS advantage was not significant, although there was a trend in favor of adjuvant chemotherapy.

An updated meta-analysis also confirmed the marginal efficacy of adjuvant chemotherapy in terms of local, distant, and overall recurrence as well as OS (which is contrary to that reported in the SMAC meta-analysis) in patients with localized STS (n = 1953).[85] A recent large, cohort-based analysis with a median follow-up of 9 years indicated that adjuvant chemotherapy may be associated with significantly improved 5-year metastasis-free survival (58% vs. 49%; *P* = .01) and 5-year OS (58% vs. 45%; *P* = .0002) in patients with FNCLCC grade 3 STS, whereas it was not significantly different in those with FNCLCC grade 2 STS (5-year metastasis-free survival, 76% vs. 73%; *P* = .27; 5-year OS, 75% vs. 65%; *P* = .15).[86]

In the Italian cooperative study (n = 104), which randomized patients with high-grade or recurrent extremity sarcoma to receive adjuvant chemotherapy with epirubicin and ifosfamide or observation alone, after a median follow-up of 59 months, median DFS (48 vs. 16 months) and median OS (75 vs. 46 months) were significantly better in the treatment group; the absolute benefit for OS from chemotherapy was 13% at 2 years and increased to 19% at 4 years for patients receiving chemotherapy.[88] After a median follow-up of 90 months, the estimated 5-year OS rate was

Discussion Update in Progress

Version 3.2026 © 2026 National Comprehensive Cancer Network® (NCCN©), All rights reserved. NCCN Guidelines® and this illustration may not be reproduced in any form without the express written permission of NCCN.

PLEASE NOTE that use of this NCCN Content is governed by the End-User License Agreement, and you MAY NOT distribute this Content or use it with any artificial intelligence model or tool.
Printed by Ling Lu on 6/26/2026 6:10:47 AM. Copyright © 2026 National Comprehensive Cancer Network, Inc. All Rights Reserved.

66% and 46%, respectively (*P* = .04), for the treatment group and the control group; however, the difference was not statistically different in the intent-to-treat analysis.[93]

In another phase III study (EORTC-62931), 351 patients with macroscopically resected grade II–III tumors with no metastases were randomized to observation or adjuvant chemotherapy with ifosfamide and doxorubicin with lenograstim.[90] A planned interim analysis of this study showed no survival advantage for adjuvant chemotherapy in patients with resected high-grade STS. The estimated 5-year RFS was 52% in both arms and the corresponding OS rates were 64% and 69%, respectively, for patients assigned to adjuvant chemotherapy and observation. These findings are consistent with the results reported in an earlier EORTC study by Bramwell and colleagues.[87] In that study, adjuvant chemotherapy with CYVADIC (cyclophosphamide, vincristine, doxorubicin, and dacarbazine) was associated with higher RFS rates (56% vs. 43% for the control group; *P* = .007) and significantly lower LR rates (17% vs. 31% for the control group; *P* = .004). However, there were no differences in distant metastases (32% and 36%, respectively, for CYVADIC and the control group; *P* = .42) and OS rates (63% and 56%, respectively, for CYVADIC and the control group; *P* = .64).

A pooled analysis of these two randomized EORTC studies (pooled, n = 819) evaluated whether adjuvant doxorubicin-based chemotherapy provided survival benefits in any particular subset of patients with resected STS in these trials.[92] Adjuvant doxorubicin-based chemotherapy was associated with improved RFS in male patients and those older than 40 years, although female patients and those younger than 40 years who received adjuvant chemotherapy had marginally worse OS. However, RFS and OS were significantly improved in patients with R1 resection who received adjuvant chemotherapy compared with those who did not.

Long-term follow-up results of another prospective randomized study also showed that adjuvant chemotherapy with IFADIC (ifosfamide, doxorubicin, and dacarbazine) given every 14 days with growth factor support did not result in significant benefit in terms of RFS (39% for IFADIC and 44% for the control group; *P* = .87) as well as OS (*P* = .99) for patients with grade 2 or 3 STS.[91]

Advanced, Unresectable, or Metastatic Disease

Chemotherapy with single agents (dacarbazine, doxorubicin, epirubicin, or ifosfamide) or anthracycline-based combination regimens (doxorubicin or epirubicin with ifosfamide and/or dacarbazine) have been widely used for patients with advanced, unresectable, or metastatic disease.[94-106] Other chemotherapeutic agents such as gemcitabine, docetaxel, vinorelbine, pegylated liposomal doxorubicin, and temozolomide have also been evaluated in clinical trials. The METASARC observational study, which explored “real-world” outcomes among 2225 patients with metastatic STS, found a positive association of OS with front-line combination chemotherapy, LMS histology, and locoregional treatment of metastases. However, with the exception of LMS, the benefits of systemic therapy beyond the second-line setting were very limited.[107]

Gemcitabine in combination with docetaxel, vinorelbine, or dacarbazine has been shown to be active in patients with unresectable or metastatic STS of various histologic subtypes.[108-112] In a randomized phase II study, the combination of gemcitabine and docetaxel was associated with superior progression-free survival (PFS) (6.2 and 3.0 months, respectively) and OS (17.9 and 11.5 months, respectively) compared to gemcitabine alone in patients with metastatic STS.[109] In another phase II study, the combination of gemcitabine and vinorelbine was also associated with clinically meaningful rates of disease control in patients with advanced STS.[110] Clinical benefit (complete response [CR], partial response [PR], or stable disease at 4 months or more) was seen in 25% of

Discussion Update in progress

Version 3.2026 © 2026 National Comprehensive Cancer Network® (NCCN©), All rights reserved. NCCN Guidelines® and this illustration may not be reproduced in any form without the express written permission of NCCN.

PLEASE NOTE that use of this NCCN Content is governed by the End-User License Agreement, and you MAY NOT distribute this Content or use it with any artificial intelligence model or tool.
Printed by Ling Lu on 6/26/2026 6:10:47 AM. Copyright © 2026 National Comprehensive Cancer Network, Inc. All Rights Reserved.

patients. The combination of gemcitabine and dacarbazine resulted in superior PFS (4.2 vs. 2 months; *P* = .005), OS (16.8 vs. 8.2 months; *P* = .014), and objective response rate (49% vs. 25%; *P* = .009) compared to dacarbazine alone in patients with previously treated advanced STS.[111]

However, gemcitabine combination therapy was not superior to single-agent doxorubicin in the randomized phase III GeDDiS trial. Among patients with previously untreated advanced or metastatic disease (n = 257), combination therapy with gemcitabine and docetaxel did not result in superior PFS compared with doxorubicin (23.7 vs. 23.3 weeks; *P* = .06).[112] It should be noted that this study utilized lower doses of gemcitabine and docetaxel as compared to other published studies.

Temozolomide,[113-115] pegylated liposomal doxorubicin,[116] and vinorelbine[117,118] have also shown activity as single agents in patients with advanced, metastatic, relapsed, or refractory disease. In a phase II study by the Spanish Group for Research on Sarcomas, temozolomide resulted in an overall response rate of 15.5% with a median OS of 8 months in patients with advanced pretreated STS.[115] The PFS rates at 3 and 6 months were 39.5% and 26%, respectively. In a prospective randomized phase II study, pegylated liposomal doxorubicin had equivalent activity and improved toxicity profile compared to doxorubicin; response rates were 9% and 10% for doxorubicin and pegylated liposomal doxorubicin, respectively, in patients with advanced or metastatic STS.[116] In a retrospective study of pretreated patients with metastatic STS, vinorelbine induced overall response in 6% of patients and 26% had stable disease.[117]

Trabectedin is a novel DNA-binding agent that has shown objective responses in phase II and III studies of patients with advanced STS.[119-127] Recent phase III data from a randomized, multicenter trial revealed a 2.7-month PFS benefit versus dacarbazine in metastatic liposarcoma (LPS) or LMS that progressed after anthracycline-based therapy.[125] However, the study failed to demonstrate an overall survival advantage for trabectedin over dacarbazine.[277]

Another study supported the efficacy of trabectedin in translocation-related sarcoma.[127] A phase III trial comparing trabectedin and doxorubicin-based chemotherapy revealed that neither arm showed superiority for PFS and OS; however, the trial was underpowered.[128] Preliminary results from the randomized phase III T-SAR trial revealed a PFS benefit for trabectedin over best supportive care in both “L-type” (LPS and LMS) and non–L-type pretreated advanced sarcoma.[129] However, trabectedin plus doxorubicin failed to demonstrate superiority over doxorubicin alone in a randomized phase II study of patients with advanced STS.[130] Trabectedin is included for palliative therapy as a category 1 recommendation for LPS and LMS (L-type) and as category 2A for non–L-type sarcomas.

Eribulin is a novel microtubule-inhibiting agent that has been evaluated as a single-agent therapy for STS, including LMS, adipocytic sarcoma, synovial sarcoma, and other tumor types.[131] Recent data from a phase III trial compared the survival benefit of eribulin and dacarbazine in 452 patients with advanced LMS or LPS, revealing a median OS of 13.5 months and 11.5 months, respectively (HR, 0.77; 95% CI, 0.62–0.95; *P* = .017).[132] A subgroup analysis demonstrated that the survival benefit was limited to LPS, and therefore eribulin is included for palliative therapy as a category 1 recommendation for LPS and as category 2A for other subtypes.

Please refer to SARC-F 1 of 11 for a complete list of chemotherapy agents and regimens recommended for STS subtypes with non-specific histologies.

Discussion Update In progress

Version 3.2026 © 2026 National Comprehensive Cancer Network® (NCCN©), All rights reserved. NCCN Guidelines® and this illustration may not be reproduced in any form without the express written permission of NCCN.

PLEASE NOTE that use of this NCCN Content is governed by the End-User License Agreement, and you MAY NOT distribute this Content or use it with any artificial intelligence model or tool.
Printed by Ling Lu on 6/26/2026 6:10:47 AM. Copyright © 2026 National Comprehensive Cancer Network, Inc. All Rights Reserved.

Targeted Therapy

More recently, a number of targeted therapies have shown promising results in patients with certain histologic types of advanced or metastatic STS.

Pazopanib, a multitargeted tyrosine kinase inhibitor (TKI), has demonstrated single-agent activity in patients with advanced STS subtypes except LPS.[133-136,278-280] In a phase III study (EORTC 62072), 369 patients with metastatic non-lipogenic STS who had failed at least one anthracycline-based chemotherapy regimen were randomized to either pazopanib or placebo.[135] Pazopanib significantly prolonged median PFS (4.6 vs.1.6 months for placebo; $P < .0001$) and there was also a trend toward improved OS (12.5 and 11 months, respectively; $P = .25$), although this was not statistically significant. Health-related quality-of-life measures did not improve or decline with the PFS benefit.[137] Pooled data from individuals who received pazopanib in phase II and III trials (n = 344) revealed a subset of long-term responders/survivors presenting at baseline with good performance status, low-/intermediate-grade primary tumor, and normal hemoglobin level.[138] Results from the open-label phase II EPAZ study found that pazopanib demonstrated non-inferior PFS compared with doxorubicin (4.4 vs. 5.3 months, respectively) as a first-line treatment in older patients with advanced/metastatic STS.[281] The guidelines have included pazopanib as a first-line therapy option for those with advanced or metastatic disease who are ineligible for intravenous (IV) systemic therapy or are not candidates for anthracycline-based regimens, and as a subsequent-line treatment option for patients with advanced or metastatic non-lipogenic STS as palliative therapy (SARC-F 1 of 11). Pazopanib in combination with gemcitabine is a category 2B subsequent-line treatment option for advanced/metastatic disease.[282]

The randomized, phase II REGOSARC trial examined regorafenib, a multi-targeted tyrosine kinase inhibitor approved for treating GIST, in cohorts of patients with advanced LPS, LMS, synovial sarcoma, and other non-GIST STS subtypes (REGOSARC, n = 182).[158,159] Compared to placebo, regorafenib significantly extended PFS in all but the LPS cohort. In patients with nonadipocytic STS, overall PFS for regorafenib and placebo-treated patients was 4 months versus 1 month (HR, 0.36; $P < .0001$). Regorafenib is included in the guidelines as a treatment option for advanced/metastatic non-adipocytic sarcomas, as well as angiosarcoma.[158,283]

Tropomyosin receptor kinase (TRK) inhibitors larotrectinib and entrectinib have demonstrated efficacy in patients with neurotrophic receptor tyrosine kinase (*NTRK)* fusion-positive tumors, and are therefore recommended as first-line treatment options for patients with advanced or metastatic *NTRK* gene fusion-positive sarcomas in the guidelines.[284,285]

Programmed cell death protein 1 (PD-1) inhibitor pembrolizumab is approved by the U.S. Food and Drug Administration (FDA) for unresectable or metastatic tumor mutational burden-high (TMB-H) (≥10 mutations/megabases [mut/Mb]) tumors, as determined by an FDA-approved test, that have progressed following prior treatment and who have no satisfactory alternative options.[286] In the guidelines, pembrolizumab is included as a subsequent-line treatment option for patients with certain subtypes of advanced or metastatic STS, including myxofibrosarcoma, undifferentiated pleomorphic sarcoma (UPS), cutaneous angiosarcoma, and undifferentiated sarcomas.[287,288]

Please refer to SARC-F 1 of 11 for a complete list of targeted therapies recommended for STS subtypes with non-specific histologies.

Treatment Guidelines

Resectable Disease

Surgical wide resection with oncologically appropriate negative margins is a potentially curative treatment for nonmetastatic primary

Discussion Update in Progress

Version 3.2026 © 2026 National Comprehensive Cancer Network® (NCCN©), All rights reserved. NCCN Guidelines® and this illustration may not be reproduced in any form without the express written permission of NCCN.

PLEASE NOTE that use of this NCCN Content is governed by the End-User License Agreement, and you MAY NOT distribute this Content or use it with any artificial intelligence model or tool.
Printed by Ling Lu on 6/26/2026 6:10:47 AM. Copyright © 2026 National Comprehensive Cancer Network, Inc. All Rights Reserved.

retroperitoneal/intra-abdominal sarcomas (RETSARC-2). The margin status after surgery is an important factor associated with long-term DFS.[289-293] In a large single-institution series involving 500 patients, the median survival was 103 months for those who underwent complete resection with grossly negative margins in contrast to 18 months for those who underwent incomplete resection.[292]

Two recent retrospective analyses reported improved local control in patients with primary retroperitoneal sarcoma operated with more aggressive approaches such as complete compartmental resection and a more liberal visceral en bloc resection performed in high-volume centers.[294,295] While the results are encouraging, this technique needs to be investigated in prospective clinical trials. For information on the *Principles of Surgery*, please refer to SARC-D 1 of 2.

Given the close proximity of retroperitoneal/intra-abdominal sarcomas to critical structures, complete or macroscopic surgical resection is achieved in less than 70% of patients. LR and disease progression continue to be a significant cause of morbidity in many patients.[296-298] Multimodality treatment (surgery with RT and/or chemotherapy) is the subject of clinical investigation, given the inability to obtain negative surgical margins and high LR rates, as discussed above.[299]

If RT is anticipated, neoadjuvant RT with an IMRT approach to optimize sparing of nearby critical structures is preferred because it reduces the risk of tumor seeding at the time of surgery and may render tumors more amenable to resection.[258] Neoadjuvant RT can be considered in selected patients with retroperitoneal/intra-abdominal sarcomas who are at high risk for local recurrence.[261] For patients treated with neoadjuvant EBRT (50 Gy; 1.8–2.0 Gy per fraction), the guidelines recommend consideration of IORT boost for patients with known or suspected positive margins at the time of surgery, if this can be done within the constraints of adjacent normal tissue (SARC-E 3 of 4). The guidelines recommend an IORT boost of 10–12.5 Gy for microscopic residual disease, and 15 Gy for gross disease.

An analysis of 8653 patients with resected retroperitoneal STS from the NCDB revealed worse OS in the surgically resected cohort receiving chemotherapy (neoadjuvant and/or adjuvant) versus those who underwent surgery alone (40 vs. 52 months; P = .002).[300] Neoadjuvant chemotherapy may have advantages over adjuvant chemotherapy. However, the role of neoadjuvant chemotherapy versus adjuvant chemotherapy has not yet been evaluated in randomized clinical trials.[301] Little data are available for the use of combined RT and chemotherapy. Decisions about adjuvant or neoadjuvant chemotherapy or RT are left to clinical judgment.[302-304] The regimens listed in the guidelines are based on the extrapolation of data derived from clinical trials on STS of the extremity that have included a small number of patients with retroperitoneal STS.[305]

The guidelines state that neoadjuvant systemic therapy can be considered as an option in selected cases; specifically, if there is a high risk for metastatic disease or if downstaging is needed to facilitate resection (RETSARC-2). Systemic therapy is not recommended for low-grade tumors.

Following surgery, adjuvant systemic therapy could be considered for all patients who are at high risk for metastatic disease based on surgical outcomes or clinical pathologic findings (RETSARC-3). For R1 or R2 outcomes, adjuvant RT should not be administered routinely, with the exception of highly selected patients and unless local recurrence would cause undue morbidity. For example, recurrence at a critical anatomic surface that would cause morbidity. For R2 outcomes, re-resection can be considered if the cancer of the biology (grade, invasiveness), the technical aspects of the operation (R0 resection anticipated as a reasonable possibility), and the comorbidities of the patient allow for a safe intervention at the judgement of the operating surgeon. Additionally, the

Discussion update in progress

Version 3.2026 © 2026 National Comprehensive Cancer Network® (NCCN©), All rights reserved. NCCN Guidelines® and this illustration may not be reproduced in any form without the express written permission of NCCN.

PLEASE NOTE that use of this NCCN Content is governed by the End-User License Agreement, and you MAY NOT distribute this Content or use it with any artificial intelligence model or tool.
Printed by Ling Lu on 6/26/2026 6:10:47 AM. Copyright © 2026 National Comprehensive Cancer Network, Inc. All Rights Reserved.

primary treatment options as described below for unresectable disease are another alternative (RETSARC-4).

Unresectable or Stage IV Disease

Unresectable tumors are defined as those that involve vital structures or tumors whose removal would cause unacceptable morbidity. Patients who are medically unresectable (ie, not medically fit to tolerate a major retroperitoneal STS resection) are also included in this category.

Biopsy is recommended before any treatment for a patient with unresectable or metastatic disease (RETSARC-4). Patients with unresectable or stage IV disease could be treated with systemic therapy and/or RT, or undergo surgery for symptom control. Observation is an option if the patient is asymptomatic and there is indolent tumor growth. For patients undergoing definitive high-dose RT, there has been favorable experience reported in the literature with the use of tissue displacement spacers to keep bowel out of the high-dose RT volume.[306] In terms of response rate, the most active chemotherapy regimen in an unselected patient population is AIM (doxorubicin/ifosfamide/mesna).[217]

For unresectable or stage IV disease, follow-up imaging is recommended to assess treatment response (RETSARC-4). Options include CT (preferred) or MRI. Patients whose tumors become resectable following primary treatment should be managed as described above for resectable disease (RETSARC-2). Palliative or best supportive care are options if the tumor remains unresectable or if there is disease progression following primary treatment. Please refer to the NCCN Guidelines for Palliative Care at www.NCCN.org. In patients with stage IV disease, resection should always be considered for resectable metastatic disease if the primary tumor can be controlled.

Surveillance

Patients are recommended to have a follow-up physical examination with imaging (chest/abdominal/pelvic CT [preferred] or MRI) every 3 to 6 months for 2 to 3 years, then every 6 months for the next 2 years, and then annually, following management of primary disease (RETSARC-3).

Recurrent Disease

For patients with resectable recurrent disease, biopsy should be considered if the recurrent disease diagnosis is not clinically definitive (RETSARC-5). The guidelines recommend surgery to obtain oncologically appropriate margins; adjuvant systemic therapy can be considered if there is a high risk for metastatic disease or history of several recurrences with a high risk for additional local recurrences. In selected cases, neoadjuvant RT (if not previously given for the primary tumor) or neoadjuvant systemic therapy should be considered, followed by surgery with or without IORT. Adjuvant treatment may be considered for tumors at high risk for metastatic disease (RETSARC-3). For patients with recurrent disease that is unresectable or stage IV, please refer to the management of unresectable or stage IV disease as described above (RETSARC-4).

Desmoid Tumors (Aggressive Fibromatoses)

Desmoid tumors, also known as aggressive fibromatoses, are unique mesenchymal neoplasms that are often considered to be locally malignant but nonmetastasizing neoplasms. Specifically, these tumors are an aggressive fibroblastic proliferation of well-circumscribed, locally invasive, and differentiated fibrous tissue. Desmoid tumors can cause functional morbidity and are often locally invasive, but they rarely metastasize. The location and presentation of desmoids vary, from the abdominal wall of young pregnant individuals, to intra-abdominal mesenteric masses, and to large extremity masses in older adults.

Discussion update in progress

Version 3.2026 © 2026 National Comprehensive Cancer Network® (NCCN©), All rights reserved. NCCN Guidelines® and this illustration may not be reproduced in any form without the express written permission of NCCN.

PLEASE NOTE that use of this NCCN Content is governed by the End-User License Agreement, and you MAY NOT distribute this Content or use it with any artificial intelligence model or tool.
Printed by Ling Lu on 6/26/2026 6:10:47 AM. Copyright © 2026 National Comprehensive Cancer Network, Inc. All Rights Reserved.

Desmoid tumors often pose difficult decisions for patients because of the extent of surgery required for optimal control, their high recurrence rate, and their long natural history. Although they do not exhibit the histopathologic features to classify them as sarcomas, desmoid tumors are often categorized as low-grade sarcomas because of their high tendency to recur locally after excision.

Desmoid tumors have been reported to occur in 7.5% to 16% of patients with FAP, and the relative risk of developing desmoid tumors is much higher in patients with FAP than in the general population.[21-24] Abdominal desmoids may be a component of FAP and may also arise through elective surgical intervention (eg, colectomy) in susceptible patients.[21,307,308] In patients who have been treated with prophylactic colectomy, desmoids now represent a more significant cause of morbidity than carcinoma of the colon.[309]

Mutations in the *CTNNB1* gene encoding the β-catenin pathway have been identified in sporadic desmoid tumors, although the correlation of *CTNNB1* mutation status with the clinical outcome remains uncertain.[310-314] Lazar and colleagues identified mutations in the *CTNNB1* gene in 85% of patients with desmoid tumors.[310] Three distinct mutations, 41A, 45F, and 45P, were identified in 59%, 33%, and 8% of cases, respectively. Mutation 45F was associated with a high risk of recurrence; 5-year RFS rate was 23% for patients harboring 45F mutation compared to 57% for those with 41A and 68% for those with no mutations.[310] In a retrospective study of patients with extra-abdominal desmoid tumors, Domont and colleagues reported *CTNNB1* mutations in 87% of patients, and the 5-year RFS rate was significantly worse in patients with β-catenin mutations, regardless of the genotype, compared with wild-type tumors (49% vs. 75%, respectively).[311] Columbo and colleagues also reported that mutation 45F was associated with higher rates of LR among patients with primary, completely resected, sporadic desmoid tumors and mutation 45F was more prevalent in extra-abdominal desmoid tumors compared to other sites.[313] In contrast to these findings, Mullen and colleagues reported that *CTNNB1* mutation status or the specific *CTNNB1* mutation was not associated with any statistically significant difference in recurrence risk in a subset of 115 patients with desmoid tumors who underwent macroscopically complete surgical resection.[314] At a median follow-up of 31 months, the 5-year RFS rates were 58% and 74%, respectively, for patients with *CTNNB1* mutations and for those with wild-type tumors. Additional prospective studies are needed to confirm whether genotyping of *CTNNB1* may provide important information regarding the risk of recurrence and the selection of patients for adjuvant treatment options.

Discussion update in progress

Evaluation and Workup

The workup for desmoid tumors includes H&P (with evaluation for Gardner's syndrome/FAP) and appropriate imaging of the primary site with CT or MRI as clinically indicated. All patients should be managed by a multidisciplinary team. Biopsy should be performed for suspicious masses to confirm the diagnosis, and may not be necessary if complete resection is planned. The differential diagnosis for desmoids depends on location; it includes other sarcomas, other malignant carcinomas, and benign lesions. Desmoid tumors of the breast are difficult to differentiate from carcinomas, because they resemble carcinomas clinically and radiologically.[315-318]

Treatment Guidelines

Resectable Tumors

Surgery is the primary treatment for patients with resectable desmoid tumors.[319-323] Tumor location and size, patients' age, and margin status have been identified as factors associated with recurrence following resection. Extra-abdominal tumors have a higher risk of recurrence than abdominal tumors. In an analysis of 203 patients with desmoid tumors treated with surgery, Gronchi and colleagues reported significantly higher DFS rates for patients with abdominal wall tumors than those with

Version 3.2026 © 2026 National Comprehensive Cancer Network® (NCCN©), All rights reserved. NCCN Guidelines® and this illustration may not be reproduced in any form without the express written permission of NCCN.

PLEASE NOTE that use of this NCCN Content is governed by the End-User License Agreement, and you MAY NOT distribute this Content or use it with any artificial intelligence model or tool.
Printed by Ling Lu on 6/26/2026 6:10:47 AM. Copyright © 2026 National Comprehensive Cancer Network, Inc. All Rights Reserved.

extremity tumors. The 10-year DFS rates were 88% and 62%, respectively ($P < .01$).[324] In a more recent report involving 211 patients with desmoid tumors treated with surgery, Peng and colleagues also reported similar findings.[325] The median RFS was not reached following resection for patients with either abdominal wall or intra-abdominal tumors, whereas the median RFS was 29.4 months for patients with extra-abdominal tumors ($P < .001$).

The impact of positive resection margins on local control and risk of recurrence remains controversial.[326] Some studies have reported margin status as an independent prognostic factor of recurrence.[325,327-330] Other studies have failed to demonstrate any clear association between resection margins and risk of recurrence.[324,331] Recent data suggest no difference in outcomes between patients with R0 or R1 resection margins who undergo careful observation.[332-334] Therefore, R1 margins are acceptable if achieving R0 margins would produce excessive morbidity. However, a recent meta-analysis of 16 studies, including data from 1295 patients, found that R1 resections were associated with an almost 2-fold higher risk of recurrence (risk ratio, 1.78; 95% CI, 1.40–2.26).[330]

Several retrospective series have reported that postoperative RT significantly improves local control and PFS compared to surgery alone, suggesting that postoperative RT could be considered for patients who are at high risk of LR.[330,331,335-340] However, in another series of patients with desmoid tumors of the chest wall, postoperative RT did not reduce the risk of recurrence.[323]

The results of recent retrospective analyses suggest that observation may be appropriate for selected patients with resectable tumors (small size, asymptomatic, and tumors located at sites where increase in size will not alter the outcome of surgery or lead to functional limitation).[341,342] In a retrospective analysis of 142 patients with desmoid fibromatoses (74 with primary tumor and 68 with recurrence) reported by Fiore and colleagues, the 5-year PFS rates for patients with primary tumors were 47% for those who were treated with a “wait and see” approach (no surgery or RT) and 54% for those who received medical therapy (chemotherapy or hormonal therapy; $P = .70$).[342] The corresponding survival rates were 54% and 61% ($P = .48$) for patients with recurrence. Large tumors (greater than 10 cm in size) and tumors located on the trunk were associated with a high risk of recurrence.

Based on these results, the panel concluded that patients with desmoid fibromatoses can be managed appropriately with a careful “wait and see” approach if their tumors are asymptomatic and are not located in an area that could lead to functional limitations if the tumor increases in size. The guidelines have included observation as an option for selected patients with resectable tumors. Stable tumors can be followed with continued observation using H&P exam with appropriate imaging. If there is progression, patients can be treated with surgery and/or RT and/or systemic therapy.

For symptomatic patients with large tumors causing morbidity, pain, or functional limitation, treatment choices should be based on the location of the tumor and potential morbidity of the treatment. Options include surgery and/or RT and/or systemic therapy. Patients with resectable tumors should be treated with complete surgical resection when feasible. Microscopically positive margins may be acceptable if achieving negative margins would produce excessive morbidity. If surgical margins are negative after resection (R0 resection) or if there is complete radiographic response, patients may only be observed. For microscopically positive margins or minimal residual disease (R1 resection), observation or re-resection can be considered. Postoperative RT reduces the risk of recurrence in patients with positive margins and should be considered only if a subsequent relapse might lead to increased morbidity. Patients with macroscopic

Discussion update in progress

Version 3.2026 © 2026 National Comprehensive Cancer Network® (NCCN©), All rights reserved. NCCN Guidelines® and this illustration may not be reproduced in any form without the express written permission of NCCN.

PLEASE NOTE that use of this NCCN Content is governed by the End-User License Agreement, and you MAY NOT distribute this Content or use it with any artificial intelligence model or tool.
Printed by Ling Lu on 6/26/2026 6:10:47 AM. Copyright © 2026 National Comprehensive Cancer Network, Inc. All Rights Reserved.

surgical margins (R2 resection) are treated as described below for unresectable disease.

For treating progressive or recurrent desmoid tumors, options include: systemic therapy; resection; resection plus RT (50 Gy, if not previously irradiated); or RT alone (50–56 Gy, if not previously irradiated).

Unresectable Tumors

In the case of unresectable desmoid tumors, amputation should almost never be considered. Functional outcomes are important, and alternatives to amputation may be open to patients who have unresectable desmoid tumors.[324,343] RT is a reasonable treatment option for patients with unresectable tumors, depending on the possible morbidity of treatment.[331,344-347]

In a retrospective analysis of 23 patients with extra-mesenteric desmoid tumors treated with RT for gross residual unresectable disease, 7 patients sustained LR, yielding a 5-year actuarial local control rate of 69%. In another retrospective analysis that included 13 patients with unresectable tumors treated with RT alone as a definitive local therapy, the actuarial 3-year freedom-from-recurrence rate was 92.3%.[331] In a multicenter, prospective phase II study of 44 patients with inoperable desmoid tumors of trunk and extremities treated with RT (56 Gy in 28 fractions), Keus and colleagues reported a 3-year local control rate of 81.5%, at a median follow-up of 4.8 years.[347] During the first 3 years, CR, PR, and stable disease were observed in 13.6%, 36.4%, and 40.9% of patients, respectively. Response to RT was slow, with continuing regression seen even after 3 years.[347]

Definitive RT (50–56 Gy in the absence of any prior RT only for desmoid tumors of the extremity head and neck or superficial trunk), systemic therapy, and observation are some of the options for patients with unresectable tumors. Radical surgery should be considered only if other treatment modalities fail. RT is not generally recommended for retroperitoneal/intra-abdominal desmoid tumors.

Systemic therapy using non-steroidal anti-inflammatory drugs (NSAIDs), hormonal or biological agents, or cytotoxic drugs have shown promising results in patients with desmoid tumors.[348,349] In a prospective study, tamoxifen in combination with sulindac resulted in disease stabilization in patients with progressive or recurrent tumors following surgery.[350] The results of a retrospective, non-randomized study showed that interferon alfa with or without tretinoin may be effective in prolonging the disease-free interval after intralesional or marginal surgery in patients with extra-abdominal desmoid tumors.[351] In case reports, toremifene has been effective in disease stabilization following surgery.[352-355] Doxorubicin-based chemotherapy has been effective in patients with recurrent or unresectable tumors.[356-359] The combination of methotrexate and vinorelbine or vinblastine has also been associated with prolonged stable disease in patients with unresectable or recurrent tumors.[358,360-362]

Imatinib and sorafenib have also been evaluated in patients with unresectable, progressive, or recurrent aggressive fibromatosis.[153,363-365] In a phase II multicenter study, imatinib resulted in an objective response rate of 6% and the 1-year PFS rate was 66% in patients with unresectable tumors.[364] Long-term follow-up results of the phase II study by the French Sarcoma Group also showed that imatinib resulted in objective responses and stable disease in a large proportion of patients with recurrent or progressive aggressive fibromatosis.[365] At a median follow-up of 34 months, the 2-year PFS and OS rates were 55% and 95%, respectively. The non-progression rates at 3, 6, and 12 months were 91%, 80%, and 67%, respectively. In a study of 26 patients (11 patients received sorafenib as first-line therapy and the remaining 15 patients had received a median of 2 prior systemic therapies), sorafenib induced PR in 25% of patients

Discussion Update in Progress

Version 3.2026 © 2026 National Comprehensive Cancer Network® (NCCN©), All rights reserved. NCCN Guidelines® and this illustration may not be reproduced in any form without the express written permission of NCCN.

PLEASE NOTE that use of this NCCN Content is governed by the End-User License Agreement, and you MAY NOT distribute this Content or use it with any artificial intelligence model or tool.
Printed by Ling Lu on 6/26/2026 6:10:47 AM. Copyright © 2026 National Comprehensive Cancer Network, Inc. All Rights Reserved.

and 70% of patients had stable disease, with a median follow-up of 6 months.[153]

The guidelines have included NSAIDs (sulindac or celecoxib), hormonal or biological agents (tamoxifen, toremifene, or low-dose interferon), chemotherapy (methotrexate and vinblastine, doxorubicin-based regimens), and TKIs (imatinib and sorafenib) as options for systemic therapy for patients with advanced or unresectable desmoid tumors. The risk of cardiovascular events may be increased in patients receiving celecoxib, and patients with cardiovascular disease or risk factors for cardiovascular disease may be at greater risk. Physicians prescribing celecoxib should consider this information when weighing the benefits against risks for individual patients.

Surveillance

Every patient should have an H&P with CT or MRI every 3 to 6 months for 2 to 3 years and then every 6 to 12 months thereafter. Disease progression or recurrence should be managed as described under primary treatment for resectable or unresectable disease.

Rhabdomyosarcoma

RMS is more common among children and adolescents but is less common in adults accounting for 2% to 5% of all STSs.[366] RMS has three histologic subtypes: embryonal (including botryoid and spindle cell variants), alveolar (including a solid variant), and pleomorphic histologies.[367,368] Embryonal and alveolar variants occur mainly in children and adolescents. Although pleomorphic RMS occurs predominantly in adults, embryonal and alveolar variants are also well represented.[366,368-373]

The incidence of pleomorphic RMS increases with age and the overall prognosis of RMS in adults is poor.[374] In a study of 39 adult patients treated at a single institution, the incidence of pleomorphic RMS increased with age (0%, 27%, and 60%, respectively, for ages 16–19, 20–49, and 50 or older) and the median survival was 2.25 years after diagnosis.[374] Extremities, trunk wall, and genitourinary organs are the most common primary sites for pleomorphic RMS in adults.[375-377] In a recent SEER database analysis of 1071 adults (older than 19 years) with RMS, the most common primary sites included extremities (26%) and trunk (23%) followed by genitourinary tract (17%) and head and neck (9%).[372] Pleomorphic histologies (19% vs. 1% in children; $P < .0001$) and unfavorable sites (65% vs. 55% in children; $P < .0001$) were more common in adults; the estimated 5-year OS rates were 27% for adults compared to 63% for pediatric patients.[372]

Given the rarity of the clinical situation, there are very limited data (mostly from single-institution retrospective studies) available on the management of adults with RMS. Multimodality treatment (surgery, RT, and chemotherapy) has been used in all of these studies. In the largest retrospective single-institution study that evaluated 180 patients diagnosed with RMS (18 years or older; 143 patients with embryonal, alveolar, or RMS not otherwise specified; and 37 patients with pleomorphic histology), Ferrari and colleagues reported 5-year EFS and OS rates of 28% and 40%, respectively.[366] The overall response rate was 85% in patients with embryonal and alveolar RMS treated with chemotherapy according to the pediatric protocol. Surgery was the main treatment in patients with pleomorphic RMS (74% compared to 34% with non-pleomorphic histologies), and the EFS rate was 37% for patients who underwent complete resection compared to 0% in patients with unresectable tumors.[366]

Other retrospective studies from MD Anderson Cancer Center (82 adults) and Dana Farber Cancer Institute (39 patients) have also reported high overall response rates to chemotherapy (75% and 82%, respectively).[370,378] Survival was significantly better for patients with disease responding to chemotherapy than those with disease that did not.

Version 3.2026 © 2026 National Comprehensive Cancer Network® (NCCN©), All rights reserved. NCCN Guidelines® and this illustration may not be reproduced in any form without the express written permission of NCCN.

PLEASE NOTE that use of this NCCN Content is governed by the End-User License Agreement, and you MAY NOT distribute this Content or use it with any artificial intelligence model or tool.
Printed by Ling Lu on 6/26/2026 6:10:47 AM. Copyright © 2026 National Comprehensive Cancer Network, Inc. All Rights Reserved.

In the MD Anderson Cancer Center study, the 10-year metastasis-free survival was 72% for patients with disease that responded to chemotherapy compared to 19% for those with disease that failed to respond.[370]

In the series from Dana Farber Cancer Institute, metastatic disease at presentation and poor response to chemotherapy were independent predictors of poor prognosis; the 5-year survival rate was 57% for patients with a CR to chemotherapy compared to only 7% for those with poor response.[378] In this study, 5-year survival rates were also higher for patients who underwent complete resection than for those who did not (63% vs. 29% and 46% for those who underwent compromised or incomplete resections, respectively).[378] Hawkins and colleagues also reported that margin status after resection was predictive of disease-specific survival in adult patients (105 months for patients who underwent complete resection compared to 9 months for those with positive margins).[369]

Chemotherapy regimens used in adults with RMS are usually derived from the pediatric clinical trials on RMS conducted by international cooperative groups.[379] Vincristine, dactinomycin, and cyclophosphamide (VAC) has been the standard chemotherapy for pediatric nonmetastatic RMS (intermediate or high risk).[380] In a randomized study (D9803) from the Children's Oncology Group (COG), there was no significant survival benefit of adding topotecan to standard VAC regimen in children with intermediate-risk RMS. In this study, at a median follow-up of 4.3 years, the 4-year failure-free-survival (FFS) rate was 73% and 68%, respectively, for patients treated with VAC and VAC alternating with vincristine, topotecan, and cyclophosphamide (P = .30).[380] RT resulted in good local control for patients with alveolar RMS who underwent primary tumor resection before initiation of chemotherapy. [381]

The results of the Intergroup RMS Study (D9602) showed that newly diagnosed patients with low-risk RMS treated with vincristine and dactinomycin had similar 5-year FFS rates compared to those patients treated with vincristine, dactinomycin, and cyclophosphamide (89% and 85%, respectively), suggesting that vincristine and dactinomycin could be an appropriate option for patients with newly diagnosed, low-risk RMS.[382] Vincristine, doxorubicin, and cyclophosphamide alternating with ifosfamide and etoposide (VAC-IE) was found to be effective for patients with intermediate-risk RMS.[383] A recent study from COG in primarily pediatric patients with metastatic RMS investigated intensive multiagent therapy with radiation that included blocks of vincristine/irinotecan, interval compression with VAC-IE, and vincristine/dactinomycin/cyclophosphamide. For patients with zero to one Oberlin risk factor, the 3-year EFS of 69% (95% CI, 52%–82%) was improved compared with historical controls, whereas high-risk disease had a 3-year EFS of 20% (95% CI, 11%–30%).[384]

Newer agents such as carboplatin,[385] irinotecan,[386-389] topotecan,[390-392] and vinorelbine[393,394] have also shown activity in the treatment of pediatric patients with metastatic, relapsed, or refractory RMS. A phase II study recently provided preliminary evidence for efficacy and tolerability of RT with concurrent irinotecan/carboplatin regimens for patients with intermediate or high-risk RMS.[395]

Retrospective studies on adults with RMS have used a variety of multidrug chemotherapy regimens, including cyclophosphamide or ifosfamide, doxorubicin, and/or dactinomycin with or without vincristine or other drugs such as cisplatin, carboplatin, and etoposide.[366,370,374,378,396] In the MD Anderson Cancer Center study, the 10-year overall, disease-free, and metastasis-free survival rates were 47%, 45%, and 59%, respectively, for adult patients treated with chemotherapy regimens containing vincristine and cyclophosphamide with dactinomycin or doxorubicin.[370] Esnaola and

Discussion update in progress

Version 3.2026 © 2026 National Comprehensive Cancer Network® (NCCN®), All rights reserved. NCCN Guidelines® and this illustration may not be reproduced in any form without the express written permission of NCCN.

PLEASE NOTE that use of this NCCN Content is governed by the End-User License Agreement, and you MAY NOT distribute this Content or use it with any artificial intelligence model or tool.
Printed by Ling Lu on 6/26/2026 6:10:47 AM. Copyright © 2026 National Comprehensive Cancer Network, Inc. All Rights Reserved.

colleagues reported an overall response rate of 82%, with a CR rate of 45% in adults with RMS treated with vincristine, doxorubicin, and cyclophosphamide or other doxorubicin-based chemotherapy regimens.[378] Ogilvie and colleagues also reported that chemotherapy with vincristine, doxorubicin, and ifosfamide resulted in an overall response rate of 86% in 11 adult patients with pleomorphic RMS; the 2-year OS and DFS rates were 55% and 64%, respectively.[396] Additionally, a recent review suggested that vincristine, irinotecan, and temozolomide in combination with local therapy may provide some degree of disease control for relapsed RMS.[397]

These guidelines strongly recommend that all patients should be referred to institutions with expertise in treating patients with RMS. Evaluation by a multidisciplinary team involving pediatric, medical, surgical, and radiation oncologists is strongly encouraged. Multimodality treatment (surgery, RT, and chemotherapy) planning and risk stratification is required for all patients.[379] PET imaging may be useful for initial staging because of the possibility of nodal metastases and the appearance of unusual sites of initial metastatic disease in adult patients.[398]

Systemic chemotherapy options for RMS may be different than those used with other STS histologies. Pleomorphic RMS is usually excluded from RMS randomized clinical trials. Consideration to treat according to STS guidelines may be warranted for this group of patients. In the absence of data from prospective clinical trials, there are no definitive, optimal regimens for the management of adult RMS. See *Systemic Therapy Agents and Regimens with Activity in Soft Tissue Sarcoma* in the algorithm for a list of chemotherapy regimens that are recommended for the management of adults with RMS.

Discussion update in progress

PLEASE NOTE that use of this NCCN Content is governed by the End-User License Agreement, and you MAY NOT distribute this Content or use it with any artificial intelligence model or tool.
Printed by Ling Lu on 6/26/2026 6:10:47 AM. Copyright © 2026 National Comprehensive Cancer Network, Inc. All Rights Reserved.

References

1. Siegel RL, Miller KD, Fuchs HE, Jemal A. Cancer statistics, 2022. CA Cancer J Clin 2022;72:7-33. Available at: https://www.ncbi.nlm.nih.gov/pubmed/35020204.

2. Brady MS, Gaynor JJ, Brennan MF. Radiation-associated sarcoma of bone and soft tissue. Arch Surg 1992;127:1379-1385. Available at: http://www.ncbi.nlm.nih.gov/pubmed/1365680.

3. Zahm S, Fraumeni JF, Jr. The epidemiology of soft tissue sarcoma. Semin Oncol 1997;24:504-514. Available at: http://www.ncbi.nlm.nih.gov/pubmed/9344316.

4. Penel N, Grosjean J, Robin YM, et al. Frequency of certain established risk factors in soft tissue sarcomas in adults: a prospective descriptive study of 658 cases. Sarcoma 2008;2008:459386. Available at: https://www.ncbi.nlm.nih.gov/pubmed/18497869.

5. Risk Factors for Soft Tissue Sarcomas. Available at: https://www.cancer.org/cancer/soft-tissue-sarcoma/causes-risks-prevention/risk-factors.html. Accessed April 12, 2022.

6. Pisters PWT, Weiss M, Maki R. Soft-Tissue Sarcomas In: Haller DG, Wagman LD, Camphausen C, Hoskins WJ, eds. Cancer Management:A Multidisciplinary Approach Medical, Surgical, & Radiation Oncology (ed 14): UBM Medica LLC; 2011.

7. Clasby R, Tilling K, Smith MA, Fletcher CD. Variable management of soft tissue sarcoma: regional audit with implications for specialist care. Br J Surg 1997;84:1692-1696. Available at: http://www.ncbi.nlm.nih.gov/pubmed/9448617.

8. Voss RK, Chiang YJ, Torres KE, et al. Adherence to National Comprehensive Cancer Network Guidelines is Associated with Improved Survival for Patients with Stage 2A and Stages 2B and 3 Extremity and Superficial Trunk Soft Tissue Sarcoma. Ann Surg Oncol 2017;24:3271-3278. Available at: https://www.ncbi.nlm.nih.gov/pubmed/28741122.

9. Li FP, Fraumeni JF, Jr., Mulvihill JJ, et al. A cancer family syndrome in twenty-four kindreds. Cancer Res 1988;48:5358-5362. Available at: http://www.ncbi.nlm.nih.gov/pubmed/3409256.

10. Galiatsatos P, Foulkes WD. Familial adenomatous polyposis. Am J Gastroenterol 2006;101:385-398. Available at: http://www.ncbi.nlm.nih.gov/pubmed/16454848.

11. Kleinerman RA, Tucker MA, Abramson DH, et al. Risk of soft tissue sarcomas by individual subtype in survivors of hereditary retinoblastoma. J Natl Cancer Inst 2007;99:24-31. Available at: http://www.ncbi.nlm.nih.gov/pubmed/17202110.

12. Half E, Bercovich D, Rozen P. Familial adenomatous polyposis. Orphanet J Rare Dis 2009;4:22. Available at: http://www.ncbi.nlm.nih.gov/pubmed/19822006.

13. Postow MA, Robson ME. Inherited gastrointestinal stromal tumor syndromes: mutations, clinical features, and therapeutic implications. Clin Sarcoma Res 2012;2:16. Available at: http://www.ncbi.nlm.nih.gov/pubmed/23036227.

14. Malkin D, Li FP, Strong LC, et al. Germ line p53 mutations in a familial syndrome of breast cancer, sarcomas, and other neoplasms. Science 1990;250:1233-1238. Available at: http://www.ncbi.nlm.nih.gov/pubmed/1978757.

15. Nichols KE, Malkin D, Garber JE, et al. Germ-line p53 mutations predispose to a wide spectrum of early-onset cancers. Cancer Epidemiol Biomarkers Prev 2001;10:83-87. Available at: http://www.ncbi.nlm.nih.gov/pubmed/11219776.

16. Ognjanovic S, Olivier M, Bergemann TL, Hainaut P. Sarcomas in TP53 germline mutation carriers. Cancer 2012;118:1387-1396. Available at: http://www.ncbi.nlm.nih.gov/pubmed/21837677.

17. Kleihues P, Schauble B, zur Hausen A, et al. Tumors associated with p53 germline mutations: a synopsis of 91 families. Am J Pathol 1997;150:1-13. Available at: http://www.ncbi.nlm.nih.gov/pubmed/9006316.

18. Olivier M, Goldgar DE, Sodha N, et al. Li-Fraumeni and related syndromes: correlation between tumor type, family structure, and TP53 genotype. Cancer Res 2003;63:6643-6650. Available at: http://www.ncbi.nlm.nih.gov/pubmed/14583457.

Version 3.2026 © 2026 National Comprehensive Cancer Network® (NCCN©), All rights reserved. NCCN Guidelines® and this illustration may not be reproduced in any form without the express written permission of NCCN.

PLEASE NOTE that use of this NCCN Content is governed by the End-User License Agreement, and you MAY NOT distribute this Content or use it with any artificial intelligence model or tool.
Printed by Ling Lu on 6/26/2026 6:10:47 AM. Copyright © 2026 National Comprehensive Cancer Network, Inc. All Rights Reserved.

19. Mitchell G, Ballinger ML, Wong S, et al. High frequency of germline TP53 mutations in a prospective adult-onset sarcoma cohort. PLoS One 2013;8:e69026. Available at: http://www.ncbi.nlm.nih.gov/pubmed/23894400.

20. Bisgaard ML, Bulow S. Familial adenomatous polyposis (FAP): genotype correlation to FAP phenotype with osteomas and sebaceous cysts. Am J Med Genet A 2006;140:200-204. Available at: http://www.ncbi.nlm.nih.gov/pubmed/16411234.

21. Gurbuz AK, Giardiello FM, Petersen GM, et al. Desmoid tumours in familial adenomatous polyposis. Gut 1994;35:377-381. Available at: http://www.ncbi.nlm.nih.gov/pubmed/8150351.

22. Fallen T, Wilson M, Morlan B, Lindor NM. Desmoid tumors -- a characterization of patients seen at Mayo Clinic 1976-1999. Fam Cancer 2006;5:191-194. Available at: http://www.ncbi.nlm.nih.gov/pubmed/16736290.

23. Nieuwenhuis MH, Casparie M, Mathus-Vliegen LM, et al. A nation-wide study comparing sporadic and familial adenomatous polyposis-related desmoid-type fibromatoses. Int J Cancer 2011;129:256-261. Available at: http://www.ncbi.nlm.nih.gov/pubmed/20830713.

24. Nieuwenhuis MH, Lefevre JH, Bulow S, et al. Family history, surgery, and APC mutation are risk factors for desmoid tumors in familial adenomatous polyposis: an international cohort study. Dis Colon Rectum 2011;54:1229-1234. Available at: http://www.ncbi.nlm.nih.gov/pubmed/21904137.

25. Carney JA, Stratakis CA. Familial paraganglioma and gastric stromal sarcoma: a new syndrome distinct from the Carney triad. Am J Med Genet 2002;108:132-139. Available at: http://www.ncbi.nlm.nih.gov/pubmed/11857563.

26. Pasini B, McWhinney SR, Bei T, et al. Clinical and molecular genetics of patients with the Carney-Stratakis syndrome and germline mutations of the genes coding for the succinate dehydrogenase subunits SDHB, SDHC, and SDHD. Eur J Hum Genet 2008;16:79-88. Available at: http://www.ncbi.nlm.nih.gov/pubmed/17667967.

27. Gill AJ, Chou A, Vilain R, et al. Immunohistochemistry for SDHB divides gastrointestinal stromal tumors (GISTs) into 2 distinct types. Am J Surg Pathol 2010;34:636-644. Available at: http://www.ncbi.nlm.nih.gov/pubmed/20305538.

28. Gaal J, Stratakis CA, Carney JA, et al. SDHB immunohistochemistry: a useful tool in the diagnosis of Carney-Stratakis and Carney triad gastrointestinal stromal tumors. Mod Pathol 2011;24:147-151. Available at: http://www.ncbi.nlm.nih.gov/pubmed/20890271.

29. Kleinerman RA, Schonfeld SJ, Tucker MA. Sarcomas in hereditary retinoblastoma. Clin Sarcoma Res 2012;2:15. Available at: http://www.ncbi.nlm.nih.gov/pubmed/23036192.

30. Korf BR. Neurofibromatosis. Handb Clin Neurol 2013;111:333-340. Available at: http://www.ncbi.nlm.nih.gov/pubmed/23622184.

31. Brems H, Beert E, de Ravel T, Legius E. Mechanisms in the pathogenesis of malignant tumours in neurofibromatosis type 1. Lancet Oncol 2009;10:508-515. Available at: http://www.ncbi.nlm.nih.gov/pubmed/19410195.

32. Domanski HA. Fine-needle aspiration cytology of soft tissue lesions: diagnostic challenges. Diagn Cytopathol 2007;35:768-773. Available at: http://www.ncbi.nlm.nih.gov/pubmed/18008345.

33. Antonescu CR. The role of genetic testing in soft tissue sarcoma. Histopathology 2006;48:13-21. Available at: http://www.ncbi.nlm.nih.gov/pubmed/16359533.

34. Pfeifer JD, Hill DA, O'Sullivan MJ, Dehner LP. Diagnostic gold standard for soft tissue tumours: morphology or molecular genetics? Histopathology 2000;37:485-500. Available at: http://www.ncbi.nlm.nih.gov/pubmed/11122430.

35. Hill DA, O'Sullivan MJ, Zhu X, et al. Practical application of molecular genetic testing as an aid to the surgical pathologic diagnosis of sarcomas: a prospective study. Am J Surg Pathol 2002;26:965-977. Available at: http://www.ncbi.nlm.nih.gov/pubmed/12170083.

36. Italiano A, Di Mauro I, Rapp J, et al. Clinical effect of molecular methods in sarcoma diagnosis (GENSARC): a prospective, multicentre,

Discussion Update in Progress

Version 3.2026 © 2026 National Comprehensive Cancer Network® (NCCN©), All rights reserved. NCCN Guidelines® and this illustration may not be reproduced in any form without the express written permission of NCCN.

PLEASE NOTE that use of this NCCN Content is governed by the End-User License Agreement, and you MAY NOT distribute this Content or use it with any artificial intelligence model or tool.
Printed by Ling Lu on 6/26/2026 6:10:47 AM. Copyright © 2026 National Comprehensive Cancer Network, Inc. All Rights Reserved.

observational study. Lancet Oncol 2016;17:532-538. Available at: http://www.ncbi.nlm.nih.gov/pubmed/26970672.

37. Sorensen PHB, Lynch JC, Qualman SJ, et al. PAX3-FKHR and PAX7-FKHR gene fusions are prognostic indicators in alveolar rhabdomyosarcoma: a report from the children's oncology group. J Clin Oncol 2002;20:2672-2679. Available at: http://www.ncbi.nlm.nih.gov/pubmed/12039929.

38. Guillou L, Benhattar J, Bonichon F, et al. Histologic grade, but not SYT-SSX fusion type, is an important prognostic factor in patients with synovial sarcoma: a multicenter, retrospective analysis. J Clin Oncol 2004;22:4040-4050. Available at: http://www.ncbi.nlm.nih.gov/pubmed/15364967.

39. Ladanyi M, Antonescu CR, Leung DH, et al. Impact of SYT-SSX fusion type on the clinical behavior of synovial sarcoma: a multi-institutional retrospective study of 243 patients. Cancer Res 2002;62:135-140. Available at: http://www.ncbi.nlm.nih.gov/pubmed/11782370.

40. Antonescu CR, Tschernyavsky SJ, Decuseara R, et al. Prognostic impact of P53 status, TLS-CHOP fusion transcript structure, and histological grade in myxoid liposarcoma: a molecular and clinicopathologic study of 82 cases. Clin Cancer Res 2001;7:3977-3987. Available at: http://www.ncbi.nlm.nih.gov/pubmed/11751490.

41. Amin MB, Edge SB, Greene FL, et al. AJCC Cancer Staging Manual, 8th edition. New York: Springer; 2017.

42. Zagars GK, Ballo MT, Pisters PWT, et al. Surgical margins and reresection in the management of patients with soft tissue sarcoma using conservative surgery and radiation therapy. Cancer 2003;97:2544-2553. Available at: http://www.ncbi.nlm.nih.gov/pubmed/12733154.

43. O'Donnell PW, Griffin AM, Eward WC, et al. The effect of the setting of a positive surgical margin in soft tissue sarcoma. Cancer 2014;120:2866-2875. Available at: http://www.ncbi.nlm.nih.gov/pubmed/24894656.

44. Gundle KR, Kafchinski L, Gupta S, et al. Analysis of Margin Classification Systems for Assessing the Risk of Local Recurrence After Soft Tissue Sarcoma Resection. J Clin Oncol 2018;36:704-709. Available at: https://www.ncbi.nlm.nih.gov/pubmed/29346043.

45. Kainhofer V, Smolle MA, Szkandera J, et al. The width of resection margins influences local recurrence in soft tissue sarcoma patients. Eur J Surg Oncol 2016;42:899-906. Available at: https://www.ncbi.nlm.nih.gov/pubmed/27107792.

46. Ecker BL, Peters MG, McMillan MT, et al. Implications of Lymph Node Evaluation in the Management of Resectable Soft Tissue Sarcoma. Ann Surg Oncol 2017;24:425-433. Available at: https://www.ncbi.nlm.nih.gov/pubmed/27785659.

47. Naghavi AO, Fernandez DC, Mesko N, et al. American Brachytherapy Society consensus statement for soft tissue sarcoma brachytherapy. Brachytherapy 2017;16:466-489. Available at: https://www.ncbi.nlm.nih.gov/pubmed/28342738.

48. Pohar S, Haq R, Liu L, et al. Adjuvant high-dose-rate and low-dose-rate brachytherapy with external beam radiation in soft tissue sarcoma: a comparison of outcomes. Brachytherapy 2007;6:53-57. Available at: http://www.ncbi.nlm.nih.gov/pubmed/17284387.

49. Leibel SA, Fuks Z, Zelefsky MJ, et al. Intensity-modulated radiotherapy. Cancer J 2002;8:164-176. Available at: http://www.ncbi.nlm.nih.gov/pubmed/12004802.

50. Li XA, Chen X, Zhang Q, et al. Margin reduction from image guided radiation therapy for soft tissue sarcoma: Secondary analysis of Radiation Therapy Oncology Group 0630 results. Pract Radiat Oncol 2016;6:e135-140. Available at: https://www.ncbi.nlm.nih.gov/pubmed/26852173.

51. Wang D, Zhang Q, Eisenberg BL, et al. Significant reduction of late toxicities in patients with extremity sarcoma treated with image-guided radiation therapy to a reduced target volume: Results of Radiation Therapy Oncology Group RTOG-0630 Trial. J Clin Oncol 2015;33:2231-2238. Available at: http://www.ncbi.nlm.nih.gov/pubmed/25667281.

52. Tran PT, Hara W, Su Z, et al. Intraoperative radiation therapy for locally advanced and recurrent soft-tissue sarcomas in adults. Int J

Discussion update in progress

Version 3.2026 © 2026 National Comprehensive Cancer Network® (NCCN©), All rights reserved. NCCN Guidelines® and this illustration may not be reproduced in any form without the express written permission of NCCN.

PLEASE NOTE that use of this NCCN Content is governed by the End-User License Agreement, and you MAY NOT distribute this Content or use it with any artificial intelligence model or tool.
Printed by Ling Lu on 6/26/2026 6:10:47 AM. Copyright © 2026 National Comprehensive Cancer Network, Inc. All Rights Reserved.

Radiat Oncol Biol Phys 2008;72:1146-1153. Available at: http://www.ncbi.nlm.nih.gov/pubmed/18394818.

53. Albertsmeier M, Rauch A, Roeder F, et al. External Beam Radiation Therapy for Resectable Soft Tissue Sarcoma: A Systematic Review and Meta-Analysis. Ann Surg Oncol 2018;25:754-767. Available at: https://www.ncbi.nlm.nih.gov/pubmed/28895107.

54. Davis AM, O'Sullivan B, Turcotte R, et al. Late radiation morbidity following randomization to preoperative versus postoperative radiotherapy in extremity soft tissue sarcoma. Radiother Oncol 2005;75:48-53. Available at: http://www.ncbi.nlm.nih.gov/pubmed/15948265.

55. Nielsen OS, Cummings B, O'Sullivan B, et al. Preoperative and postoperative irradiation of soft tissue sarcomas: effect of radiation field size. Int J Radiat Oncol Biol Phys 1991;21:1595-1599. Available at: https://www.ncbi.nlm.nih.gov/pubmed/1938569.

56. Kuklo TR, Temple HT, Owens BD, et al. Preoperative versus postoperative radiation therapy for soft-tissue sarcomas. Am J Orthop (Belle Mead NJ) 2005;34:75-80. Available at: http://www.ncbi.nlm.nih.gov/pubmed/15789525.

57. Al-Absi E, Farrokhyar F, Sharma R, et al. A systematic review and meta-analysis of oncologic outcomes of pre- versus postoperative radiation in localized resectable soft-tissue sarcoma. Ann Surg Oncol 2010;17:1367-1374. Available at: http://www.ncbi.nlm.nih.gov/pubmed/20217260.

58. Sampath S, Schultheiss TE, Hitchcock YJ, et al. Preoperative versus postoperative radiotherapy in soft-tissue sarcoma: multi-institutional analysis of 821 patients. International journal of radiation oncology, biology, physics 2011;81:498-505. Available at: http://www.ncbi.nlm.nih.gov/pubmed/20888702.

59. Cheng EY, Dusenbery KE, Winters MR, Thompson RC. Soft tissue sarcomas: preoperative versus postoperative radiotherapy. J Surg Oncol 1996;61:90-99. Available at: http://www.ncbi.nlm.nih.gov/pubmed/8606553.

60. Davis AM, O'Sullivan B, Bell RS, et al. Function and health status outcomes in a randomized trial comparing preoperative and postoperative radiotherapy in extremity soft tissue sarcoma. J Clin Oncol 2002;20:4472-4477. Available at: http://www.ncbi.nlm.nih.gov/pubmed/12431971.

61. Griffin AM, Dickie CI, Catton CN, et al. The influence of time interval between preoperative radiation and surgical resection on the development of wound healing complications in extremity soft tissue sarcoma. Ann Surg Oncol 2015;22:2824-2830. Available at: https://www.ncbi.nlm.nih.gov/pubmed/26018726.

62. Zagars GK, Ballo MT, Pisters PWT, et al. Preoperative vs. postoperative radiation therapy for soft tissue sarcoma: a retrospective comparative evaluation of disease outcome. Int J Radiat Oncol Biol Phys 2003;56:482-488. Available at: http://www.ncbi.nlm.nih.gov/pubmed/12738324.

63. Wilson AN, Davis A, Bell RS, et al. Local control of soft tissue sarcoma of the extremity: the experience of a multidisciplinary sarcoma group with definitive surgery and radiotherapy. Eur J Cancer 1994;30A:746-751. Available at: http://www.ncbi.nlm.nih.gov/pubmed/7917531.

64. Delaney TF, Kepka L, Goldberg SI, et al. Radiation therapy for control of soft-tissue sarcomas resected with positive margins. Int J Radiat Oncol Biol Phys 2007;67:1460-1469. Available at: http://www.ncbi.nlm.nih.gov/pubmed/17394945.

65. Al Yami A, Griffin AM, Ferguson PC, et al. Positive surgical margins in soft tissue sarcoma treated with preoperative radiation: is a postoperative boost necessary? Int J Radiat Oncol Biol Phys 2010;77:1191-1197. Available at: http://www.ncbi.nlm.nih.gov/pubmed/20056340.

66. Alamanda VK, Song Y, Shinohara E, et al. Postoperative radiation boost does not improve local recurrence rates in extremity soft tissue sarcomas. J Med Imaging Radiat Oncol 2014;58:633-640. Available at: http://www.ncbi.nlm.nih.gov/pubmed/24821569.

67. Pisters PW, Patel SR, Varma DG, et al. Preoperative chemotherapy for stage IIIB extremity soft tissue sarcoma: long-term results from a

Version 3.2026 © 2026 National Comprehensive Cancer Network® (NCCN®), All rights reserved. NCCN Guidelines® and this illustration may not be reproduced in any form without the express written permission of NCCN.

PLEASE NOTE that use of this NCCN Content is governed by the End-User License Agreement, and you MAY NOT distribute this Content or use it with any artificial intelligence model or tool.
Printed by Ling Lu on 6/26/2026 6:10:47 AM. Copyright © 2026 National Comprehensive Cancer Network, Inc. All Rights Reserved.

single institution. J Clin Oncol 1997;15:3481-3487. Available at: http://www.ncbi.nlm.nih.gov/pubmed/9396401.

68. Gortzak E, Azzarelli A, Buesa J, et al. A randomised phase II study on neo-adjuvant chemotherapy for 'high-risk' adult soft-tissue sarcoma. Eur J Cancer 2001;37:1096-1103. Available at: http://www.ncbi.nlm.nih.gov/pubmed/11378339.

69. Cormier JN, Huang X, Xing Y, et al. Cohort analysis of patients with localized, high-risk, extremity soft tissue sarcoma treated at two cancer centers: chemotherapy-associated outcomes. J Clin Oncol 2004;22:4567-4574. Available at: http://www.ncbi.nlm.nih.gov/pubmed/15542808.

70. Grobmyer SR, Maki RG, Demetri GD, et al. Neo-adjuvant chemotherapy for primary high-grade extremity soft tissue sarcoma. Ann Oncol 2004;15:1667-1672. Available at: http://www.ncbi.nlm.nih.gov/pubmed/15520069.

71. Gronchi A, Ferrari S, Quagliuolo V, et al. Histotype-tailored neoadjuvant chemotherapy versus standard chemotherapy in patients with high-risk soft-tissue sarcomas (ISG-STS 1001): an international, open-label, randomised, controlled, phase 3, multicentre trial. Lancet Oncol 2017;18:812-822. Available at: https://www.ncbi.nlm.nih.gov/pubmed/28499583.

72. Edmonson JH, Petersen IA, Shives TC, et al. Chemotherapy, irradiation, and surgery for function-preserving therapy of primary extremity soft tissue sarcomas: initial treatment with ifosfamide, mitomycin, doxorubicin, and cisplatin plus granulocyte macrophage-colony-stimulating factor. Cancer 2002;94:786-792. Available at: http://www.ncbi.nlm.nih.gov/pubmed/11857314.

73. Pisters PWT, Ballo MT, Patel SR. Preoperative chemoradiation treatment strategies for localized sarcoma. Ann Surg Oncol 2002;9:535-542. Available at: http://www.ncbi.nlm.nih.gov/pubmed/12095968.

74. DeLaney TF, Spiro IJ, Suit HD, et al. Neoadjuvant chemotherapy and radiotherapy for large extremity soft-tissue sarcomas. Int J Radiat Oncol Biol Phys 2003;56:1117-1127. Available at: http://www.ncbi.nlm.nih.gov/pubmed/12829150.

75. Mack LA, Crowe PJ, Yang JL, et al. Preoperative chemoradiotherapy (modified Eilber protocol) provides maximum local control and minimal morbidity in patients with soft tissue sarcoma. Ann Surg Oncol 2005;12:646-653. Available at: http://www.ncbi.nlm.nih.gov/pubmed/15965732.

76. Kraybill WG, Harris J, Spiro IJ, et al. Phase II study of neoadjuvant chemotherapy and radiation therapy in the management of high-risk, high-grade, soft tissue sarcomas of the extremities and body wall: Radiation Therapy Oncology Group Trial 9514. J Clin Oncol 2006;24:619-625. Available at: http://www.ncbi.nlm.nih.gov/pubmed/16446334.

77. Kraybill WG, Harris J, Spiro IJ, et al. Long-term results of a phase 2 study of neoadjuvant chemotherapy and radiotherapy in the management of high-risk, high-grade, soft tissue sarcomas of the extremities and body wall: Radiation Therapy Oncology Group Trial 9514. Cancer 2010;116:4613-4621. Available at: http://www.ncbi.nlm.nih.gov/pubmed/20572040.

78. Mullen JT, Kobayashi W, Wang JJ, et al. Long-term follow-up of patients treated with neoadjuvant chemotherapy and radiotherapy for large, extremity soft tissue sarcomas. Cancer 2012;118:3758-3765. Available at: http://www.ncbi.nlm.nih.gov/pubmed/22180344.

79. Look Hong NJ, Hornicek FJ, Harmon DC, et al. Neoadjuvant chemoradiotherapy for patients with high-risk extremity and truncal sarcomas: a 10-year single institution retrospective study. Eur J Cancer 2013;49:875-883. Available at: http://www.ncbi.nlm.nih.gov/pubmed/23092789.

80. Tseng WW, Zhou S, To CA, et al. Phase 1 adaptive dose-finding study of neoadjuvant gemcitabine combined with radiation therapy for patients with high-risk extremity and trunk soft tissue sarcoma. Cancer 2015;121:3659-3667. Available at: https://www.ncbi.nlm.nih.gov/pubmed/26177983.

81. Davis EJ, Chugh R, Zhao L, et al. A randomised, open-label, phase II study of neo/adjuvant doxorubicin and ifosfamide versus gemcitabine and docetaxel in patients with localised, high-risk, soft tissue sarcoma.

Discussion update in progress

Version 3.2026 © 2026 National Comprehensive Cancer Network® (NCCN©), All rights reserved. NCCN Guidelines® and this illustration may not be reproduced in any form without the express written permission of NCCN.

PLEASE NOTE that use of this NCCN Content is governed by the End-User License Agreement, and you MAY NOT distribute this Content or use it with any artificial intelligence model or tool.
Printed by Ling Lu on 6/26/2026 6:10:47 AM. Copyright © 2026 National Comprehensive Cancer Network, Inc. All Rights Reserved.

Eur J Cancer 2015;51:1794-1802. Available at: https://www.ncbi.nlm.nih.gov/pubmed/26066736.

82. Tierney JF, Mosseri V, Stewart LA, et al. Adjuvant chemotherapy for soft-tissue sarcoma: review and meta-analysis of the published results of randomised clinical trials. Br J Cancer 1995;72:469-475. Available at: http://www.ncbi.nlm.nih.gov/pubmed/7640234.

83. Adjuvant chemotherapy for localised resectable soft-tissue sarcoma of adults: meta-analysis of individual data. Sarcoma Meta-analysis Collaboration. Lancet 1997;350:1647-1654. Available at: http://www.ncbi.nlm.nih.gov/pubmed/9400508

84. Maki RG. Role of chemotherapy in patients with soft tissue sarcomas. Expert Rev Anticancer Ther 2004;4:229-236. Available at: http://www.ncbi.nlm.nih.gov/pubmed/15056053.

85. Pervaiz N, Colterjohn N, Farrokhyar F, et al. A systematic meta-analysis of randomized controlled trials of adjuvant chemotherapy for localized resectable soft-tissue sarcoma. Cancer 2008;113:573-581. Available at: http://www.ncbi.nlm.nih.gov/pubmed/18521899.

86. Italiano A, Delva F, Mathoulin-Pelissier S, et al. Effect of adjuvant chemotherapy on survival in FNCLCC grade 3 soft tissue sarcomas: a multivariate analysis of the French Sarcoma Group Database. Ann Oncol 2010;21:2436-2441. Available at: http://www.ncbi.nlm.nih.gov/pubmed/20439343.

87. Bramwell V, Rouesse J, Steward W, et al. Adjuvant CYVADIC chemotherapy for adult soft tissue sarcoma--reduced local recurrence but no improvement in survival: a study of the European Organization for Research and Treatment of Cancer Soft Tissue and Bone Sarcoma Group. J Clin Oncol 1994;12:1137-1149. Available at: http://www.ncbi.nlm.nih.gov/pubmed/8201375.

88. Frustaci S, Gherlinzoni F, De Paoli A, et al. Adjuvant chemotherapy for adult soft tissue sarcomas of the extremities and girdles: results of the Italian randomized cooperative trial. J Clin Oncol 2001;19:1238-1247. Available at: http://www.ncbi.nlm.nih.gov/pubmed/11230464.

89. Petrioli R, Coratti A, Correale P, et al. Adjuvant epirubicin with or without Ifosfamide for adult soft-tissue sarcoma. Am J Clin Oncol 2002;25:468-473. Available at: http://www.ncbi.nlm.nih.gov/pubmed/12393986.

90. Woll PJ, van Glabbeke M, Hohenberger P, et al. Adjuvant chemotherapy (CT) with doxorubicin and ifosfamide in resected soft tissue sarcoma (STS): Interim analysis of a randomised phase III trial [abstract]. J Clin Oncol 2007;25(18_Suppl):Abstract 10008. Available at: http://meeting.ascopubs.org/cgi/content/abstract/25/18_suppl/10008.

91. Fakhrai N, Ebm C, Kostler WJ, et al. Intensified adjuvant IFADIC chemotherapy in combination with radiotherapy versus radiotherapy alone for soft tissue sarcoma: long-term follow-up of a prospective randomized feasibility trial. Wien Klin Wochenschr 2010;122:614-619. Available at: http://www.ncbi.nlm.nih.gov/pubmed/20963638.

92. Le Cesne A, Ouali M, Leahy MG, et al. Doxorubicin-based adjuvant chemotherapy in soft tissue sarcoma: pooled analysis of two STBSG-EORTC phase III clinical trials. Ann Oncol 2014;25:2425-2432. Available at: http://www.ncbi.nlm.nih.gov/pubmed/25294887.

93. Frustaci S, De Paoli A, Bidoli E, et al. Ifosfamide in the adjuvant therapy of soft tissue sarcomas. Oncology 2003;65 Suppl 2:80-84. Available at: http://www.ncbi.nlm.nih.gov/pubmed/14586155.

94. Mouridsen HT, Bastholt L, Somers R, et al. Adriamycin versus epirubicin in advanced soft tissue sarcomas. A randomized phase II/phase III study of the EORTC Soft Tissue and Bone Sarcoma Group. Eur J Cancer Clin Oncol 1987;23:1477-1483. Available at: http://www.ncbi.nlm.nih.gov/pubmed/3479329.

95. Elias A, Ryan L, Sulkes A, et al. Response to mesna, doxorubicin, ifosfamide, and dacarbazine in 108 patients with metastatic or unresectable sarcoma and no prior chemotherapy. J Clin Oncol 1989;7:1208-1216. Available at: http://www.ncbi.nlm.nih.gov/pubmed/2504890.

96. Antman KH, Elias A. Dana-Farber Cancer Institute studies in advanced sarcoma. Semin Oncol. 1990;1:7-15. Available at: http://www.ncbi.nlm.nih.gov/pubmed/2106162

97. Buesa JM, Mouridsen HT, van Oosterom AT, et al. High-dose DTIC in advanced soft-tissue sarcomas in the adult. A phase II study of the

Version 3.2026 © 2026 National Comprehensive Cancer Network® (NCCN©), All rights reserved. NCCN Guidelines® and this illustration may not be reproduced in any form without the express written permission of NCCN.

PLEASE NOTE that use of this NCCN Content is governed by the End-User License Agreement, and you MAY NOT distribute this Content or use it with any artificial intelligence model or tool.
Printed by Ling Lu on 6/26/2026 6:10:47 AM. Copyright © 2026 National Comprehensive Cancer Network, Inc. All Rights Reserved.

E.O.R.T.C. Soft Tissue and Bone Sarcoma Group. Ann Oncol 1991;2:307-309. Available at: http://www.ncbi.nlm.nih.gov/pubmed/1868027.

98. Antman K, Crowley J, Balcerzak SP, et al. An intergroup phase III randomized study of doxorubicin and dacarbazine with or without ifosfamide and mesna in advanced soft tissue and bone sarcomas. J Clin Oncol 1993;11:1276-1285. Available at: http://www.ncbi.nlm.nih.gov/pubmed/8315425.

99. Bramwell VH, Anderson D, Charette ML, Sarcoma Disease Site Group. Doxorubicin-based chemotherapy for the palliative treatment of adult patients with locally advanced or metastatic soft tissue sarcoma. Cochrane Database Syst Rev 2003:CD003293. Available at: https://www.ncbi.nlm.nih.gov/pubmed/12917960.

100. Edmonson JH, Ryan LM, Blum RH, et al. Randomized comparison of doxorubicin alone versus ifosfamide plus doxorubicin or mitomycin, doxorubicin, and cisplatin against advanced soft tissue sarcomas. J Clin Oncol 1993;11:1269-1275. Available at: http://www.ncbi.nlm.nih.gov/pubmed/8315424.

101. Zalupski M, Metch B, Balcerzak S, et al. Phase III comparison of doxorubicin and dacarbazine given by bolus versus infusion in patients with soft-tissue sarcomas: a Southwest Oncology Group study. J Natl Cancer Inst 1991;83:926-932. Available at: http://www.ncbi.nlm.nih.gov/pubmed/2067035.

102. Santoro A, Tursz T, Mouridsen H, et al. Doxorubicin versus CYVADIC versus doxorubicin plus ifosfamide in first-line treatment of advanced soft tissue sarcomas: a randomized study of the European Organization for Research and Treatment of Cancer Soft Tissue and Bone Sarcoma Group. J Clin Oncol 1995;13:1537-1545. Available at: http://www.ncbi.nlm.nih.gov/pubmed/7602342.

103. Reichardt P, Tilgner J, Hohenberger P, Dorken B. Dose-intensive chemotherapy with ifosfamide, epirubicin, and filgrastim for adult patients with metastatic or locally advanced soft tissue sarcoma: a phase II study. J Clin Oncol 1998;16:1438-1443. Available at: http://www.ncbi.nlm.nih.gov/pubmed/9552049.

104. Palumbo R, Neumaier C, Cosso M, et al. Dose-intensive first-line chemotherapy with epirubicin and continuous infusion ifosfamide in adult patients with advanced soft tissue sarcomas: a phase II study. Eur J Cancer 1999;35:66-72. Available at: http://www.ncbi.nlm.nih.gov/pubmed/10211090.

105. Lorigan P, Verweij J, Papai Z, et al. Phase III trial of two investigational schedules of ifosfamide compared with standard-dose doxorubicin in advanced or metastatic soft tissue sarcoma: a European Organisation for Research and Treatment of Cancer Soft Tissue and Bone Sarcoma Group Study. J Clin Oncol 2007;25:3144-3150. Available at: http://www.ncbi.nlm.nih.gov/pubmed/17634494.

106. Young RJ, Natukunda A, Litiere S, et al. First-line anthracycline-based chemotherapy for angiosarcoma and other soft tissue sarcoma subtypes: pooled analysis of eleven European Organisation for Research and Treatment of Cancer Soft Tissue and Bone Sarcoma Group trials. Eur J Cancer 2014;50:3178-3186. Available at: http://www.ncbi.nlm.nih.gov/pubmed/25459395.

107. Savina M, Le Cesne A, Blay JY, et al. Patterns of care and outcomes of patients with METAstatic soft tissue SARComa in a real-life setting: the METASARC observational study. BMC Med 2017;15:78. Available at: https://www.ncbi.nlm.nih.gov/pubmed/28391775.

108. Bay JO, Ray-Coquard I, Fayette J, et al. Docetaxel and gemcitabine combination in 133 advanced soft-tissue sarcomas: A retrospective analysis. Int J Cancer 2006;119:706-711. Available at: http://www.ncbi.nlm.nih.gov/pubmed/16496406.

109. Maki RG, Wathen JK, Patel SR, et al. Randomized phase II study of gemcitabine and docetaxel compared with gemcitabine alone in patients with metastatic soft tissue sarcomas: results of sarcoma alliance for research through collaboration study 002 [corrected]. J Clin Oncol 2007;25:2755-2763. Available at: http://www.ncbi.nlm.nih.gov/pubmed/17602081.

110. Dileo P, Morgan JA, Zahrieh D, et al. Gemcitabine and vinorelbine combination chemotherapy for patients with advanced soft tissue sarcomas: results of a phase II trial. Cancer 2007;109:1863-1869. Available at: http://www.ncbi.nlm.nih.gov/pubmed/17385194.

Discussion update in progress

Version 3.2026 © 2026 National Comprehensive Cancer Network® (NCCN©), All rights reserved. NCCN Guidelines® and this illustration may not be reproduced in any form without the express written permission of NCCN.

PLEASE NOTE that use of this NCCN Content is governed by the End-User License Agreement, and you MAY NOT distribute this Content or use it with any artificial intelligence model or tool.
Printed by Ling Lu on 6/26/2026 6:10:47 AM. Copyright © 2026 National Comprehensive Cancer Network, Inc. All Rights Reserved.

111. Garcia-Del-Muro X, Lopez-Pousa A, Maurel J, et al. Randomized phase II study comparing gemcitabine plus dacarbazine versus dacarbazine alone in patients with previously treated soft tissue sarcoma: a Spanish Group for Research on Sarcomas study. J Clin Oncol 2011;29:2528-2533. Available at: http://www.ncbi.nlm.nih.gov/pubmed/21606430.

112. Seddon B, Strauss SJ, Whelan J, et al. Gemcitabine and docetaxel versus doxorubicin as first-line treatment in previously untreated advanced unresectable or metastatic soft-tissue sarcomas (GeDDiS): a randomised controlled phase 3 trial. Lancet Oncol 2017;18:1397-1410. Available at: https://www.ncbi.nlm.nih.gov/pubmed/28882536.

113. Talbot SM, Keohan ML, Hesdorffer M, et al. A phase II trial of temozolomide in patients with unresectable or metastatic soft tissue sarcoma. Cancer 2003;98:1942-1946. Available at: http://www.ncbi.nlm.nih.gov/pubmed/14584078.

114. Trent JC, Beach J, Burgess MA, et al. A two-arm phase II study of temozolomide in patients with advanced gastrointestinal stromal tumors and other soft tissue sarcomas. Cancer 2003;98:2693-2699. Available at: http://www.ncbi.nlm.nih.gov/pubmed/14669291.

115. Garcia del Muro X, Lopez-Pousa A, Martin J, et al. A phase II trial of temozolomide as a 6-week, continuous, oral schedule in patients with advanced soft tissue sarcoma: a study by the Spanish Group for Research on Sarcomas. Cancer 2005;104:1706-1712. Available at: http://www.ncbi.nlm.nih.gov/pubmed/16134177.

116. Judson I, Radford JA, Harris M, et al. Randomised phase II trial of pegylated liposomal doxorubicin (DOXIL/CAELYX) versus doxorubicin in the treatment of advanced or metastatic soft tissue sarcoma: a study by the EORTC Soft Tissue and Bone Sarcoma Group. Eur J Cancer 2001;37:870-877. Available at: http://www.ncbi.nlm.nih.gov/pubmed/11313175.

117. Anderson SE, Keohan ML, D'Adamo DR, Maki RG. A retrospective analysis of vinorelbine chemotherapy for patients with previously treated soft-tissue sarcomas. Sarcoma 2006;2006:15947. Available at: https://www.ncbi.nlm.nih.gov/pubmed/17496991.

118. Kuttesch JF, Jr., Krailo MD, Madden T, et al. Phase II evaluation of intravenous vinorelbine (Navelbine) in recurrent or refractory pediatric malignancies: a Children's Oncology Group study. Pediatr Blood Cancer 2009;53:590-593. Available at: http://www.ncbi.nlm.nih.gov/pubmed/19533657.

119. Laverdiere C, Kolb EA, Supko JG, et al. Phase II study of ecteinascidin 743 in heavily pretreated patients with recurrent osteosarcoma. Cancer 2003;98:832-840. Available at: http://www.ncbi.nlm.nih.gov/pubmed/12910529.

120. Yovine A, Riofrio M, Blay JY, et al. Phase II study of ecteinascidin-743 in advanced pretreated soft tissue sarcoma patients. J Clin Oncol 2004;22:890-899. Available at: http://www.ncbi.nlm.nih.gov/pubmed/14990645.

121. Le Cesne A, Blay JY, Judson I, et al. Phase II study of ET-743 in advanced soft tissue sarcomas: a European Organisation for the Research and Treatment of Cancer (EORTC) soft tissue and bone sarcoma group trial. J Clin Oncol 2005;23:576-584. Available at: http://www.ncbi.nlm.nih.gov/pubmed/15659504.

122. Garcia-Carbonero R, Supko JG, Maki RG, et al. Ecteinascidin-743 (ET-743) for chemotherapy-naive patients with advanced soft tissue sarcomas: multicenter phase II and pharmacokinetic study. J Clin Oncol 2005;23:5484-5492. Available at: http://www.ncbi.nlm.nih.gov/pubmed/16110008.

123. Demetri GD, Chawla SP, von Mehren M, et al. Efficacy and safety of trabectedin in patients with advanced or metastatic liposarcoma or leiomyosarcoma after failure of prior anthracyclines and ifosfamide: results of a randomized phase II study of two different schedules. J Clin Oncol 2009;27:4188-4196. Available at: http://www.ncbi.nlm.nih.gov/pubmed/19652065.

124. Cesne AL, Judson I, Maki R, et al. Trabectedin is a feasible treatment for soft tissue sarcoma patients regardless of patient age: a retrospective pooled analysis of five phase II trials. Br J Cancer 2013;109:1717-1724. Available at: http://www.ncbi.nlm.nih.gov/pubmed/24022187.

Discussion update in progress

Version 3.2026 © 2026 National Comprehensive Cancer Network® (NCCN©), All rights reserved. NCCN Guidelines® and this illustration may not be reproduced in any form without the express written permission of NCCN.

PLEASE NOTE that use of this NCCN Content is governed by the End-User License Agreement, and you MAY NOT distribute this Content or use it with any artificial intelligence model or tool.
Printed by Ling Lu on 6/26/2026 6:10:47 AM. Copyright © 2026 National Comprehensive Cancer Network, Inc. All Rights Reserved.

125. Demetri GD, von Mehren M, Jones RL, et al. Efficacy and Safety of Trabectedin or Dacarbazine for Metastatic Liposarcoma or Leiomyosarcoma After Failure of Conventional Chemotherapy: Results of a Phase III Randomized Multicenter Clinical Trial. J Clin Oncol 2016;34:786-793. Available at: https://www.ncbi.nlm.nih.gov/pubmed/26371143.

126. Le Cesne A, Blay JY, Domont J, et al. Interruption versus continuation of trabectedin in patients with soft-tissue sarcoma (T-DIS): a randomised phase 2 trial. Lancet Oncol 2015;16:312-319. Available at: http://www.ncbi.nlm.nih.gov/pubmed/25680558.

127. Kawai A, Araki N, Sugiura H, et al. Trabectedin monotherapy after standard chemotherapy versus best supportive care in patients with advanced, translocation-related sarcoma: a randomised, open-label, phase 2 study. Lancet Oncol 2015;16:406-416. Available at: http://www.ncbi.nlm.nih.gov/pubmed/25795406.

128. Blay JY, Leahy MG, Nguyen BB, et al. Randomised phase III trial of trabectedin versus doxorubicin-based chemotherapy as first-line therapy in translocation-related sarcomas. Eur J Cancer 2014;50:1137-1147. Available at: http://www.ncbi.nlm.nih.gov/pubmed/24512981.

129. Le Cesne A, JY B, Cupissol D, et al. Results of a prospective randomized phase III T-SAR trial comparing trabectedin vs best supportive care (BSC) in patients with pretreated advanced soft tissue sarcoma (ASTS) [abstract]. Presented at the ESMO Congress; Copenhagen.

130. Martin-Broto J, Pousa AL, de Las Penas R, et al. Randomized Phase II Study of Trabectedin and Doxorubicin Compared With Doxorubicin Alone as First-Line Treatment in Patients With Advanced Soft Tissue Sarcomas: A Spanish Group for Research on Sarcoma Study. J Clin Oncol 2016;34:2294-2302. Available at: https://www.ncbi.nlm.nih.gov/pubmed/27185843.

131. Schoffski P, Ray-Coquard IL, Cioffi A, et al. Activity of eribulin mesylate in patients with soft-tissue sarcoma: a phase 2 study in four independent histological subtypes. Lancet Oncol 2011;12:1045-1052. Available at: http://www.ncbi.nlm.nih.gov/pubmed/21937277.

132. Schoffski P, Chawla S, Maki RG, et al. Eribulin versus dacarbazine in previously treated patients with advanced liposarcoma or leiomyosarcoma: a randomised, open-label, multicentre, phase 3 trial. Lancet 2016;387:1629-1637. Available at: https://www.ncbi.nlm.nih.gov/pubmed/26874885.

133. Kollar A, Jones RL, Stacchiotti S, et al. Pazopanib in advanced vascular sarcomas: an EORTC Soft Tissue and Bone Sarcoma Group (STBSG) retrospective analysis. Acta Oncol 2017;56:88-92. Available at: https://www.ncbi.nlm.nih.gov/pubmed/27838944.

134. Sleijfer S, Ray-Coquard I, Papai Z, et al. Pazopanib, a multikinase angiogenesis inhibitor, in patients with relapsed or refractory advanced soft tissue sarcoma: a phase II study from the European organisation for research and treatment of cancer-soft tissue and bone sarcoma group (EORTC study 62043). J Clin Oncol 2009;27:3126-3132. Available at: http://www.ncbi.nlm.nih.gov/pubmed/19451427.

135. van der Graaf WT, Blay JY, Chawla SP, et al. Pazopanib for metastatic soft-tissue sarcoma (PALETTE): a randomised, double-blind, placebo-controlled phase 3 trial. Lancet 2012;379:1879-1886. Available at: http://www.ncbi.nlm.nih.gov/pubmed/22595799.

136. Kawai A, Araki N, Hiraga H, et al. A randomized, double-blind, placebo-controlled, Phase III study of pazopanib in patients with soft tissue sarcoma: results from the Japanese subgroup. Jpn J Clin Oncol 2016;46:248-253. Available at: https://www.ncbi.nlm.nih.gov/pubmed/26864131.

137. Coens C, van der Graaf WT, Blay JY, et al. Health-related quality-of-life results from PALETTE: A randomized, double-blind, phase 3 trial of pazopanib versus placebo in patients with soft tissue sarcoma whose disease has progressed during or after prior chemotherapy-a European Organization for research and treatment of cancer soft tissue and bone sarcoma group global network study (EORTC 62072). Cancer 2015;121:2933-2941. Available at: https://www.ncbi.nlm.nih.gov/pubmed/26033286.

138. Kasper B, Sleijfer S, Litiere S, et al. Long-term responders and survivors on pazopanib for advanced soft tissue sarcomas: subanalysis of two European Organisation for Research and Treatment of Cancer

Version 3.2026 © 2026 National Comprehensive Cancer Network® (NCCN©), All rights reserved. NCCN Guidelines® and this illustration may not be reproduced in any form without the express written permission of NCCN.

PLEASE NOTE that use of this NCCN Content is governed by the End-User License Agreement, and you MAY NOT distribute this Content or use it with any artificial intelligence model or tool.
Printed by Ling Lu on 6/26/2026 6:10:47 AM. Copyright © 2026 National Comprehensive Cancer Network, Inc. All Rights Reserved.

(EORTC) clinical trials 62043 and 62072. Ann Oncol 2014. Available at: http://www.ncbi.nlm.nih.gov/pubmed/24504442.

139. Cassier PA, Gelderblom H, Stacchiotti S, et al. Efficacy of imatinib mesylate for the treatment of locally advanced and/or metastatic tenosynovial giant cell tumor/pigmented villonodular synovitis. Cancer 2012;118:1649-1655. Available at: http://www.ncbi.nlm.nih.gov/pubmed/21823110.

140. Stacchiotti S, Negri T, Libertini M, et al. Sunitinib malate in solitary fibrous tumor (SFT). Ann Oncol 2012;23:3171-3179. Available at: http://www.ncbi.nlm.nih.gov/pubmed/22711763.

141. Stacchiotti S, Negri T, Zaffaroni N, et al. Sunitinib in advanced alveolar soft part sarcoma: evidence of a direct antitumor effect. Ann Oncol 2011;22:1682-1690. Available at: http://www.ncbi.nlm.nih.gov/pubmed/21242589.

142. Valentin T, Fournier C, Penel N, et al. Sorafenib in patients with progressive malignant solitary fibrous tumors: a subgroup analysis from a phase II study of the French Sarcoma Group (GSF/GETO). Invest New Drugs 2013;31:1626-1627. Available at: https://www.ncbi.nlm.nih.gov/pubmed/24005614.

143. Butrynski JE, D'Adamo DR, Hornick JL, et al. Crizotinib in ALK-rearranged inflammatory myofibroblastic tumor. N Engl J Med 2010;363:1727-1733. Available at: http://www.ncbi.nlm.nih.gov/pubmed/20979472.

144. Shaw AT, Kim DW, Mehra R, et al. Ceritinib in ALK-rearranged non-small-cell lung cancer. N Engl J Med 2014;370:1189-1197. Available at: http://www.ncbi.nlm.nih.gov/pubmed/24670165.

145. Bissler JJ, McCormack FX, Young LR, et al. Sirolimus for angiomyolipoma in tuberous sclerosis complex or lymphangioleiomyomatosis. N Engl J Med 2008;358:140-151. Available at: http://www.ncbi.nlm.nih.gov/pubmed/18184959.

146. Wagner AJ, Malinowska-Kolodziej I, Morgan JA, et al. Clinical activity of mTOR inhibition with sirolimus in malignant perivascular epithelioid cell tumors: targeting the pathogenic activation of mTORC1 in tumors. J Clin Oncol 2010;28:835-840. Available at: http://www.ncbi.nlm.nih.gov/pubmed/20048174.

147. Davies DM, de Vries PJ, Johnson SR, et al. Sirolimus therapy for angiomyolipoma in tuberous sclerosis and sporadic lymphangioleiomyomatosis: a phase 2 trial. Clin Cancer Res 2011;17:4071-4081. Available at: http://www.ncbi.nlm.nih.gov/pubmed/21525172.

148. McCormack FX, Inoue Y, Moss J, et al. Efficacy and safety of sirolimus in lymphangioleiomyomatosis. N Engl J Med 2011;364:1595-1606. Available at: http://www.ncbi.nlm.nih.gov/pubmed/21410393.

149. Gennatas C, Michalaki V, Kairi PV, et al. Successful treatment with the mTOR inhibitor everolimus in a patient with perivascular epithelioid cell tumor. World J Surg Oncol 2012;10:181. Available at: http://www.ncbi.nlm.nih.gov/pubmed/22943457.

150. Benson C, Vitfell-Rasmussen J, Maruzzo M, et al. A retrospective study of patients with malignant PEComa receiving treatment with sirolimus or temsirolimus: the Royal Marsden Hospital experience. Anticancer Res 2014;34:3663-3668. Available at: http://www.ncbi.nlm.nih.gov/pubmed/24982384.

151. Italiano A, Delcambre C, Hostein I, et al. Treatment with the mTOR inhibitor temsirolimus in patients with malignant PEComa. Ann Oncol 2010;21:1135-1137. Available at: http://www.ncbi.nlm.nih.gov/pubmed/20215136.

152. Santoro A, Comandone A, Basso U, et al. Phase II prospective study with sorafenib in advanced soft tissue sarcomas after anthracycline-based therapy. Ann Oncol 2013;24:1093-1098. Available at: http://www.ncbi.nlm.nih.gov/pubmed/23230134.

153. Gounder MM, Lefkowitz RA, Keohan ML, et al. Activity of Sorafenib against desmoid tumor/deep fibromatosis. Clin Cancer Res 2011;17:4082-4090. Available at: http://www.ncbi.nlm.nih.gov/pubmed/21447727.

154. Park MS, Patel SR, Ludwig JA, et al. Activity of temozolomide and bevacizumab in the treatment of locally advanced, recurrent, and metastatic hemangiopericytoma and malignant solitary fibrous tumor.

Version 3.2026 © 2026 National Comprehensive Cancer Network® (NCCN©), All rights reserved. NCCN Guidelines® and this illustration may not be reproduced in any form without the express written permission of NCCN.

PLEASE NOTE that use of this NCCN Content is governed by the End-User License Agreement, and you MAY NOT distribute this Content or use it with any artificial intelligence model or tool.
Printed by Ling Lu on 6/26/2026 6:10:47 AM. Copyright © 2026 National Comprehensive Cancer Network, Inc. All Rights Reserved.

Cancer 2011;117:4939-4947. Available at: http://www.ncbi.nlm.nih.gov/pubmed/21480200.

155. Agulnik M, Yarber JL, Okuno SH, et al. An open-label, multicenter, phase II study of bevacizumab for the treatment of angiosarcoma and epithelioid hemangioendotheliomas. Ann Oncol 2013;24:257-263. Available at: http://www.ncbi.nlm.nih.gov/pubmed/22910841.

156. Dickson MA, Tap WD, Keohan ML, et al. Phase II trial of the CDK4 inhibitor PD0332991 in patients with advanced CDK4-amplified well-differentiated or dedifferentiated liposarcoma. J Clin Oncol 2013;31:2024-2028. Available at: http://www.ncbi.nlm.nih.gov/pubmed/23569312.

157. Dickson MA, Tap WD, Keohan ML, et al. Phase II trial of the CDK4 inhibitor PD0332991 in patients with advanced CDK4-amplified liposarcoma [abstract]. ASCO Meeting Abstracts 2013;31:10512. Available at: http://meeting.ascopubs.org/cgi/content/abstract/31/15_suppl/10512.

158. Berry V, Basson L, Bogart E, et al. REGOSARC: Regorafenib versus placebo in doxorubicin-refractory soft-tissue sarcoma-A quality-adjusted time without symptoms of progression or toxicity analysis. Cancer 2017;123:2294-2302. Available at: https://www.ncbi.nlm.nih.gov/pubmed/28295221.

159. Mir O, Brodowicz T, Italiano A, et al. Safety and efficacy of regorafenib in patients with advanced soft tissue sarcoma (REGOSARC): a randomised, double-blind, placebo-controlled, phase 2 trial. Lancet Oncol 2016;17:1732-1742. Available at: https://www.ncbi.nlm.nih.gov/pubmed/27751846.

160. Schwab JH, Boland P, Guo T, et al. Skeletal metastases in myxoid liposarcoma: an unusual pattern of distant spread. Ann Surg Oncol 2007;14:1507-1514. Available at: http://www.ncbi.nlm.nih.gov/pubmed/17252290.

161. Schwab JH, Boland PJ, Antonescu C, et al. Spinal metastases from myxoid liposarcoma warrant screening with magnetic resonance imaging. Cancer 2007;110:1815-1822. Available at: http://www.ncbi.nlm.nih.gov/pubmed/17724681.

162. Tateishi U, Hasegawa T, Beppu Y, et al. Prognostic significance of MRI findings in patients with myxoid-round cell liposarcoma. AJR Am J Roentgenol 2004;182:725-731. Available at: http://www.ncbi.nlm.nih.gov/pubmed/14975976.

163. Portera CA, Jr., Ho V, Patel SR, et al. Alveolar soft part sarcoma: clinical course and patterns of metastasis in 70 patients treated at a single institution. Cancer 2001;91:585-591. Available at: http://www.ncbi.nlm.nih.gov/pubmed/11169942.

164. Eary JF, O'Sullivan F, Powitan Y, et al. Sarcoma tumor FDG uptake measured by PET and patient outcome: a retrospective analysis. Eur J Nucl Med Mol Imaging 2002;29:1149-1154. Available at: http://www.ncbi.nlm.nih.gov/pubmed/12192559.

165. Schuetze SM, Rubin BP, Vernon C, et al. Use of positron emission tomography in localized extremity soft tissue sarcoma treated with neoadjuvant chemotherapy. Cancer 2005;103:339-348. Available at: http://www.ncbi.nlm.nih.gov/pubmed/15578712.

166. Schuetze SM. Utility of positron emission tomography in sarcomas. Curr Opin Oncol 2006;18:369-373. Available at: http://www.ncbi.nlm.nih.gov/pubmed/16721133.

167. Evilevitch V, Weber WA, Tap WD, et al. Reduction of glucose metabolic activity is more accurate than change in size at predicting histopathologic response to neoadjuvant therapy in high-grade soft-tissue sarcomas. Clin Cancer Res 2008;14:715-720. Available at: http://www.ncbi.nlm.nih.gov/pubmed/18245531.

168. Benz MR, Czernin J, Allen-Auerbach MS, et al. FDG-PET/CT imaging predicts histopathologic treatment responses after the initial cycle of neoadjuvant chemotherapy in high-grade soft-tissue sarcomas. Clin Cancer Res 2009;15:2856-2863. Available at: http://www.ncbi.nlm.nih.gov/pubmed/19351756.

169. Quak E, van de Luijtgaarden AC, de Geus-Oei LF, et al. Clinical applications of positron emission tomography in sarcoma management. Expert Rev Anticancer Ther 2011;11:195-204. Available at: http://www.ncbi.nlm.nih.gov/pubmed/21342039.

Version 3.2026 © 2026 National Comprehensive Cancer Network® (NCCN®), All rights reserved. NCCN Guidelines® and this illustration may not be reproduced in any form without the express written permission of NCCN.

PLEASE NOTE that use of this NCCN Content is governed by the End-User License Agreement, and you MAY NOT distribute this Content or use it with any artificial intelligence model or tool.
Printed by Ling Lu on 6/26/2026 6:10:47 AM. Copyright © 2026 National Comprehensive Cancer Network, Inc. All Rights Reserved.

170. Folpe AL, Lyles RH, Sprouse JT, et al. (F-18) fluorodeoxyglucose positron emission tomography as a predictor of pathologic grade and other prognostic variables in bone and soft tissue sarcoma. Clin Cancer Res 2000;6:1279-1287. Available at: http://www.ncbi.nlm.nih.gov/pubmed/10778952.

171. Schwarzbach MH, Dimitrakopoulou-Strauss A, Willeke F, et al. Clinical value of [18-F]] fluorodeoxyglucose positron emission tomography imaging in soft tissue sarcomas. Ann Surg 2000;231:380-386. Available at: http://www.ncbi.nlm.nih.gov/pubmed/10714631.

172. Pisters PW, Leung DH, Woodruff J, et al. Analysis of prognostic factors in 1,041 patients with localized soft tissue sarcomas of the extremities. J Clin Oncol 1996;14:1679-1689. Available at: http://www.ncbi.nlm.nih.gov/pubmed/8622088.

173. Fleming JB, Berman RS, Cheng SC, et al. Long-term outcome of patients with American Joint Committee on Cancer stage IIB extremity soft tissue sarcomas. J Clin Oncol 1999;17:2772-2780. Available at: http://www.ncbi.nlm.nih.gov/pubmed/10561352.

174. Gerrand CH, Wunder JS, Kandel RA, et al. Classification of positive margins after resection of soft-tissue sarcoma of the limb predicts the risk of local recurrence. J Bone Joint Surg Br 2001;83:1149-1155. Available at: http://www.ncbi.nlm.nih.gov/pubmed/11764430.

175. McKee MD, Liu DF, Brooks JJ, et al. The prognostic significance of margin width for extremity and trunk sarcoma. J Surg Oncol 2004;85:68-76. Available at: http://www.ncbi.nlm.nih.gov/pubmed/14755506.

176. Biau DJ, Ferguson PC, Chung P, et al. Local recurrence of localized soft tissue sarcoma: a new look at old predictors. Cancer 2012;118:5867-5877. Available at: http://www.ncbi.nlm.nih.gov/pubmed/22648518.

177. Alamanda VK, Crosby SN, Archer KR, et al. Predictors and clinical significance of local recurrence in extremity soft tissue sarcoma. Acta Oncol 2013;52:793-802. Available at: http://www.ncbi.nlm.nih.gov/pubmed/22877243.

178. Clark MA, Thomas JM. Amputation for soft-tissue sarcoma. Lancet Oncol 2003;4:335-342. Available at: http://www.ncbi.nlm.nih.gov/pubmed/12788405.

179. Rosenberg SA, Tepper J, Glatstein E, et al. The treatment of soft-tissue sarcomas of the extremities: prospective randomized evaluations of (1) limb-sparing surgery plus radiation therapy compared with amputation and (2) the role of adjuvant chemotherapy. Ann Surg 1982;196:305-315. Available at: http://www.ncbi.nlm.nih.gov/pubmed/7114936.

180. Baldini EH, Goldberg J, Jenner C, et al. Long-term outcomes after function-sparing surgery without radiotherapy for soft tissue sarcoma of the extremities and trunk. J Clin Oncol 1999;17:3252-3259. Available at: http://www.ncbi.nlm.nih.gov/pubmed/10506627.

181. Lin PP, Guzel VB, Pisters PW, et al. Surgical management of soft tissue sarcomas of the hand and foot. Cancer 2002;95:852-861. Available at: http://www.ncbi.nlm.nih.gov/pubmed/12209730.

182. Williard WC, Hajdu SI, Casper ES, Brennan MF. Comparison of amputation with limb-sparing operations for adult soft tissue sarcoma of the extremity. Ann Surg 1992;215:269-275. Available at: http://www.ncbi.nlm.nih.gov/pubmed/1543400.

183. Stojadinovic A, Jaques DP, Leung DH, et al. Amputation for recurrent soft tissue sarcoma of the extremity: indications and outcome. Ann Surg Oncol 2001;8:509-518. Available at: http://www.ncbi.nlm.nih.gov/pubmed/11456050.

184. Ghert MA, Abudu A, Driver N, et al. The indications for and the prognostic significance of amputation as the primary surgical procedure for localized soft tissue sarcoma of the extremity. Ann Surg Oncol 2005;12:10-17. Available at: http://www.ncbi.nlm.nih.gov/pubmed/15827772.

185. Alamanda VK, Crosby SN, Archer KR, et al. Amputation for extremity soft tissue sarcoma does not increase overall survival: a retrospective cohort study. Eur J Surg Oncol 2012;38:1178-1183. Available at: http://www.ncbi.nlm.nih.gov/pubmed/22985713.

Discussion update in progress

Version 3.2026 © 2026 National Comprehensive Cancer Network® (NCCN©), All rights reserved. NCCN Guidelines® and this illustration may not be reproduced in any form without the express written permission of NCCN.

PLEASE NOTE that use of this NCCN Content is governed by the End-User License Agreement, and you MAY NOT distribute this Content or use it with any artificial intelligence model or tool.
Printed by Ling Lu on 6/26/2026 6:10:47 AM. Copyright © 2026 National Comprehensive Cancer Network, Inc. All Rights Reserved.

186. Yang JC, Chang AE, Baker AR, et al. Randomized prospective study of the benefit of adjuvant radiation therapy in the treatment of soft tissue sarcomas of the extremity. J Clin Oncol 1998;16:197-203. Available at: http://www.ncbi.nlm.nih.gov/pubmed/9440743.

187. O'Sullivan B, Davis AM, Turcotte R, et al. Preoperative versus postoperative radiotherapy in soft-tissue sarcoma of the limbs: a randomised trial. Lancet 2002;359:2235-2241. Available at: http://www.ncbi.nlm.nih.gov/pubmed/12103287.

188. Alektiar KM, Velasco J, Zelefsky MJ, et al. Adjuvant radiotherapy for margin-positive high-grade soft tissue sarcoma of the extremity. Int J Radiat Oncol Biol Phys 2000;48:1051-1058. Available at: http://www.ncbi.nlm.nih.gov/pubmed/11072162.

189. Jebsen NL, Trovik CS, Bauer HC, et al. Radiotherapy to improve local control regardless of surgical margin and malignancy grade in extremity and trunk wall soft tissue sarcoma: a Scandinavian sarcoma group study. Int J Radiat Oncol Biol Phys 2008;71:1196-1203. Available at: http://www.ncbi.nlm.nih.gov/pubmed/18207661.

190. Kim B, Chen YL, Kirsch DG, et al. An effective preoperative three-dimensional radiotherapy target volume for extremity soft tissue sarcoma and the effect of margin width on local control. Int J Radiat Oncol Biol Phys 2010;77:843-850. Available at: http://www.ncbi.nlm.nih.gov/pubmed/20005638.

191. Gingrich AA, Bateni SB, Monjazeb AM, et al. Neoadjuvant Radiotherapy is Associated with R0 Resection and Improved Survival for Patients with Extremity Soft Tissue Sarcoma Undergoing Surgery: A National Cancer Database Analysis. Ann Surg Oncol 2017;24:3252-3263. Available at: https://www.ncbi.nlm.nih.gov/pubmed/28741123.

192. Pisters PW, Harrison LB, Leung DH, et al. Long-term results of a prospective randomized trial of adjuvant brachytherapy in soft tissue sarcoma. J Clin Oncol 1996;14:859-868. Available at: http://www.ncbi.nlm.nih.gov/pubmed/8622034.

193. Alektiar KM, Leung D, Zelefsky MJ, et al. Adjuvant brachytherapy for primary high-grade soft tissue sarcoma of the extremity. Ann Surg Oncol 2002;9:48-56. Available at: http://www.ncbi.nlm.nih.gov/pubmed/11829430.

194. Alektiar KM, Brennan MF, Healey JH, Singer S. Impact of intensity-modulated radiation therapy on local control in primary soft-tissue sarcoma of the extremity. J Clin Oncol 2008;26:3440-3444. Available at: http://www.ncbi.nlm.nih.gov/pubmed/18612160.

195. Alektiar KM, Brennan MF, Singer S. Local control comparison of adjuvant brachytherapy to intensity-modulated radiotherapy in primary high-grade sarcoma of the extremity. Cancer 2011;117:3229-3234. Available at: http://www.ncbi.nlm.nih.gov/pubmed/21264834.

196. O'Sullivan B, Davis A, Turcotte R, et al. Five-year results of a randomized phase III trial of pre-operative vs post-operative radiotherapy in extremity soft tissue sarcoma [abstract]. J Clin Oncol 2004;22(14_Suppl):Abstract 9007. Available at: http://meeting.jco.org/cgi/content/abstract/22/14_suppl/9007.

197. Beane JD, Yang JC, White D, et al. Efficacy of adjuvant radiation therapy in the treatment of soft tissue sarcoma of the extremity: 20-year follow-up of a randomized prospective trial. Ann Surg Oncol 2014;21:2484-2489. Available at: http://www.ncbi.nlm.nih.gov/pubmed/24756814.

198. Cassier PA, Kantor G, Bonvalot S, et al. Adjuvant radiotherapy for extremity and trunk wall atypical lipomatous tumor/well-differentiated LPS (ALT/WD-LPS): a French Sarcoma Group (GSF-GETO) study. Ann Oncol 2014;25:1854-1860. Available at: http://www.ncbi.nlm.nih.gov/pubmed/24914041.

199. Cahlon O, Spierer M, Brennan MF, et al. Long-term outcomes in extremity soft tissue sarcoma after a pathologically negative re-resection and without radiotherapy. Cancer 2008;112:2774-2779. Available at: http://www.ncbi.nlm.nih.gov/pubmed/18429001.

200. O'Sullivan B, Griffin AM, Dickie CI, et al. Phase 2 study of preoperative image-guided intensity-modulated radiation therapy to reduce wound and combined modality morbidities in lower extremity soft tissue sarcoma. Cancer 2013;119:1878-1884. Available at: http://www.ncbi.nlm.nih.gov/pubmed/23423841.

201. Tran QNH, Kim AC, Gottschalk AR, et al. Clinical outcomes of intraoperative radiation therapy for extremity sarcomas. Sarcoma

Discussion update in progress

Version 3.2026 © 2026 National Comprehensive Cancer Network® (NCCN©), All rights reserved. NCCN Guidelines® and this illustration may not be reproduced in any form without the express written permission of NCCN.

PLEASE NOTE that use of this NCCN Content is governed by the End-User License Agreement, and you MAY NOT distribute this Content or use it with any artificial intelligence model or tool.
Printed by Ling Lu on 6/26/2026 6:10:47 AM. Copyright © 2026 National Comprehensive Cancer Network, Inc. All Rights Reserved.

2006;2006:91671-91671. Available at: http://www.ncbi.nlm.nih.gov/pubmed/17040093.

202. Call JA, Stafford SL, Petersen IA, Haddock MG. Use of intraoperative radiotherapy for upper-extremity soft-tissue sarcomas: analysis of disease outcomes and toxicity. Am J Clin Oncol 2014;37:81-85. Available at: http://www.ncbi.nlm.nih.gov/pubmed/23111357.

203. Calvo FA, Sole CV, Polo A, et al. Limb-sparing management with surgical resection, external-beam and intraoperative electron-beam radiation therapy boost for patients with primary soft tissue sarcoma of the extremity: a multicentric pooled analysis of long-term outcomes. Strahlenther Onkol 2014;190:891-898. Available at: http://www.ncbi.nlm.nih.gov/pubmed/24715241.

204. Sole CV, Calvo FA, Cambeiro M, et al. Intraoperative radiotherapy-containing multidisciplinary management of trunk-wall soft-tissue sarcomas. Clin Transl Oncol 2014;16:834-842. Available at: http://www.ncbi.nlm.nih.gov/pubmed/24481721.

205. Pan E, Goldberg SI, Chen YL, et al. Role of post-operative radiation boost for soft tissue sarcomas with positive margins following pre-operative radiation and surgery. J Surg Oncol 2014;110:817-822. Available at: https://www.ncbi.nlm.nih.gov/pubmed/25111884.

206. Geer RJ, Woodruff J, Casper ES, Brennan MF. Management of small soft-tissue sarcoma of the extremity in adults. Arch Surg 1992;127:1285-1289. Available at: http://www.ncbi.nlm.nih.gov/pubmed/1444788.

207. Karakousis CP, Emrich LJ, Rao U, Khalil M. Limb salvage in soft tissue sarcomas with selective combination of modalities. Eur J Surg Oncol 1991;17:71-80. Available at: http://www.ncbi.nlm.nih.gov/pubmed/1995362.

208. Billing V, Mertens F, Domanski HA, Rydholm A. Deep-seated ordinary and atypical lipomas: histopathology, cytogenetics, clinical features, and outcome in 215 tumours of the extremity and trunk wall. J Bone Joint Surg Br 2008;90:929-933. Available at: http://www.ncbi.nlm.nih.gov/pubmed/18591605.

209. Sommerville SMM, Patton JT, Luscombe JC, et al. Clinical outcomes of deep atypical lipomas (well-differentiated lipoma-like liposarcomas) of the extremities. ANZ J Surg 2005;75:803-806. Available at: http://www.ncbi.nlm.nih.gov/pubmed/16173997.

210. Kooby DA, Antonescu CR, Brennan MF, Singer S. Atypical lipomatous tumor/well-differentiated liposarcoma of the extremity and trunk wall: importance of histological subtype with treatment recommendations. Ann Surg Oncol 2004;11:78-84. Available at: http://www.ncbi.nlm.nih.gov/pubmed/14699038.

211. Kang J, Botros M, Goldberg S, et al. The use of radiation therapy in the management of selected patients with atypical lipomas. Sarcoma 2013;2013:485483-485483. Available at: http://www.ncbi.nlm.nih.gov/pubmed/23401663.

212. Issels RD, Lindner LH, Verweij J, et al. Neo-adjuvant chemotherapy alone or with regional hyperthermia for localised high-risk soft-tissue sarcoma: a randomised phase 3 multicentre study. Lancet Oncol 2010;11:561-570. Available at: https://www.ncbi.nlm.nih.gov/pubmed/20434400.

213. Pisters PW, Pollock RE, Lewis VO, et al. Long-term results of prospective trial of surgery alone with selective use of radiation for patients with T1 extremity and trunk soft tissue sarcomas. Ann Surg 2007;246:675-681; discussion 681-682. Available at: http://www.ncbi.nlm.nih.gov/pubmed/17893504.

214. Al-Refaie WB, Habermann EB, Jensen EH, et al. Surgery alone is adequate treatment for early stage soft tissue sarcoma of the extremity. Br J Surg 2010;97:707-713. Available at: http://www.ncbi.nlm.nih.gov/pubmed/20235085.

215. Kachare SD, Brinkley J, Vohra NA, et al. Radiotherapy associated with improved survival for high-grade sarcoma of the extremity. J Surg Oncol 2015;112:338-343. Available at: https://www.ncbi.nlm.nih.gov/pubmed/26250782.

216. Fong Y, Coit DG, Woodruff JM, Brennan MF. Lymph node metastasis from soft tissue sarcoma in adults. Analysis of data from a prospective database of 1772 sarcoma patients. Ann Surg 1993;217:72-77. Available at: http://www.ncbi.nlm.nih.gov/pubmed/8424704.

Version 3.2026 © 2026 National Comprehensive Cancer Network® (NCCN©), All rights reserved. NCCN Guidelines® and this illustration may not be reproduced in any form without the express written permission of NCCN.

PLEASE NOTE that use of this NCCN Content is governed by the End-User License Agreement, and you MAY NOT distribute this Content or use it with any artificial intelligence model or tool.
Printed by Ling Lu on 6/26/2026 6:10:47 AM. Copyright © 2026 National Comprehensive Cancer Network, Inc. All Rights Reserved.

217. Judson I, Verweij J, Gelderblom H, et al. Doxorubicin alone versus intensified doxorubicin plus ifosfamide for first-line treatment of advanced or metastatic soft-tissue sarcoma: a randomised controlled phase 3 trial. Lancet Oncol 2014;15:415-423. Available at: http://www.ncbi.nlm.nih.gov/pubmed/24618336.

218. Young RJ, Litiere S, Lia M, et al. Predictive and prognostic factors associated with soft tissue sarcoma response to chemotherapy: a subgroup analysis of the European Organisation for Research and Treatment of Cancer 62012 study. Acta Oncol 2017;56:1013-1020. Available at: https://www.ncbi.nlm.nih.gov/pubmed/28431480.

219. Kepka L, DeLaney TF, Suit HD, Goldberg SI. Results of radiation therapy for unresected soft-tissue sarcomas. Int J Radiat Oncol Biol Phys 2005;63:852-859. Available at: http://www.ncbi.nlm.nih.gov/pubmed/16199316.

220. Grunhagen DJ, de Wilt JHW, Graveland WJ, et al. Outcome and prognostic factor analysis of 217 consecutive isolated limb perfusions with tumor necrosis factor-alpha and melphalan for limb-threatening soft tissue sarcoma. Cancer 2006;106:1776-1784. Available at: http://www.ncbi.nlm.nih.gov/pubmed/16541435.

221. Wray CJ, Benjamin RS, Hunt KK, et al. Isolated limb perfusion for unresectable extremity sarcoma: Results of 2 single-institution phase 2 trials. Cancer 2011;117:3235-3241. Available at: http://www.ncbi.nlm.nih.gov/pubmed/21246524.

222. Deroose JP, Eggermont AMM, van Geel AN, et al. Long-term results of tumor necrosis factor alpha- and melphalan-based isolated limb perfusion in locally advanced extremity soft tissue sarcomas. J Clin Oncol 2011;29:4036-4044. Available at: http://www.ncbi.nlm.nih.gov/pubmed/21931039.

223. Bhangu A, Broom L, Nepogodiev D, et al. Outcomes of isolated limb perfusion in the treatment of extremity soft tissue sarcoma: a systematic review. Eur J Surg Oncol 2013;39:311-319. Available at: http://www.ncbi.nlm.nih.gov/pubmed/23351681.

224. Hegazy MAF, Kotb SZ, Sakr H, et al. Preoperative isolated limb infusion of doxorubicin and external irradiation for limb-threatening soft tissue sarcomas. Ann Surg Oncol 2007;14:568-576. Available at: http://www.ncbi.nlm.nih.gov/pubmed/17094027.

225. Moncrieff MD, Kroon HM, Kam PC, et al. Isolated limb infusion for advanced soft tissue sarcoma of the extremity. Ann Surg Oncol 2008;15:2749-2756. Available at: http://www.ncbi.nlm.nih.gov/pubmed/18648882.

226. Brady MS, Brown K, Patel A, et al. Isolated limb infusion with melphalan and dactinomycin for regional melanoma and soft-tissue sarcoma of the extremity: final report of a phase II clinical trial. Melanoma Res 2009;19:106-111. Available at: http://www.ncbi.nlm.nih.gov/pubmed/19282789.

227. Turaga KK, Beasley GM, Kane JM, et al. Limb preservation with isolated limb infusion for locally advanced nonmelanoma cutaneous and soft-tissue malignant neoplasms. Arch Surg 2011;146:870-875. Available at: http://www.ncbi.nlm.nih.gov/pubmed/21768436.

228. Mullinax JE, Kroon HM, Thompson JF, et al. Isolated Limb Infusion as a Limb Salvage Strategy for Locally Advanced Extremity Sarcoma. J Am Coll Surg 2017;224:635-642. Available at: https://www.ncbi.nlm.nih.gov/pubmed/28214556.

229. Neuwirth MG, Song Y, Sinnamon AJ, et al. Isolated Limb Perfusion and Infusion for Extremity Soft Tissue Sarcoma: A Contemporary Systematic Review and Meta-Analysis. Ann Surg Oncol 2017;24:3803-3810. Available at: https://www.ncbi.nlm.nih.gov/pubmed/29022281.

230. Kane JM, Finley JW, Driscoll D, et al. The treatment and outcome of patients with soft tissue sarcomas and synchronous metastases. Sarcoma 2002;6:69-73. Available at: http://www.ncbi.nlm.nih.gov/pubmed/18521331.

231. Ferguson PC, Deheshi BM, Chung P, et al. Soft tissue sarcoma presenting with metastatic disease: outcome with primary surgical resection. Cancer 2011;117:372-379. Available at: http://www.ncbi.nlm.nih.gov/pubmed/20830769.

232. Okiror L, Peleki A, Moffat D, et al. Survival following Pulmonary Metastasectomy for Sarcoma. Thorac Cardiovasc Surg 2016;64:146-149. Available at: https://www.ncbi.nlm.nih.gov/pubmed/25742552.

Discussion update in progress

Version 3.2026 © 2026 National Comprehensive Cancer Network® (NCCN®), All rights reserved. NCCN Guidelines® and this illustration may not be reproduced in any form without the express written permission of NCCN.

PLEASE NOTE that use of this NCCN Content is governed by the End-User License Agreement, and you MAY NOT distribute this Content or use it with any artificial intelligence model or tool.
Printed by Ling Lu on 6/26/2026 6:10:47 AM. Copyright © 2026 National Comprehensive Cancer Network, Inc. All Rights Reserved.

233. Chudgar NP, Brennan MF, Tan KS, et al. Is Repeat Pulmonary Metastasectomy Indicated for Soft Tissue Sarcoma? Ann Thorac Surg 2017;104:1837-1845. Available at: https://www.ncbi.nlm.nih.gov/pubmed/29074153.

234. Baumann BC, Nagda SN, Kolker JD, et al. Efficacy and safety of stereotactic body radiation therapy for the treatment of pulmonary metastases from sarcoma: A potential alternative to resection. J Surg Oncol 2016;114:65-69. Available at: https://www.ncbi.nlm.nih.gov/pubmed/27111504.

235. Dhakal S, Corbin KS, Milano MT, et al. Stereotactic body radiotherapy for pulmonary metastases from soft-tissue sarcomas: excellent local lesion control and improved patient survival. Int J Radiat Oncol Biol Phys 2012;82:940-945. Available at: https://www.ncbi.nlm.nih.gov/pubmed/21277105.

236. Navarria P, Ascolese AM, Cozzi L, et al. Stereotactic body radiation therapy for lung metastases from soft tissue sarcoma. Eur J Cancer 2015;51:668-674. Available at: https://www.ncbi.nlm.nih.gov/pubmed/25686482.

237. Whooley BP, Mooney MM, Gibbs JF, Kraybill WG. Effective follow-up strategies in soft tissue sarcoma. Semin Surg Oncol 1999;17:83-87. Available at: http://www.ncbi.nlm.nih.gov/pubmed/10402642.

238. Whooley BP, Gibbs JF, Mooney MM, et al. Primary extremity sarcoma: what is the appropriate follow-up? Ann Surg Oncol 2000;7:9-14. Available at: http://www.ncbi.nlm.nih.gov/pubmed/10674442.

239. Kane JM, 3rd. Surveillance strategies for patients following surgical resection of soft tissue sarcomas. Curr Opin Oncol 2004;16:328-332. Available at: http://www.ncbi.nlm.nih.gov/pubmed/15187887.

240. Patel SA, Royce TJ, Barysauskas CM, et al. Surveillance Imaging Patterns and Outcomes Following Radiation Therapy and Radical Resection for Localized Extremity and Trunk Soft Tissue Sarcoma. Ann Surg Oncol 2017. Available at: https://www.ncbi.nlm.nih.gov/pubmed/28058559.

241. Lewis JJ, Leung D, Casper ES, et al. Multifactorial analysis of long-term follow-up (more than 5 years) of primary extremity sarcoma. Arch Surg 1999;134:190-194. Available at: http://www.ncbi.nlm.nih.gov/pubmed/10025462.

242. Fleming JB, Cantor SB, Varma DG, et al. Utility of chest computed tomography for staging in patients with T1 extremity soft tissue sarcomas. Cancer 2001;92:863-868. Available at: http://www.ncbi.nlm.nih.gov/pubmed/11550159.

243. Choi H, Varma DG, Fornage BD, et al. Soft-tissue sarcoma: MR imaging vs sonography for detection of local recurrence after surgery. AJR Am J Roentgenol 1991;157:353-358. Available at: http://www.ncbi.nlm.nih.gov/pubmed/1853821.

244. Arya S, Nagarkatti DG, Dudhat SB, et al. Soft tissue sarcomas: ultrasonographic evaluation of local recurrences. Clin Radiol 2000;55:193-197. Available at: http://www.ncbi.nlm.nih.gov/pubmed/10708612.

245. Briccoli A, Galletti S, Salone M, et al. Ultrasonography is superior to computed tomography and magnetic resonance imaging in determining superficial resection margins of malignant chest wall tumors. J Ultrasound Med 2007;26:157-162. Available at: http://www.ncbi.nlm.nih.gov/pubmed/17255176.

246. Cheney MD, Giraud C, Goldberg SI, et al. MRI surveillance following treatment of extremity soft tissue sarcoma. J Surg Oncol 2014;109:593-596. Available at: http://www.ncbi.nlm.nih.gov/pubmed/24374823.

247. Billingsley KG, Burt ME, Jara E, et al. Pulmonary metastases from soft tissue sarcoma: analysis of patterns of diseases and postmetastasis survival. Ann Surg 1999;229:602-610. Available at: http://www.ncbi.nlm.nih.gov/pubmed/10235518.

248. Zagars GK, Ballo MT, Pisters PWT, et al. Prognostic factors for disease-specific survival after first relapse of soft-tissue sarcoma: analysis of 402 patients with disease relapse after initial conservative surgery and radiotherapy. Int J Radiat Oncol Biol Phys 2003;57:739-747. Available at: http://www.ncbi.nlm.nih.gov/pubmed/14529779.

249. Kim S, Ott HC, Wright CD, et al. Pulmonary resection of metastatic sarcoma: prognostic factors associated with improved outcomes. Ann

Version 3.2026 © 2026 National Comprehensive Cancer Network® (NCCN©), All rights reserved. NCCN Guidelines® and this illustration may not be reproduced in any form without the express written permission of NCCN.

PLEASE NOTE that use of this NCCN Content is governed by the End-User License Agreement, and you MAY NOT distribute this Content or use it with any artificial intelligence model or tool.
Printed by Ling Lu on 6/26/2026 6:10:47 AM. Copyright © 2026 National Comprehensive Cancer Network, Inc. All Rights Reserved.

Thorac Surg 2011;92:1780-1786. Available at: http://www.ncbi.nlm.nih.gov/pubmed/22051274.

250. Singer S, Antman K, Corson JM, Eberlein TJ. Long-term salvageability for patients with locally recurrent soft-tissue sarcomas. Arch Surg 1992;127:548-553. Available at: http://www.ncbi.nlm.nih.gov/pubmed/1575625.

251. Catton C, Davis A, Bell R, et al. Soft tissue sarcoma of the extremity. Limb salvage after failure of combined conservative therapy. Radiother Oncol 1996;41:209-214. Available at: http://www.ncbi.nlm.nih.gov/pubmed/9027935.

252. Torres MA, Ballo MT, Butler CE, et al. Management of locally recurrent soft-tissue sarcoma after prior surgery and radiation therapy. Int J Radiat Oncol Biol Phys 2007;67:1124-1129. Available at: http://www.ncbi.nlm.nih.gov/pubmed/17208389.

253. Canter RJ, Qin LX, Downey RJ, et al. Perioperative chemotherapy in patients undergoing pulmonary resection for metastatic soft-tissue sarcoma of the extremity : a retrospective analysis. Cancer 2007;110:2050-2060. Available at: http://www.ncbi.nlm.nih.gov/pubmed/17828771.

254. Musat E, Kantor G, Caron J, et al. Comparison of intensity-modulated postoperative radiotherapy with conventional postoperative conformal radiotherapy for retroperitoneal sarcoma [in French]. Cancer Radiother 2004;8:255-261. Available at: http://www.ncbi.nlm.nih.gov/pubmed/15450519.

255. Yoon SS, Chen YL, Kirsch DG, et al. Proton-beam, intensity-modulated, and/or intraoperative electron radiation therapy combined with aggressive anterior surgical resection for retroperitoneal sarcomas. Ann Surg Oncol 2010;17:1515-1529. Available at: http://www.ncbi.nlm.nih.gov/pubmed/20151216.

256. Swanson EL, Indelicato DJ, Louis D, et al. Comparison of three-dimensional (3D) conformal proton radiotherapy (RT), 3D conformal photon RT, and intensity-modulated RT for retroperitoneal and intra-abdominal sarcomas. Int J Radiat Oncol Biol Phys 2012;83:1549-1557. Available at: http://www.ncbi.nlm.nih.gov/pubmed/22270176.

257. Trans-Atlantic RPS Working Group. Management of primary retroperitoneal sarcoma (RPS) in the adult: a consensus approach from the Trans-Atlantic RPS Working Group. Ann Surg Oncol 2015;22:256-263. Available at: https://www.ncbi.nlm.nih.gov/pubmed/25316486.

258. Zlotecki RA, Katz TS, Morris CG, et al. Adjuvant radiation therapy for resectable retroperitoneal soft tissue sarcoma: the University of Florida experience. Am J Clin Oncol 2005;28:310-316. Available at: http://www.ncbi.nlm.nih.gov/pubmed/15923806.

259. Baldini EH, Wang D, Haas RL, et al. Treatment Guidelines for Preoperative Radiation Therapy for Retroperitoneal Sarcoma: Preliminary Consensus of an International Expert Panel. Int J Radiat Oncol Biol Phys 2015;92:602-612. Available at: https://www.ncbi.nlm.nih.gov/pubmed/26068493.

260. Pawlik TM, Pisters PWT, Mikula L, et al. Long-term results of two prospective trials of preoperative external beam radiotherapy for localized intermediate- or high-grade retroperitoneal soft tissue sarcoma. Ann Surg Oncol 2006;13:508-517. Available at: http://www.ncbi.nlm.nih.gov/pubmed/16491338.

261. Bonvalot S, Gronchi A, Le Pechoux C, et al. Preoperative radiotherapy plus surgery versus surgery alone for patients with primary retroperitoneal sarcoma (EORTC-62092: STRASS): a multicentre, open-label, randomised, phase 3 trial. Lancet Oncol 2020;21:1366-1377. Available at: https://www.ncbi.nlm.nih.gov/pubmed/32941794.

262. Chowdhary M, Spraker MB. Preoperative radiotherapy for retroperitoneal sarcoma. Lancet Oncol 2021;22:e2. Available at: https://www.ncbi.nlm.nih.gov/pubmed/33387501.

263. DeLaney T, Mullen JT, Wang D, et al. Preoperative radiotherapy for retroperitoneal sarcoma. Lancet Oncol 2021;22:e1. Available at: https://www.ncbi.nlm.nih.gov/pubmed/33387499.

264. Izzuddeen Y, Sharma DN. Preoperative radiotherapy for retroperitoneal sarcoma. Lancet Oncol 2021;22:e3. Available at: https://www.ncbi.nlm.nih.gov/pubmed/33387503.

265. Baldini EH, Bosch W, Kane JM, 3rd, et al. Retroperitoneal sarcoma (RPS) high risk gross tumor volume boost (HR GTV boost) contour

Discussion update in progress

Version 3.2026 © 2026 National Comprehensive Cancer Network® (NCCN©), All rights reserved. NCCN Guidelines® and this illustration may not be reproduced in any form without the express written permission of NCCN.

PLEASE NOTE that use of this NCCN Content is governed by the End-User License Agreement, and you MAY NOT distribute this Content or use it with any artificial intelligence model or tool.
Printed by Ling Lu on 6/26/2026 6:10:47 AM. Copyright © 2026 National Comprehensive Cancer Network, Inc. All Rights Reserved.

delineation agreement among NRG sarcoma radiation and surgical oncologists. Ann Surg Oncol 2015;22:2846-2852. Available at: https://www.ncbi.nlm.nih.gov/pubmed/26018727.

266. Tzeng CW, Fiveash JB, Popple RA, et al. Preoperative radiation therapy with selective dose escalation to the margin at risk for retroperitoneal sarcoma. Cancer 2006;107:371-379. Available at: http://www.ncbi.nlm.nih.gov/pubmed/16752414.

267. Sindelar WF, Kinsella TJ, Chen PW, et al. Intraoperative radiotherapy in retroperitoneal sarcomas. Final results of a prospective, randomized, clinical trial. Arch Surg 1993;128:402-410. Available at: http://www.ncbi.nlm.nih.gov/pubmed/8457152.

268. Alektiar KM, Hu K, Anderson L, et al. High-dose-rate intraoperative radiation therapy (HDR-IORT) for retroperitoneal sarcomas. Int J Radiat Oncol Biol Phys 2000;47:157-163. Available at: http://www.ncbi.nlm.nih.gov/pubmed/10758318.

269. Gieschen HL, Spiro IJ, Suit HD, et al. Long-term results of intraoperative electron beam radiotherapy for primary and recurrent retroperitoneal soft tissue sarcoma. Int J Radiat Oncol Biol Phys 2001;50:127-131. Available at: http://www.ncbi.nlm.nih.gov/pubmed/11316555.

270. Petersen IA, Haddock MG, Donohue JH, et al. Use of intraoperative electron beam radiotherapy in the management of retroperitoneal soft tissue sarcomas. Int J Radiat Oncol Biol Phys 2002;52:469-475. Available at: http://www.ncbi.nlm.nih.gov/pubmed/11872294.

271. Bobin JY, Al-Lawati T, Granero LE, et al. Surgical management of retroperitoneal sarcomas associated with external and intraoperative electron beam radiotherapy. Eur J Surg Oncol 2003;29:676-681. Available at: http://www.ncbi.nlm.nih.gov/pubmed/14511617.

272. Pisters PWT, Ballo MT, Fenstermacher MJ, et al. Phase I trial of preoperative concurrent doxorubicin and radiation therapy, surgical resection, and intraoperative electron-beam radiation therapy for patients with localized retroperitoneal sarcoma. J Clin Oncol 2003;21:3092-3097. Available at: http://www.ncbi.nlm.nih.gov/pubmed/12915599.

273. Krempien R, Roeder F, Oertel S, et al. Intraoperative electron-beam therapy for primary and recurrent retroperitoneal soft-tissue sarcoma. Int J Radiat Oncol Biol Phys 2006;65:773-779. Available at: http://www.ncbi.nlm.nih.gov/pubmed/16682152.

274. Stucky CC, Wasif N, Ashman JB, et al. Excellent local control with preoperative radiation therapy, surgical resection, and intra-operative electron radiation therapy for retroperitoneal sarcoma. J Surg Oncol 2014;109:798-803. Available at: http://www.ncbi.nlm.nih.gov/pubmed/24862926.

275. Roeder F, Ulrich A, Habl G, et al. Clinical phase I/II trial to investigate preoperative dose-escalated intensity-modulated radiation therapy (IMRT) and intraoperative radiation therapy (IORT) in patients with retroperitoneal soft tissue sarcoma: interim analysis. BMC Cancer 2014;14:617. Available at: http://www.ncbi.nlm.nih.gov/pubmed/25163595.

276. ClinicalTrials.gov. Available at: https://www.clinicaltrials.gov/. Accessed April 13, 2022.

277. Patel S, von Mehren M, Reed DR, et al. Overall survival and histology-specific subgroup analyses from a phase 3, randomized controlled study of trabectedin or dacarbazine in patients with advanced liposarcoma or leiomyosarcoma. Cancer 2019;125:2610-2620. Available at: https://www.ncbi.nlm.nih.gov/pubmed/31173362.

278. Toulmonde M, Pulido M, Ray-Coquard I, et al. Pazopanib or methotrexate-vinblastine combination chemotherapy in adult patients with progressive desmoid tumours (DESMOPAZ): a non-comparative, randomised, open-label, multicentre, phase 2 study. Lancet Oncol 2019;20:1263-1272. Available at: https://www.ncbi.nlm.nih.gov/pubmed/31331699.

279. Stacchiotti S, Mir O, Le Cesne A, et al. Activity of Pazopanib and Trabectedin in Advanced Alveolar Soft Part Sarcoma. Oncologist 2018;23:62-70. Available at: https://www.ncbi.nlm.nih.gov/pubmed/28754721.

280. Ebata T, Shimoi T, Bun S, et al. Efficacy and Safety of Pazopanib for Recurrent or Metastatic Solitary Fibrous Tumor. Oncology

Version 3.2026 © 2026 National Comprehensive Cancer Network® (NCCN®), All rights reserved. NCCN Guidelines® and this illustration may not be reproduced in any form without the express written permission of NCCN.

PLEASE NOTE that use of this NCCN Content is governed by the End-User License Agreement, and you MAY NOT distribute this Content or use it with any artificial intelligence model or tool.
Printed by Ling Lu on 6/26/2026 6:10:47 AM. Copyright © 2026 National Comprehensive Cancer Network, Inc. All Rights Reserved.

2018;94:340-344. Available at: https://www.ncbi.nlm.nih.gov/pubmed/29614488.

281. Grunwald V, Karch A, Schuler M, et al. Randomized Comparison of Pazopanib and Doxorubicin as First-Line Treatment in Patients With Metastatic Soft Tissue Sarcoma Age 60 Years or Older: Results of a German Intergroup Study. J Clin Oncol 2020;38:3555-3564. Available at: https://www.ncbi.nlm.nih.gov/pubmed/32840417.

282. Somaiah N, Van Tine BA, Wahlquist AE, et al. A randomized, open-label, phase 2, multicenter trial of gemcitabine with pazopanib or gemcitabine with docetaxel in patients with advanced soft-tissue sarcoma. Cancer 2021;127:894-904. Available at: https://www.ncbi.nlm.nih.gov/pubmed/33231866.

283. Agulnik M, Schulte B, Robinson S, et al. An open-label single-arm phase II study of regorafenib for the treatment of angiosarcoma. Eur J Cancer 2021;154:201-208. Available at: https://www.ncbi.nlm.nih.gov/pubmed/34284255.

284. Doebele RC, Drilon A, Paz-Ares L, et al. Entrectinib in patients with advanced or metastatic NTRK fusion-positive solid tumours: integrated analysis of three phase 1-2 trials. Lancet Oncol 2020;21:271-282. Available at: https://www.ncbi.nlm.nih.gov/pubmed/31838007.

285. Drilon A, Laetsch TW, Kummar S, et al. Efficacy of Larotrectinib in TRK Fusion-Positive Cancers in Adults and Children. N Engl J Med 2018;378:731-739. Available at: https://www.ncbi.nlm.nih.gov/pubmed/29466156.

286. Prescribing Information for Pembrolizumab injection for intravenous use. 2022. Available at: https://www.accessdata.fda.gov/drugsatfda_docs/label/2022/125514s125lbl.pdf. Accessed March 11, 2022.

287. Burgess MA, Bolejack V, Van Tine BA, et al. Multicenter phase II study of pembrolizumab (P) in advanced soft tissue (STS) and bone sarcomas (BS): Final results of SARC028 and biomarker analyses. Journal of Clinical Oncology 2017;35:11008-11008. Available at: https://doi.org/10.1200/JCO.2017.35.15_suppl.11008.

288. Florou V, Rosenberg AE, Wieder E, et al. Angiosarcoma patients treated with immune checkpoint inhibitors: a case series of seven patients from a single institution. J Immunother Cancer 2019;7:213. Available at: https://www.ncbi.nlm.nih.gov/pubmed/31395100.

289. Anaya DA, Lev DC, Pollock RE. The role of surgical margin status in retroperitoneal sarcoma. J Surg Oncol 2008;98:607-610. Available at: http://www.ncbi.nlm.nih.gov/pubmed/19072853.

290. Bevilacqua RG, Rogatko A, Hajdu SI, Brennan MF. Prognostic factors in primary retroperitoneal soft-tissue sarcomas. Arch Surg 1991;126:328-334. Available at: http://www.ncbi.nlm.nih.gov/pubmed/1998475.

291. Heslin MJ, Lewis JJ, Nadler E, et al. Prognostic factors associated with long-term survival for retroperitoneal sarcoma: implications for management. J Clin Oncol 1997;15:2832-2839. Available at: http://www.ncbi.nlm.nih.gov/pubmed/9256126.

292. Lewis JJ, Leung D, Woodruff JM, Brennan MF. Retroperitoneal soft-tissue sarcoma: analysis of 500 patients treated and followed at a single institution. Ann Surg 1998;228:355-365. Available at: http://www.ncbi.nlm.nih.gov/pubmed/9742918.

293. Bremjit PJ, Jones RL, Chai X, et al. A contemporary large single-institution evaluation of resected retroperitoneal sarcoma. Ann Surg Oncol 2014;21:2150-2158. Available at: http://www.ncbi.nlm.nih.gov/pubmed/24615180.

294. Bonvalot S, Rivoire M, Castaing M, et al. Primary retroperitoneal sarcomas: a multivariate analysis of surgical factors associated with local control. J Clin Oncol 2009;27:31-37. Available at: http://www.ncbi.nlm.nih.gov/pubmed/19047280.

295. Gronchi A, Lo Vullo S, Fiore M, et al. Aggressive surgical policies in a retrospectively reviewed single-institution case series of retroperitoneal soft tissue sarcoma patients. J Clin Oncol 2009;27:24-30. Available at: http://www.ncbi.nlm.nih.gov/pubmed/19047283.

296. Ballo MT, Zagars GK, Pollock RE, et al. Retroperitoneal soft tissue sarcoma: an analysis of radiation and surgical treatment. Int J Radiat

Version 3.2026 © 2026 National Comprehensive Cancer Network® (NCCN©), All rights reserved. NCCN Guidelines® and this illustration may not be reproduced in any form without the express written permission of NCCN.

PLEASE NOTE that use of this NCCN Content is governed by the End-User License Agreement, and you MAY NOT distribute this Content or use it with any artificial intelligence model or tool.
Printed by Ling Lu on 6/26/2026 6:10:47 AM. Copyright © 2026 National Comprehensive Cancer Network, Inc. All Rights Reserved.

Oncol Biol Phys 2007;67:158-163. Available at: http://www.ncbi.nlm.nih.gov/pubmed/17084545.

297. Gronchi A, Casali PG, Fiore M, et al. Retroperitoneal soft tissue sarcomas: patterns of recurrence in 167 patients treated at a single institution. Cancer 2004;100:2448-2455. Available at: http://www.ncbi.nlm.nih.gov/pubmed/15160351.

298. Stoeckle E, Coindre JM, Bonvalot S, et al. Prognostic factors in retroperitoneal sarcoma: a multivariate analysis of a series of 165 patients of the French Cancer Center Federation Sarcoma Group. Cancer 2001;92:359-368. Available at: http://www.ncbi.nlm.nih.gov/pubmed/11466691.

299. Raut CP, Pisters PWT. Retroperitoneal sarcomas: combined-modality treatment approaches. J Surg Oncol 2006;94:81-87. Available at: http://www.ncbi.nlm.nih.gov/pubmed/16788949.

300. Miura JT, Charlson J, Gamblin TC, et al. Impact of chemotherapy on survival in surgically resected retroperitoneal sarcoma. Eur J Surg Oncol 2015;41:1386-1392. Available at: https://www.ncbi.nlm.nih.gov/pubmed/26251340.

301. Thomas DM, O'Sullivan B, Gronchi A. Current concepts and future perspectives in retroperitoneal soft-tissue sarcoma management. Expert Rev Anticancer Ther 2009;9:1145-1157. Available at: http://www.ncbi.nlm.nih.gov/pubmed/19671034.

302. Mendenhall WM, Zlotecki RA, Hochwald SN, et al. Retroperitoneal soft tissue sarcoma. Cancer 2005;104:669-675. Available at: http://www.ncbi.nlm.nih.gov/pubmed/16003776.

303. Windham TC, Pisters PWT. Retroperitoneal sarcomas. Cancer Control 2005;12:36-43. Available at: http://www.ncbi.nlm.nih.gov/pubmed/15668651.

304. Singer S, Corson JM, Demetri GD, et al. Prognostic factors predictive of survival for truncal and retroperitoneal soft-tissue sarcoma. Ann Surg 1995;221:185-195. Available at: http://www.ncbi.nlm.nih.gov/pubmed/7857146.

305. Mullinax JE, Zager JS, Gonzalez RJ. Current diagnosis and management of retroperitoneal sarcoma. Cancer Control 2011;18:177-187. Available at: http://www.ncbi.nlm.nih.gov/pubmed/21666580.

306. Yoon SS, Chen Y-L, Kambadakone A, et al. Surgical placement of biologic mesh spacers prior to external beam radiation for retroperitoneal and pelvic tumors. Pract Radiat Oncol 2013;3:199-208. Available at: http://linkinghub.elsevier.com/retrieve/pii/S187985001200118X?showall=true.

307. Friedl W, Caspari R, Sengteller M, et al. Can APC mutation analysis contribute to therapeutic decisions in familial adenomatous polyposis? Experience from 680 FAP families. Gut 2001;48:515-521. Available at: http://www.ncbi.nlm.nih.gov/pubmed/11247896.

308. Durno C, Monga N, Bapat B, et al. Does early colectomy increase desmoid risk in familial adenomatous polyposis? Clin Gastroenterol Hepatol 2007;5:1190-1194. Available at: http://www.ncbi.nlm.nih.gov/pubmed/17916546.

309. Nugent KP, Spigelman AD, Phillips RK. Life expectancy after colectomy and ileorectal anastomosis for familial adenomatous polyposis. Dis Colon Rectum 1993;36:1059-1062. Available at: http://www.ncbi.nlm.nih.gov/pubmed/8223060.

310. Lazar AJ, Tuvin D, Hajibashi S, et al. Specific mutations in the beta-catenin gene (CTNNB1) correlate with local recurrence in sporadic desmoid tumors. Am J Pathol 2008;173:1518-1527. Available at: http://www.ncbi.nlm.nih.gov/pubmed/18832571.

311. Domont J, Salas S, Lacroix L, et al. High frequency of beta-catenin heterozygous mutations in extra-abdominal fibromatosis: a potential molecular tool for disease management. Br J Cancer 2010;102:1032-1036. Available at: http://www.ncbi.nlm.nih.gov/pubmed/20197769.

312. Le Guellec S, Soubeyran I, Rochaix P, et al. CTNNB1 mutation analysis is a useful tool for the diagnosis of desmoid tumors: a study of 260 desmoid tumors and 191 potential morphologic mimics. Mod Pathol 2012;25:1551-1558. Available at: http://www.ncbi.nlm.nih.gov/pubmed/22766794.

Discussion update in progress

Version 3.2026 © 2026 National Comprehensive Cancer Network® (NCCN©), All rights reserved. NCCN Guidelines® and this illustration may not be reproduced in any form without the express written permission of NCCN.

PLEASE NOTE that use of this NCCN Content is governed by the End-User License Agreement, and you MAY NOT distribute this Content or use it with any artificial intelligence model or tool.
Printed by Ling Lu on 6/26/2026 6:10:47 AM. Copyright © 2026 National Comprehensive Cancer Network, Inc. All Rights Reserved.

313. Colombo C, Miceli R, Lazar AJ, et al. CTNNB1 45F mutation is a molecular prognosticator of increased postoperative primary desmoid tumor recurrence: An independent, multicenter validation study. Cancer 2013;119:3696-3702. Available at: http://www.ncbi.nlm.nih.gov/pubmed/23913621.

314. Mullen JT, DeLaney TF, Rosenberg AE, et al. beta-Catenin mutation status and outcomes in sporadic desmoid tumors. Oncologist 2013;18:1043-1049. Available at: http://www.ncbi.nlm.nih.gov/pubmed/23960186.

315. Godwin Y, McCulloch TA, Sully L. Extra-abdominal desmoid tumour of the breast: review of the primary management and the implications for breast reconstruction. Br J Plast Surg 2001;54:268-271. Available at: http://www.ncbi.nlm.nih.gov/pubmed/11254428.

316. Yamaguchi H, Sakakibara T, Hino M, et al. A case of fibromatosis of the breast. Breast Cancer 2002;9:175-178. Available at: http://www.ncbi.nlm.nih.gov/pubmed/12016399.

317. Kouriefs C, Leris ACA, Mokbel K, et al. Infiltrating fibromatosis of the breast: a potential pitfall. Int J Clin Pract 2002;56:401-402. Available at: http://www.ncbi.nlm.nih.gov/pubmed/12137452.

318. Neuman HB, Brogi E, Ebrahim A, et al. Desmoid tumors (fibromatoses) of the breast: a 25-year experience. Ann Surg Oncol 2008;15:274-280. Available at: http://www.ncbi.nlm.nih.gov/pubmed/17896146.

319. Lev D, Kotilingam D, Wei C, et al. Optimizing treatment of desmoid tumors. J Clin Oncol 2007;25:1785-1791. Available at: http://www.ncbi.nlm.nih.gov/pubmed/17470870.

320. Pritchard DJ, Nascimento AG, Petersen IA. Local control of extra-abdominal desmoid tumors. J Bone Joint Surg Am 1996;78:848-854. Available at: http://www.ncbi.nlm.nih.gov/pubmed/8666602.

321. Ballo MT, Zagars GK, Pollack A, et al. Desmoid tumor: prognostic factors and outcome after surgery, radiation therapy, or combined surgery and radiation therapy. J Clin Oncol 1999;17:158-167. Available at: http://www.ncbi.nlm.nih.gov/pubmed/10458229.

322. Stojadinovic A, Hoos A, Karpoff HM, et al. Soft tissue tumors of the abdominal wall: analysis of disease patterns and treatment. Arch Surg 2001;136:70-79. Available at: http://www.ncbi.nlm.nih.gov/pubmed/11146782.

323. Ma D, Li S, Fu R, et al. Long-term outcomes of 47 patients with aggressive fibromatosis of the chest treated with surgery. Eur J Surg Oncol 2016;42:1693-1698. Available at: https://www.ncbi.nlm.nih.gov/pubmed/27425579.

324. Gronchi A, Casali PG, Mariani L, et al. Quality of surgery and outcome in extra-abdominal aggressive fibromatosis: a series of patients surgically treated at a single institution. J Clin Oncol 2003;21:1390-1397. Available at: http://www.ncbi.nlm.nih.gov/pubmed/12663732.

325. Peng PD, Hyder O, Mavros MN, et al. Management and recurrence patterns of desmoids tumors: a multi-institutional analysis of 211 patients. Ann Surg Oncol 2012;19:4036-4042. Available at: http://www.ncbi.nlm.nih.gov/pubmed/22972507.

326. Melis M, Zager JS, Sondak VK. Multimodality management of desmoid tumors: how important is a negative surgical margin? J Surg Oncol 2008;98:594-602. Available at: http://www.ncbi.nlm.nih.gov/pubmed/19072851.

327. Huang K, Fu H, Shi YQ, et al. Prognostic factors for extra-abdominal and abdominal wall desmoids: a 20-year experience at a single institution. J Surg Oncol 2009;100:563-569. Available at: http://www.ncbi.nlm.nih.gov/pubmed/19722232.

328. Stoeckle E, Coindre JM, Longy M, et al. A critical analysis of treatment strategies in desmoid tumours: a review of a series of 106 cases. Eur J Surg Oncol 2009;35:129-134. Available at: http://www.ncbi.nlm.nih.gov/pubmed/18760561.

329. Mullen JT, Delaney TF, Kobayashi WK, et al. Desmoid tumor: analysis of prognostic factors and outcomes in a surgical series. Ann Surg Oncol 2012;19:4028-4035. Available at: http://www.ncbi.nlm.nih.gov/pubmed/22965569.

330. Janssen ML, van Broekhoven DL, Cates JM, et al. Meta-analysis of the influence of surgical margin and adjuvant radiotherapy on local

Discussion update in progress

Version 3.2026 © 2026 National Comprehensive Cancer Network® (NCCN©), All rights reserved. NCCN Guidelines® and this illustration may not be reproduced in any form without the express written permission of NCCN.

PLEASE NOTE that use of this NCCN Content is governed by the End-User License Agreement, and you MAY NOT distribute this Content or use it with any artificial intelligence model or tool.
Printed by Ling Lu on 6/26/2026 6:10:47 AM. Copyright © 2026 National Comprehensive Cancer Network, Inc. All Rights Reserved.

recurrence after resection of sporadic desmoid-type fibromatosis. Br J Surg 2017;104:347-357. Available at: https://www.ncbi.nlm.nih.gov/pubmed/28199014.

331. Gluck I, Griffith KA, Biermann JS, et al. Role of radiotherapy in the management of desmoid tumors. Int J Radiat Oncol Biol Phys 2011;80:787-792. Available at: http://www.ncbi.nlm.nih.gov/pubmed/20615622.

332. Crago AM, Denton B, Salas S, et al. A prognostic nomogram for prediction of recurrence in desmoid fibromatosis. Ann Surg 2013;258:347-353. Available at: http://www.ncbi.nlm.nih.gov/pubmed/23532110.

333. Salas S, Dufresne A, Bui B, et al. Prognostic factors influencing progression-free survival determined from a series of sporadic desmoid tumors: a wait-and-see policy according to tumor presentation. J Clin Oncol 2011;29:3553-3558. Available at: http://www.ncbi.nlm.nih.gov/pubmed/21844500.

334. Cates JM, Stricker TP. Surgical resection margins in desmoid-type fibromatosis: a critical reassessment. Am J Surg Pathol 2014;38:1707-1714. Available at: http://www.ncbi.nlm.nih.gov/pubmed/25392923.

335. Goy BW, Lee SP, Eilber F, et al. The role of adjuvant radiotherapy in the treatment of resectable desmoid tumors. Int J Radiat Oncol Biol Phys 1997;39:659-665. Available at: http://www.ncbi.nlm.nih.gov/pubmed/9336146.

336. Jelinek JA, Stelzer KJ, Conrad E, et al. The efficacy of radiotherapy as postoperative treatment for desmoid tumors. Int J Radiat Oncol Biol Phys 2001;50:121-125. Available at: http://www.ncbi.nlm.nih.gov/pubmed/11316554.

337. Fontanesi J, Mott MP, Kraut MJ, et al. The role of postoperative irradiation in the treatment of locally recurrent incompletely resected extra-abdominal desmoid tumors. Sarcoma 2004;8:83-86. Available at: http://www.ncbi.nlm.nih.gov/pubmed/18521399.

338. Baumert BG, Spahr MO, Von Hochstetter A, et al. The impact of radiotherapy in the treatment of desmoid tumours. An international survey of 110 patients. A study of the Rare Cancer Network. Radiat Oncol 2007;2:12-12. Available at: http://www.ncbi.nlm.nih.gov/pubmed/17343751.

339. Guadagnolo BA, Zagars GK, Ballo MT. Long-term outcomes for desmoid tumors treated with radiation therapy. Int J Radiat Oncol Biol Phys 2008;71:441-447. Available at: http://www.ncbi.nlm.nih.gov/pubmed/18068311.

340. Santti K, Beule A, Tuomikoski L, et al. Radiotherapy in desmoid tumors : Treatment response, local control, and analysis of local failures. Strahlenther Onkol 2017. Available at: https://www.ncbi.nlm.nih.gov/pubmed/28044201.

341. Bonvalot S, Eldweny H, Haddad V, et al. Extra-abdominal primary fibromatosis: Aggressive management could be avoided in a subgroup of patients. Eur J Surg Oncol 2008;34:462-468. Available at: http://www.ncbi.nlm.nih.gov/pubmed/17709227.

342. Fiore M, Rimareix F, Mariani L, et al. Desmoid-type fibromatosis: a front-line conservative approach to select patients for surgical treatment. Ann Surg Oncol 2009;16:2587-2593. Available at: http://www.ncbi.nlm.nih.gov/pubmed/19568815.

343. Lewis JJ, Boland PJ, Leung DH, et al. The enigma of desmoid tumors. Ann Surg 1999;229:866-872. Available at: http://www.ncbi.nlm.nih.gov/pubmed/10363901.

344. Kiel KD, Suit HD. Radiation therapy in the treatment of aggressive fibromatoses (desmoid tumors). Cancer 1984;54:2051-2055. Available at: http://www.ncbi.nlm.nih.gov/pubmed/6488135.

345. Ballo MT, Zagars GK, Pollack A. Radiation therapy in the management of desmoid tumors. Int J Radiat Oncol Biol Phys 1998;42:1007-1014. Available at: http://www.ncbi.nlm.nih.gov/pubmed/9869223.

346. Schulz-Ertner D, Zierhut D, Mende U, et al. The role of radiation therapy in the management of desmoid tumors. Strahlenther Onkol 2002;178:78-83. Available at: http://www.ncbi.nlm.nih.gov/pubmed/11942041.

347. Keus RB, Nout RA, Blay JY, et al. Results of a phase II pilot study of moderate dose radiotherapy for inoperable desmoid-type fibromatosis-

Version 3.2026 © 2026 National Comprehensive Cancer Network® (NCCN©), All rights reserved. NCCN Guidelines® and this illustration may not be reproduced in any form without the express written permission of NCCN.

PLEASE NOTE that use of this NCCN Content is governed by the End-User License Agreement, and you MAY NOT distribute this Content or use it with any artificial intelligence model or tool.
Printed by Ling Lu on 6/26/2026 6:10:47 AM. Copyright © 2026 National Comprehensive Cancer Network, Inc. All Rights Reserved.

-an EORTC STBSG and ROG study (EORTC 62991-22998). Ann Oncol 2013;24:2672-2676. Available at: http://www.ncbi.nlm.nih.gov/pubmed/23868907.

348. Janinis J, Patriki M, Vini L, et al. The pharmacological treatment of aggressive fibromatosis: a systematic review. Ann Oncol 2003;14:181-190. Available at: http://www.ncbi.nlm.nih.gov/pubmed/12562642.

349. de Camargo VP, Keohan ML, D'Adamo DR, et al. Clinical outcomes of systemic therapy for patients with deep fibromatosis (desmoid tumor). Cancer 2010;116:2258-2265. Available at: http://www.ncbi.nlm.nih.gov/pubmed/20187095.

350. Hansmann A, Adolph C, Vogel T, et al. High-dose tamoxifen and sulindac as first-line treatment for desmoid tumors. Cancer 2004;100:612-620. Available at: http://www.ncbi.nlm.nih.gov/pubmed/14745880.

351. Leithner A, Schnack B, Katterschafka T, et al. Treatment of extra-abdominal desmoid tumors with interferon-alpha with or without tretinoin. J Surg Oncol 2000;73:21-25. Available at: http://www.ncbi.nlm.nih.gov/pubmed/10649274.

352. Benson JR, Mokbel K, Baum M. Management of desmoid tumours including a case report of toremifene. Ann Oncol 1994;5:173-177. Available at: http://www.ncbi.nlm.nih.gov/pubmed/8186162.

353. Bus PJ, Verspaget HW, van Krieken JH, et al. Treatment of mesenteric desmoid tumours with the anti-oestrogenic agent toremifene: case histories and an overview of the literature. Eur J Gastroenterol Hepatol 1999;11:1179-1183. Available at: http://www.ncbi.nlm.nih.gov/pubmed/10524651.

354. Heidemann J, Ogawa H, Otterson MF, et al. Antiangiogenic treatment of mesenteric desmoid tumors with toremifene and interferon alfa-2b: report of two cases. Dis Colon Rectum 2004;47:118-122. Available at: http://www.ncbi.nlm.nih.gov/pubmed/14719159.

355. Maseelall P, Robins JC, Williams DB, Thomas MA. Stabilization and regression of a recurrent desmoid tumor with the antiestrogen toremifene. Fertil Steril 2005;84:509. Available at: http://www.ncbi.nlm.nih.gov/pubmed/16086575.

356. Patel SR, Evans HL, Benjamin RS. Combination chemotherapy in adult desmoid tumors. Cancer 1993;72:3244-3247. Available at: http://www.ncbi.nlm.nih.gov/pubmed/8242548.

357. Poritz LS, Blackstein M, Berk T, et al. Extended follow-up of patients treated with cytotoxic chemotherapy for intra-abdominal desmoid tumors. Dis Colon Rectum 2001;44:1268-1273. Available at: http://www.ncbi.nlm.nih.gov/pubmed/11584198.

358. Garbay D, Le Cesne A, Penel N, et al. Chemotherapy in patients with desmoid tumors: a study from the French Sarcoma Group (FSG). Ann Oncol 2012;23:182-186. Available at: http://www.ncbi.nlm.nih.gov/pubmed/21444357.

359. Constantinidou A, Jones RL, Scurr M, et al. Pegylated liposomal doxorubicin, an effective, well-tolerated treatment for refractory aggressive fibromatosis. Eur J Cancer 2009;45:2930-2934. Available at: http://www.ncbi.nlm.nih.gov/pubmed/19767198.

360. Weiss AJ, Horowitz S, Lackman RD. Therapy of desmoid tumors and fibromatosis using vinorelbine. Am J Clin Oncol 1999;22:193-195. Available at: http://www.ncbi.nlm.nih.gov/pubmed/10199460.

361. Azzarelli A, Gronchi A, Bertulli R, et al. Low-dose chemotherapy with methotrexate and vinblastine for patients with advanced aggressive fibromatosis. Cancer 2001;92:1259-1264. Available at: http://www.ncbi.nlm.nih.gov/pubmed/11571741.

362. Park KH, Choi YJ, Kim KW, et al. Combination chemotherapy with methotrexate and vinblastine for surgically unresectable, aggressive fibromatosis. Jpn J Clin Oncol 2016;46:845-849. Available at: https://www.ncbi.nlm.nih.gov/pubmed/27365524.

363. Heinrich MC, McArthur GA, Demetri GD, et al. Clinical and molecular studies of the effect of imatinib on advanced aggressive fibromatosis (desmoid tumor). J Clin Oncol 2006;24:1195-1203. Available at: http://www.ncbi.nlm.nih.gov/pubmed/16505440.

364. Chugh R, Wathen JK, Patel SR, et al. Efficacy of imatinib in aggressive fibromatosis: Results of a phase II multicenter Sarcoma Alliance for Research through Collaboration (SARC) trial. Clin Cancer

Discussion update in progress

Version 3.2026 © 2026 National Comprehensive Cancer Network® (NCCN©), All rights reserved. NCCN Guidelines® and this illustration may not be reproduced in any form without the express written permission of NCCN.

PLEASE NOTE that use of this NCCN Content is governed by the End-User License Agreement, and you MAY NOT distribute this Content or use it with any artificial intelligence model or tool.
Printed by Ling Lu on 6/26/2026 6:10:47 AM. Copyright © 2026 National Comprehensive Cancer Network, Inc. All Rights Reserved.

Res 2010;16:4884-4891. Available at: http://www.ncbi.nlm.nih.gov/pubmed/20724445.

365. Penel N, Le Cesne A, Bui BN, et al. Imatinib for progressive and recurrent aggressive fibromatosis (desmoid tumors): an FNCLCC/French Sarcoma Group phase II trial with a long-term follow-up. Ann Oncol 2011;22:452-457. Available at: http://www.ncbi.nlm.nih.gov/pubmed/20622000.

366. Ferrari A, Dileo P, Casanova M, et al. Rhabdomyosarcoma in adults. A retrospective analysis of 171 patients treated at a single institution. Cancer 2003;98:571-580. Available at: http://www.ncbi.nlm.nih.gov/pubmed/12879475.

367. Newton WA, Jr., Gehan EA, Webber BL, et al. Classification of rhabdomyosarcomas and related sarcomas. Pathologic aspects and proposal for a new classification--an Intergroup Rhabdomyosarcoma Study. Cancer 1995;76:1073-1085. Available at: http://www.ncbi.nlm.nih.gov/pubmed/8625211.

368. Parham DM, Ellison DA. Rhabdomyosarcomas in adults and children: an update. Arch Pathol Lab Med 2006;130:1454-1465. Available at: http://www.ncbi.nlm.nih.gov/pubmed/17090187.

369. Hawkins WG, Hoos A, Antonescu CR, et al. Clinicopathologic analysis of patients with adult rhabdomyosarcoma. Cancer 2001;91:794-803. Available at: http://www.ncbi.nlm.nih.gov/pubmed/11241248.

370. Little DJ, Ballo MT, Zagars GK, et al. Adult rhabdomyosarcoma: outcome following multimodality treatment. Cancer 2002;95:377-388. Available at: http://www.ncbi.nlm.nih.gov/pubmed/12124838.

371. Nascimento AF, Fletcher CDM. Spindle cell rhabdomyosarcoma in adults. Am J Surg Pathol 2005;29:1106-1113. Available at: http://www.ncbi.nlm.nih.gov/pubmed/16006807.

372. Sultan I, Qaddoumi I, Yaser S, et al. Comparing adult and pediatric rhabdomyosarcoma in the surveillance, epidemiology and end results program, 1973 to 2005: an analysis of 2,600 patients. J Clin Oncol 2009;27:3391-3397. Available at: http://www.ncbi.nlm.nih.gov/pubmed/19398574.

373. Yasuda T, Perry KD, Nelson M, et al. Alveolar rhabdomyosarcoma of the head and neck region in older adults: genetic characterization and a review of the literature. Hum Pathol 2009;40:341-348. Available at: http://www.ncbi.nlm.nih.gov/pubmed/18973919.

374. Simon JH, Paulino AC, Ritchie JM, et al. Presentation, prognostic factors and patterns of failure in adult rhabdomyosarcoma. Sarcoma 2003;7:1-7. Available at: http://www.ncbi.nlm.nih.gov/pubmed/18521362.

375. Gaffney EF, Dervan PA, Fletcher CD. Pleomorphic rhabdomyosarcoma in adulthood. Analysis of 11 cases with definition of diagnostic criteria. Am J Surg Pathol 1993;17:601-609. Available at: http://www.ncbi.nlm.nih.gov/pubmed/8333559.

376. Furlong MA, Mentzel T, Fanburg-Smith JC. Pleomorphic rhabdomyosarcoma in adults: a clinicopathologic study of 38 cases with emphasis on morphologic variants and recent skeletal muscle-specific markers. Mod Pathol 2001;14:595-603. Available at: http://www.ncbi.nlm.nih.gov/pubmed/11406662.

377. Stock N, Chibon F, Binh MBN, et al. Adult-type rhabdomyosarcoma: analysis of 57 cases with clinicopathologic description, identification of 3 morphologic patterns and prognosis. Am J Surg Pathol 2009;33:1850-1859. Available at: http://www.ncbi.nlm.nih.gov/pubmed/19898221.

378. Esnaola NF, Rubin BP, Baldini EH, et al. Response to chemotherapy and predictors of survival in adult rhabdomyosarcoma. Ann Surg 2001;234:215-223. Available at: http://www.ncbi.nlm.nih.gov/pubmed/11505068.

379. Sultan I, Ferrari A. Selecting multimodal therapy for rhabdomyosarcoma. Expert Rev Anticancer Ther 2010;10:1285-1301. Available at: http://www.ncbi.nlm.nih.gov/pubmed/20735314.

380. Arndt CAS, Stoner JA, Hawkins DS, et al. Vincristine, actinomycin, and cyclophosphamide compared with vincristine, actinomycin, and cyclophosphamide alternating with vincristine, topotecan, and cyclophosphamide for intermediate-risk rhabdomyosarcoma: children's oncology group study D9803. J Clin Oncol 2009;27:5182-5188. Available at: http://www.ncbi.nlm.nih.gov/pubmed/19770373.

Discussion Update in Progress

Version 3.2026 © 2026 National Comprehensive Cancer Network® (NCCN©), All rights reserved. NCCN Guidelines® and this illustration may not be reproduced in any form without the express written permission of NCCN.

PLEASE NOTE that use of this NCCN Content is governed by the End-User License Agreement, and you MAY NOT distribute this Content or use it with any artificial intelligence model or tool.
Printed by Ling Lu on 6/26/2026 6:10:47 AM. Copyright © 2026 National Comprehensive Cancer Network, Inc. All Rights Reserved.

381. Wolden SL, Lyden ER, Arndt CA, et al. Local Control for Intermediate-Risk Rhabdomyosarcoma: Results From D9803 According to Histology, Group, Site, and Size: A Report From the Children's Oncology Group. Int J Radiat Oncol Biol Phys 2015;93:1071-1076. Available at: https://www.ncbi.nlm.nih.gov/pubmed/26581144.

382. Raney RB, Walterhouse DO, Meza JL, et al. Results of the Intergroup Rhabdomyosarcoma Study Group D9602 protocol, using vincristine and dactinomycin with or without cyclophosphamide and radiation therapy, for newly diagnosed patients with low-risk embryonal rhabdomyosarcoma: a report from the Soft Tissue Sarcoma Committee of the Children's Oncology Group. J Clin Oncol 2011;29:1312-1318. Available at: http://www.ncbi.nlm.nih.gov/pubmed/21357783.

383. Arndt CAS, Hawkins DS, Meyer WH, et al. Comparison of results of a pilot study of alternating vincristine/doxorubicin/cyclophosphamide and etoposide/ifosfamide with IRS-IV in intermediate risk rhabdomyosarcoma: a report from the Children's Oncology Group. Pediatr Blood Cancer 2008;50:33-36. Available at: http://www.ncbi.nlm.nih.gov/pubmed/17091486.

384. Weigel BJ, Lyden E, Anderson JR, et al. Intensive Multiagent Therapy, Including Dose-Compressed Cycles of Ifosfamide/Etoposide and Vincristine/Doxorubicin/Cyclophosphamide, Irinotecan, and Radiation, in Patients With High-Risk Rhabdomyosarcoma: A Report From the Children's Oncology Group. J Clin Oncol 2016;34:117-122. Available at: https://www.ncbi.nlm.nih.gov/pubmed/26503200.

385. Klingebiel T, Pertl U, Hess CF, et al. Treatment of children with relapsed soft tissue sarcoma: report of the German CESS/CWS REZ 91 trial. Med Pediatr Oncol 1998;30:269-275. Available at: http://www.ncbi.nlm.nih.gov/pubmed/9544222.

386. Pappo AS, Lyden E, Breitfeld P, et al. Two consecutive phase II window trials of irinotecan alone or in combination with vincristine for the treatment of metastatic rhabdomyosarcoma: the Children's Oncology Group. J Clin Oncol 2007;25:362-369. Available at: http://www.ncbi.nlm.nih.gov/pubmed/17264331.

387. Vassal G, Couanet D, Stockdale E, et al. Phase II trial of irinotecan in children with relapsed or refractory rhabdomyosarcoma: a joint study of the French Society of Pediatric Oncology and the United Kingdom Children's Cancer Study Group. J Clin Oncol 2007;25:356-361. Available at: http://www.ncbi.nlm.nih.gov/pubmed/17264330.

388. Mascarenhas L, Lyden ER, Breitfeld PP, et al. Randomized phase II window trial of two schedules of irinotecan with vincristine in patients with first relapse or progression of rhabdomyosarcoma: a report from the Children's Oncology Group. J Clin Oncol 2010;28:4658-4663. Erratum in J Clin Oncol. 2011;4629(4610):1394. Available at: http://www.ncbi.nlm.nih.gov/pubmed/20837952.

389. McNall-Knapp RY, Williams CN, Reeves EN, et al. Extended phase I evaluation of vincristine, irinotecan, temozolomide, and antibiotic in children with refractory solid tumors. Pediatr Blood Cancer 2010;54:909-915. Available at: http://www.ncbi.nlm.nih.gov/pubmed/20405511.

390. Pappo AS, Lyden E, Breneman J, et al. Up-front window trial of topotecan in previously untreated children and adolescents with metastatic rhabdomyosarcoma: an intergroup rhabdomyosarcoma study. J Clin Oncol 2001;19:213-219. Available at: http://www.ncbi.nlm.nih.gov/pubmed/11134215.

391. Saylors RL, Stine KC, Sullivan J, et al. Cyclophosphamide plus topotecan in children with recurrent or refractory solid tumors: a Pediatric Oncology Group phase II study. J Clin Oncol 2001;19:3463-3469. Available at: http://www.ncbi.nlm.nih.gov/pubmed/11481351.

392. Walterhouse DO, Lyden ER, Breitfeld PP, et al. Efficacy of topotecan and cyclophosphamide given in a phase II window trial in children with newly diagnosed metastatic rhabdomyosarcoma: a Children's Oncology Group study. J Clin Oncol 2004;22:1398-1403. Available at: http://www.ncbi.nlm.nih.gov/pubmed/15007087.

393. Casanova M, Ferrari A, Bisogno G, et al. Vinorelbine and low-dose cyclophosphamide in the treatment of pediatric sarcomas: pilot study for the upcoming European Rhabdomyosarcoma Protocol. Cancer 2004;101:1664-1671. Available at: http://www.ncbi.nlm.nih.gov/pubmed/15378498.

394. Casanova M, Ferrari A, Spreafico F, et al. Vinorelbine in previously treated advanced childhood sarcomas: evidence of activity in

Discussion update in progress

Version 3.2026 © 2026 National Comprehensive Cancer Network® (NCCN©), All rights reserved. NCCN Guidelines® and this illustration may not be reproduced in any form without the express written permission of NCCN.

PLEASE NOTE that use of this NCCN Content is governed by the End-User License Agreement, and you MAY NOT distribute this Content or use it with any artificial intelligence model or tool.
Printed by Ling Lu on 6/26/2026 6:10:47 AM. Copyright © 2026 National Comprehensive Cancer Network, Inc. All Rights Reserved.

rhabdomyosarcoma. Cancer 2002;94:3263-3268. Available at: http://www.ncbi.nlm.nih.gov/pubmed/12115359.

395. Dharmarajan KV, Wexler LH, Wolden SL. Concurrent radiation with irinotecan and carboplatin in intermediate- and high-risk rhabdomyosarcoma: a report on toxicity and efficacy from a prospective pilot phase II study. Pediatr Blood Cancer 2013;60:242-247. Available at: http://www.ncbi.nlm.nih.gov/pubmed/22619050.

396. Ogilvie CM, Crawford EA, Slotcavage RL, et al. Treatment of adult rhabdomyosarcoma. Am J Clin Oncol 2010;33:128-131. Available at: http://www.ncbi.nlm.nih.gov/pubmed/19770626.

397. Setty BA, Stanek JR, Mascarenhas L, et al. VIncristine, irinotecan, and temozolomide in children and adolescents with relapsed rhabdomyosarcoma. Pediatr Blood Cancer 2018;65. Available at: https://www.ncbi.nlm.nih.gov/pubmed/28748602.

398. Tateishi U, Hosono A, Makimoto A, et al. Comparative study of FDG PET/CT and conventional imaging in the staging of rhabdomyosarcoma. Ann Nucl Med 2009;23:155-161. Available at: http://www.ncbi.nlm.nih.gov/pubmed/19225939.

Discussion update in progress

Version 3.2026 © 2026 National Comprehensive Cancer Network® (NCCN©), All rights reserved. NCCN Guidelines® and this illustration may not be reproduced in any form without the express written permission of NCCN.